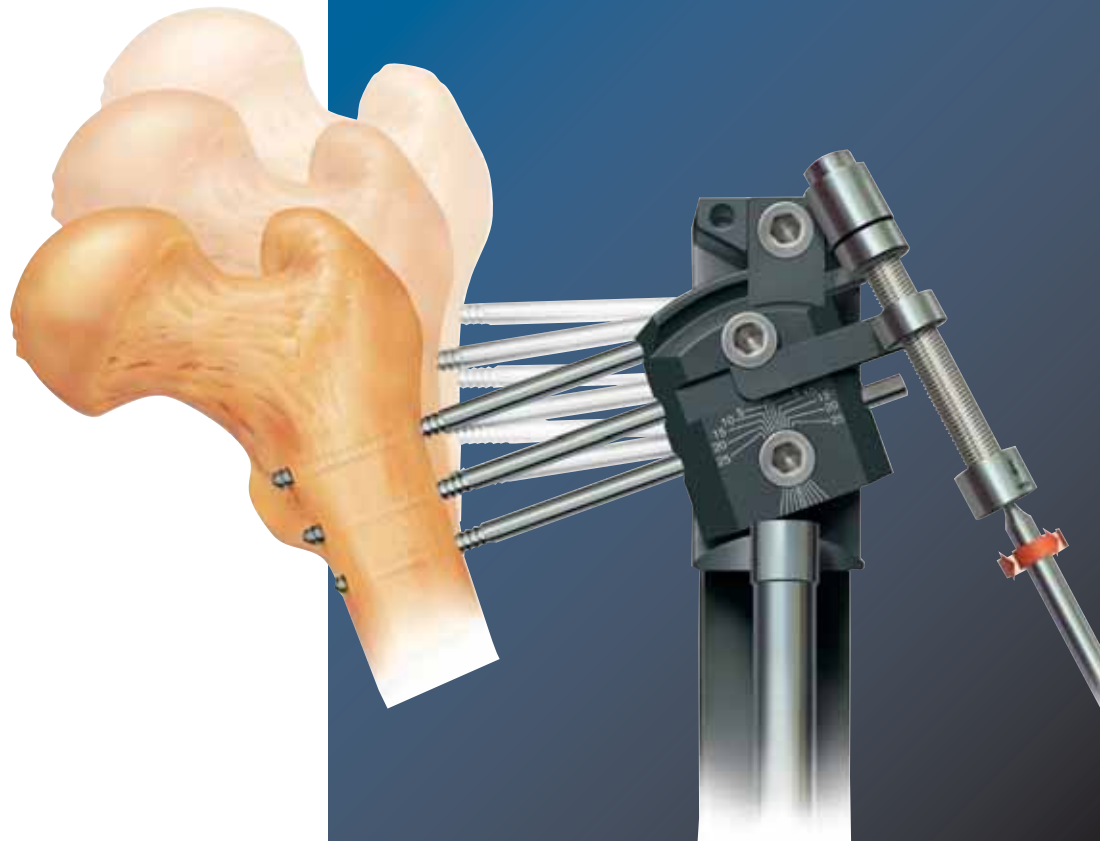

Limb Reconstruction System

Part B: Correction of Deformities

By Dr. S. Nayagam

LIMB RECONSTRUCTION SYSTEM**Part B: Correction of Deformities**

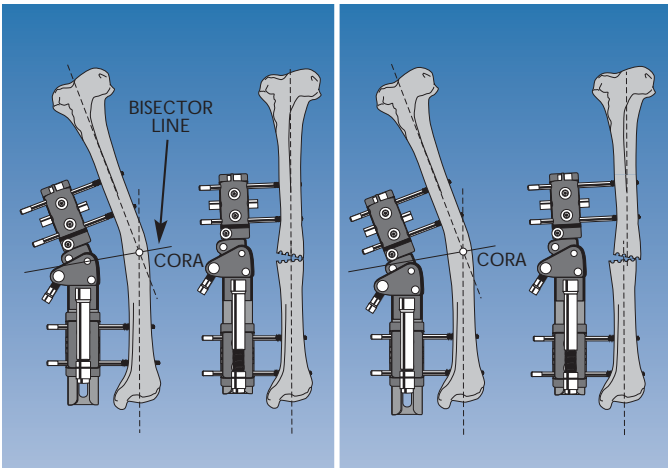
| | Page N° |
|--|---------|
| QUICK REFERENCE GUIDE | I |
| BASIC CONSIDERATIONS | 1 |
| Anatomical Axis..... | 1 |
| Mechanical Axis..... | 1 |
| CORA..... | 2 |
| Bisector Line..... | 2 |
| Translation..... | 3 |
| Pre-Operative Planning..... | 3 |
| Acute or Gradual Correction of a Deformity?..... | 3 |
| Gradual Correction..... | 4 |
| Acute Correction..... | 4 |
| Calculation of the True Plane of the Deformity..... | 5 |
| GRADUAL CORRECTION OF A DEFORMITY WITH THE MICROMETRIC CLAMPS | 6 |
| THE PLANE OF DEFORMITY | 6 |
| POSITION OF THE CENTER OF ROTATION OF THE CLAMP | 7 |
| PROTOCOL FOR THE USE OF THE MICROMETRIC CORRECTION CLAMPS | 8 |
| Fixator on Convex Side of Deformity..... | 8 |
| Fixator on Concave Side of Deformity..... | 9 |
| General Points..... | 9 |
| Translation and the Micrometric Clamps..... | 10 |
| USE OF THE MICROMETRIC SWIVELLING CLAMP | 12 |
| 1. IMMEDIATE ON-TABLE CORRECTION..... | 12 |
| 2. LATE CORRECTION THROUGH CALLUS MANIPULATION..... | 13 |
| a) Planned Later Correction..... | 13 |
| b) Correction of an Unexpected Deformity during Lengthening..... | 13 |
| USE OF THE MULTIPLANAR CLAMP | 14 |
| Application Technique..... | 14 |
| SALVAGE PROCEDURE IN CASE OF INCORRECT PRE-OPERATIVE PLANNING | 16 |
| THE OF-GARCHES T-CLAMP IN THE PROXIMAL TIBIA | 17 |
| Principles of Use..... | 17 |
| CORRECTION OF VARUS OR VALGUS DEVIATION | 18 |
| Gradual Correction..... | 18 |
| Immediate Correction..... | 19 |
| Lengthening with Correction..... | 20 |
| THE ACUTE CORRECTION TEMPLATES | 21 |
| General Principles..... | 21 |
| Caution with Acute Correction..... | 21 |
| Angulation Templates..... | 22 |
| Rotational Templates..... | 22 |
| Choosing the Correct Arc Size..... | 23 |
| Rotational Template Assembly..... | 24 |
| Example Application Showing Use of Angular and Rotational Template..... | 24 |
| Post-Operative Management..... | 26 |
| PEDIATRIC USE OF THE LIMB RECONSTRUCTION SYSTEM | 27 |
| Screw Size..... | 27 |

LIMB RECONSTRUCTION SYSTEM

Part A: General Principles

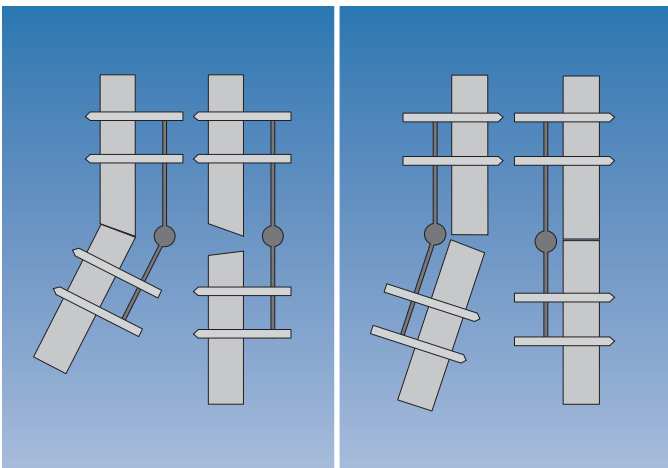
| | Page N° |
|--|---------|
| QUICK REFERENCE GUIDE | I |
| INTRODUCTION | 1 |
| EQUIPMENT REQUIRED | 7 |
| 1. LIMB RECONSTRUCTION SYSTEM | 7 |
| Adult Models..... | 7 |
| Pediatric Models..... | 10 |
| 2. INSTRUMENTATION | 12 |
| 3. SCREWS | 13 |
| 4. ACCESSORY MODULES | 14 |
| The T-Clamp..... | 14 |
| The Swivelling Clamp..... | 14 |
| The Ball-Joint Coupling..... | 15 |
| The Acute Correction Templates..... | 15 |
| The OF-Garches T-Clamp..... | 16 |
| The Multiplanar Clamp..... | 16 |
| The Sandwich Clamp..... | 17 |
| The Dyna-Ring..... | 17 |
| CLEANING AND STERILIZATION | 18 |
| A. BONE TRANSPORT | 19 |
| A) DISTAL BONE LOSS IN THE FEMUR | 19 |
| Pre-Operative Planning..... | 19 |
| Operative Technique..... | 19 |
| Post-Operative Management..... | 28 |
| Physiotherapy..... | 28 |
| Pin Site Care..... | 28 |
| Segmental Transport..... | 29 |
| The Docking Procedure..... | 29 |
| Dynamization of the Docking Site..... | 30 |
| Distal Clamp and Screw Removal..... | 30 |
| Management of the Newly-Formed Segment..... | 30 |
| Dynamization of the Newly-Formed Segment..... | 31 |
| Clamp and Screw Removal..... | 31 |
| B) PROXIMAL BONE LOSS IN THE FEMUR | 31 |
| Post-Operative Management..... | 31 |
| Segmental Transport..... | 31 |
| The Docking Procedure..... | 31 |
| Dynamization of the Docking Site..... | 31 |
| Proximal Clamp and Screw Removal..... | 31 |
| Management of the Newly-Formed Segment..... | 32 |
| Dynamization of the Newly-Formed Segment..... | 32 |
| Clamp and Screw Removal..... | 32 |
| C) DISTAL BONE LOSS IN THE TIBIA | 32 |
| Post-Operative Management..... | 33 |
| D) PROXIMAL BONE LOSS IN THE TIBIA | 33 |
| E) BIFOCAL TRANSPORT | 34 |
| B. COMPRESSION-DISTRACTION | 35 |
| A) SHORTENING WITH A SMALL DEFECT | 35 |
| B) SHORTENING WITH DIAPHYSEAL DEFORMITY | 36 |

| | |
|---|----|
| C. BIFOCAL LENGTHENING | 37 |
| A) EXTREME SHORTENING | 37 |
| B) SHORTENING ASSOCIATED WITH METAPHYSEAL DEFORMITY | 38 |
| D. THE MANAGEMENT OF FRACTURES ASSOCIATED WITH MAJOR SOFT TISSUE DEFECTS | 39 |
| E. MONOFOCAL PROCEDURES | 40 |
| A) MONOFOCAL LENGTHENING | 40 |
| B) SITUATIONS WHERE INCREASED STABILITY IS REQUIRED | 40 |
| C) DEFORMITY CORRECTION WITH OR WITHOUT LENGTHENING | 40 |
| F. NON-UNION | 41 |
| USING THE ACCESSORY MODULES | 42 |
| The T-Clamp | 42 |
| The OF-Garches T-Clamp | 42 |
| The Ball-Joint Coupling | 46 |
| PEDIATRIC USE OF THE LIMB RECONSTRUCTION SYSTEM | 46 |
| REFERENCES | 47 |

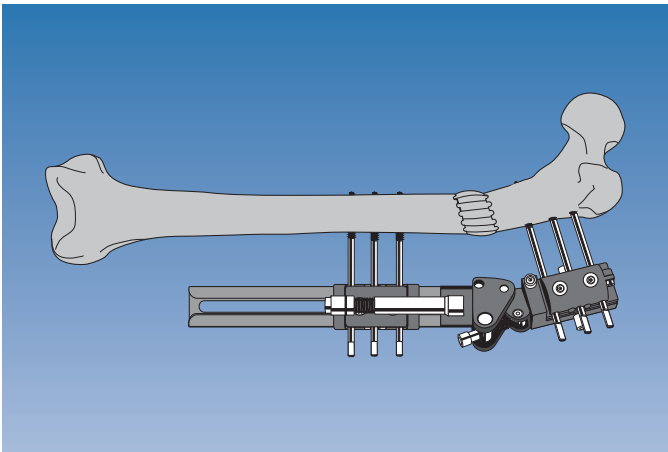


BASIC CONSIDERATIONS

When hinge of monolateral fixator is on bisector line, after correction there is no translation.
 When hinge is at level of deformity, after correction there is some residual translation.



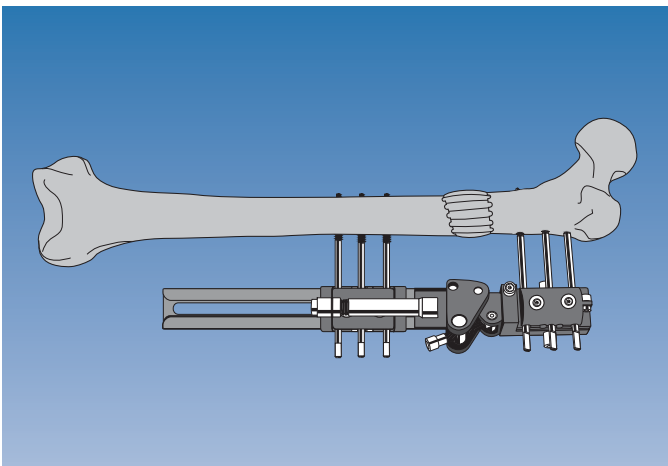
When monolateral fixator is on convex side of deformity, correction will *distract* osteotomy.
 When on concave side, *compression* will occur at osteotomy.



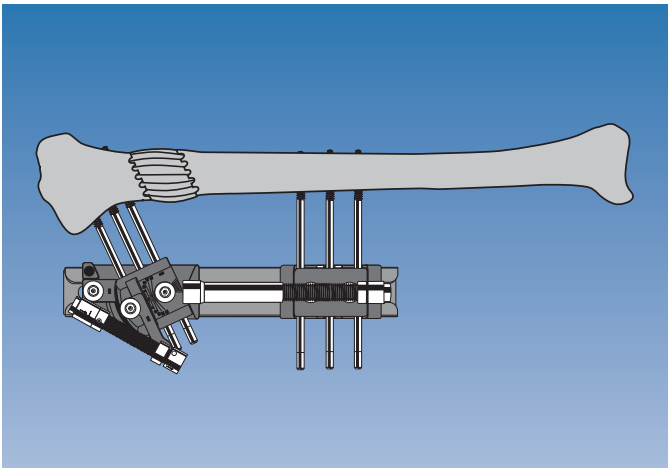
PROTOCOL FOR USE OF MICROMETRIC CORRECTION CLAMPS

Fixator on Convex Side of Deformity

- a) Distract osteotomy according to principles of Callotasis.
- b) Reduce soft tissue tension by shortening acutely by 4-5 mm.

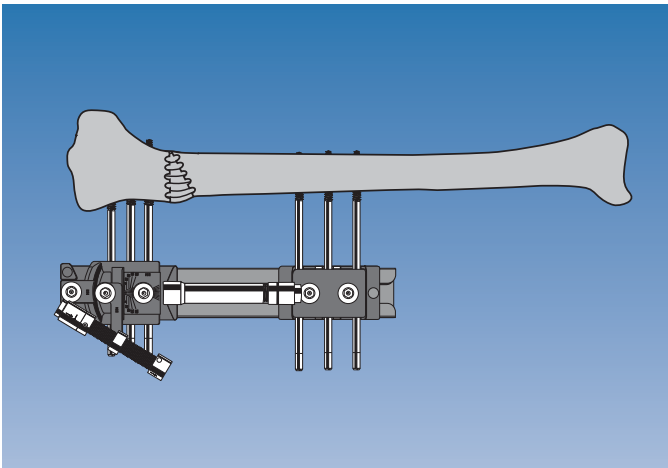


- c) Correction is performed until tension is felt.
- d) Repeat (b) and (c) until correction complete.

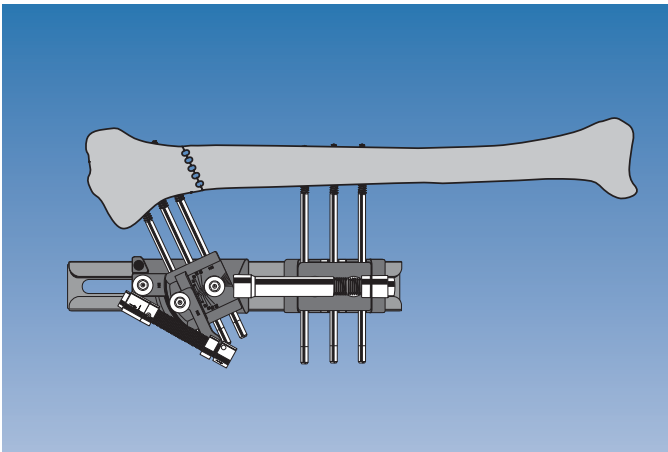


Fixator on Concave Side of Deformity

a) Distract osteotomy according to principles of Callotaxis.

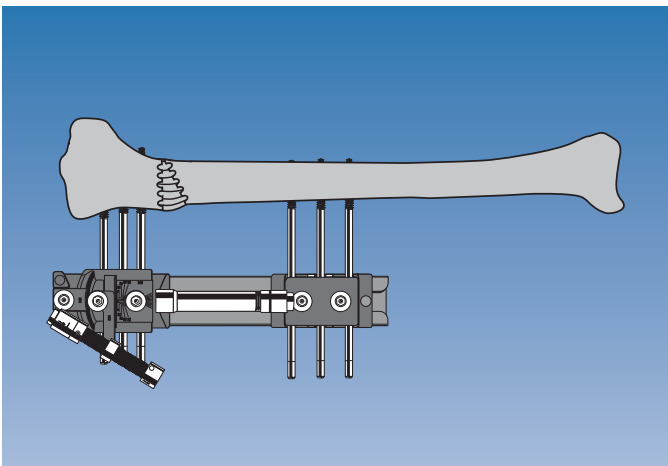


b) Correction is performed. As fixator is on concave side, angular correction will close distraction gap and simultaneously reduce soft tissue tension.



MICROMETRIC SWIVELLING CLAMP

Apply LRS with swivelling clamp, using template and screw guides.
Osteotomy: at least 15 mm from nearest bone screw, as near as possible to level of hinge.



Immediate on-table Correction

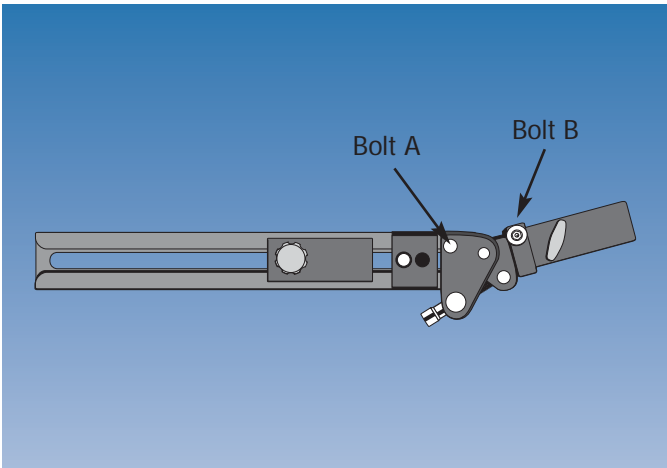
Loosen micrometric swivelling clamp on rail; loosen outer two clamp locking screws; perform correction, allowing clamp to slide on rail.

Late Correction through Callus Manipulation

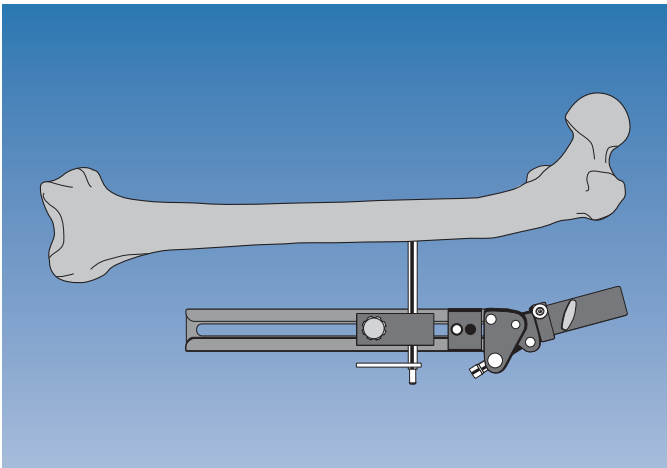
See "Protocol for use of Micrometric Correction Clamps", above.

MULTIPLANAR CLAMP

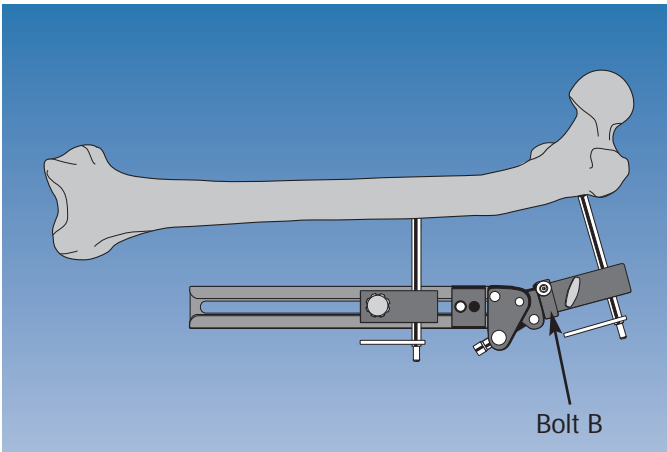
Assemble template and set angulator to plane of deformity. Tighten bolt A. Set hinge of angulator to angle of deformity with distractor.



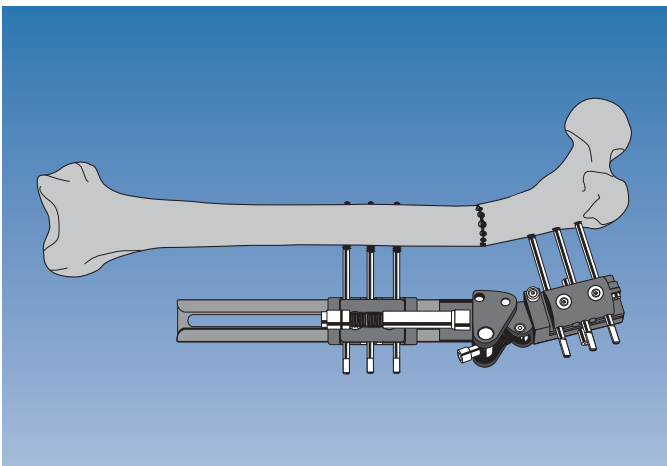
Mark position of CORA and bone screws on patient's limb. Hold assembly at correct distance from skin and adjust position so that hinge is at same level as either apex of deformed bone or bisector line of CORA. Insert bone screw through straight clamp template into longer bone segment, at 90° to axis.



Adjust distance between rail and skin to 2-3 cm. Insert screw guide and trocar through multiplanar clamp template. Check is at 90° to axis, in correct plane. If not, adjust position. Tighten bolt B. Insert second screw through multiplanar clamp template.

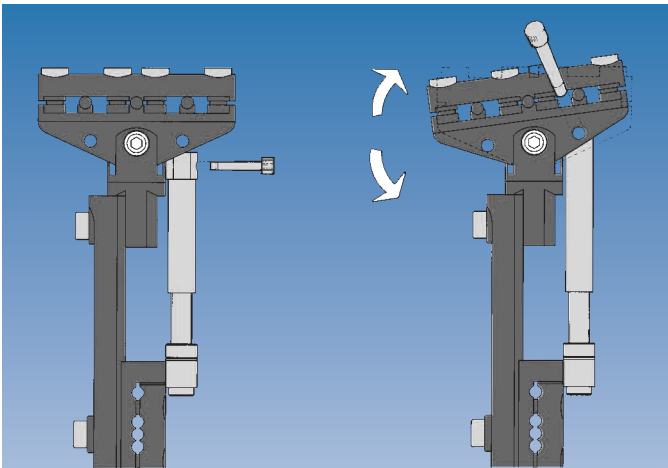


Insert all screws. In an adult, always use three screws per clamp. Remove screw guides and templates, apply rail with definitive clamps. Tighten firmly all clamp locking screws, perform osteotomy through apex of deformity. For correction, follow "Protocol for use of Micrometric Correction Clamps" described above.



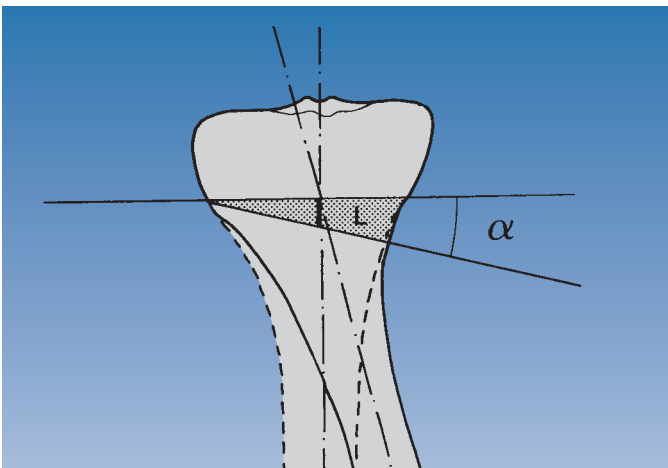
THE OF-GARCHES T-CLAMP

The OF-Garches T-Clamp may be used for lengthening, angular correction or a combination of the two. Gradual or immediate angular correction is possible.



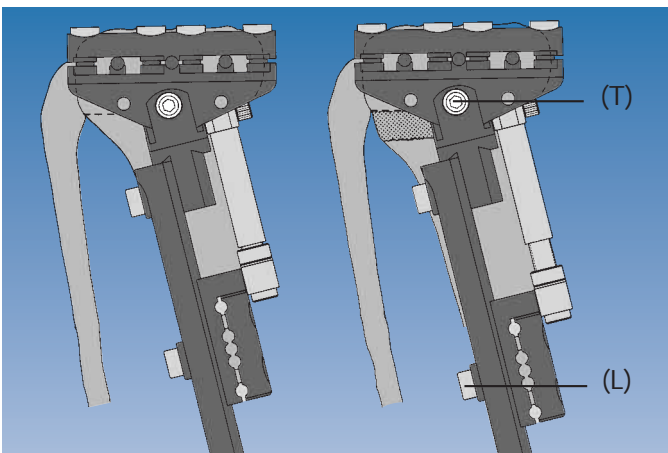
Gradual Correction

Determine pre-operatively distance L shown opposite by drawing anatomical axis of both deformed and corrected tibia.

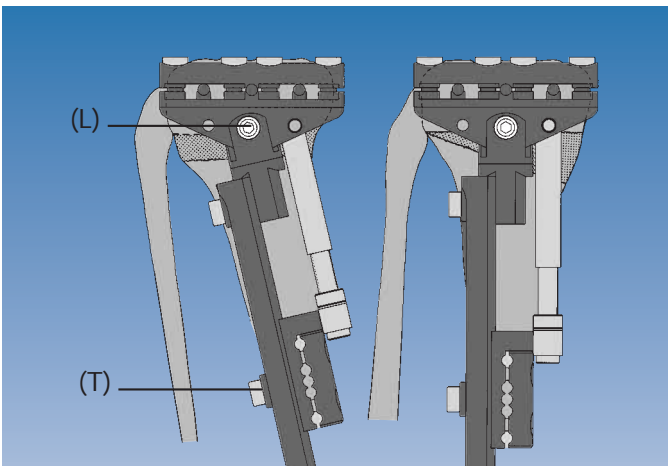


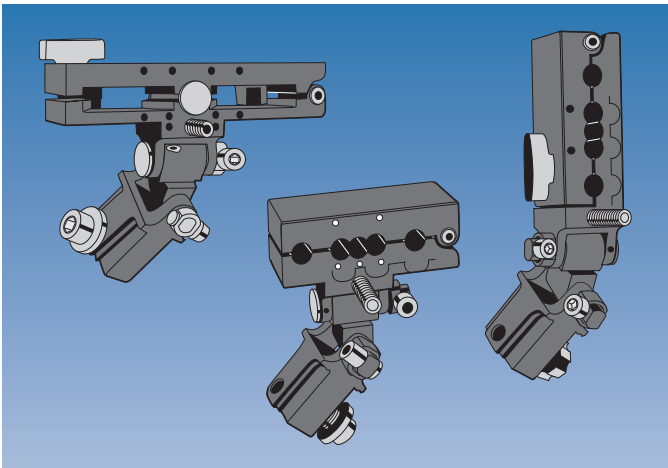
Perform complete tibial osteotomy just below insertion of patellar tendon, and a fibular osteotomy. Place compression-distraction unit in concavity of deformity and distract osteotomy according to principles of Callotasis, to amount equal to distance L above.

While distracting, clamp axis locking nut (T) should be tightened and straight clamp locking screw (L) loosened.



Change position of removable locking pin, and with clamp axis locking nut (L) loosened and straight clamp locking screw (T) tightened, distract to correct angular deformity. When correction complete, tighten clamp axis locking nut.



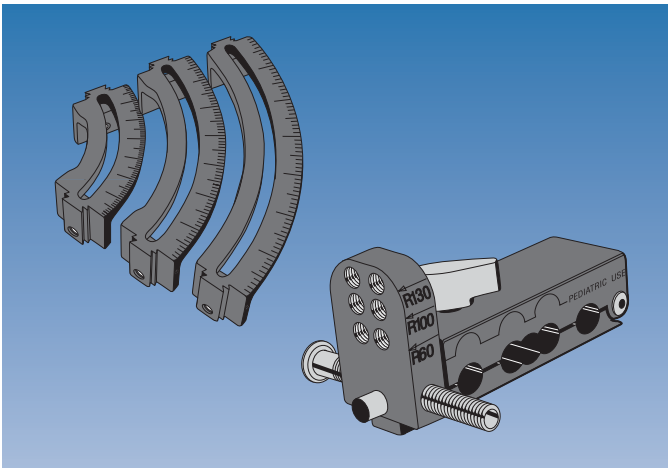


THE ACUTE CORRECTION TEMPLATES

Compatible with either adult or pediatric limb reconstruction system, they may be used to correct acutely an angular or rotational deformity, or combination of the two.

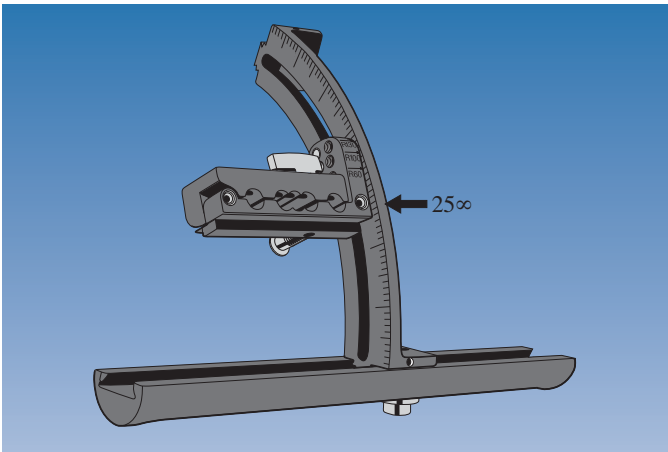
Angulation Templates

Allow correction in two planes. Two hinges on each clamp, one for alignment in coronal plane, the other in sagittal plane.



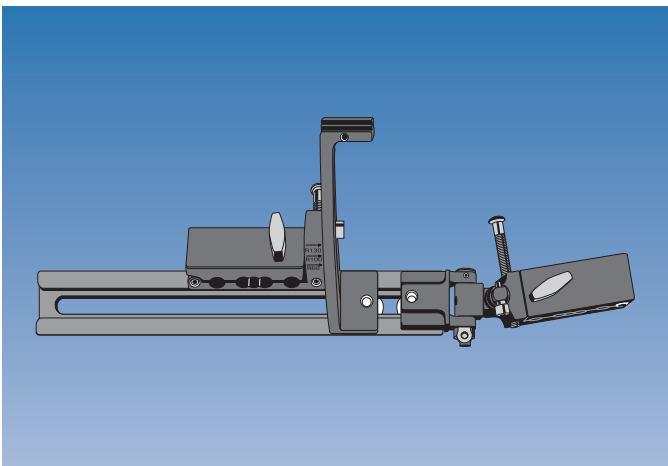
Rotational Templates

The template consists of two components: an arc and a template clamp.
3 arc sizes for different sizes of limb (60 mm, 100 mm, 130 mm).

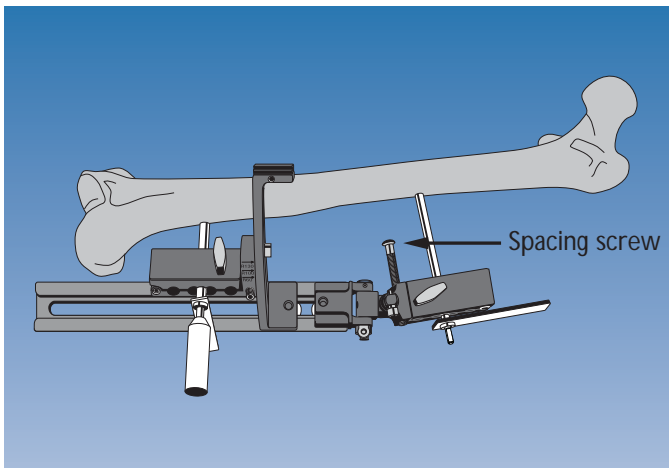


Example Application Showing Use of Angulation and Rotational Templates in a 20° Varus and 25° Internal Rotation Deformity

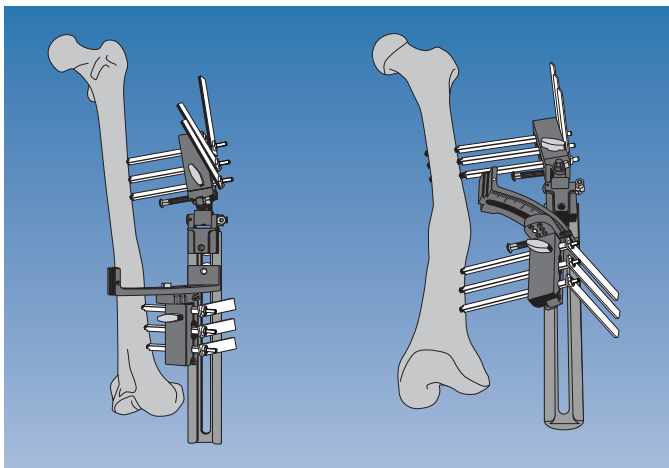
Choose correct size arc, so that distance between rail and bone is equal to radius of arc selected.
Attach template clamp (N.B. Use correct locking hole for arc size). Lock to arc at correct rotational position for screw insertion (in this case 25°).



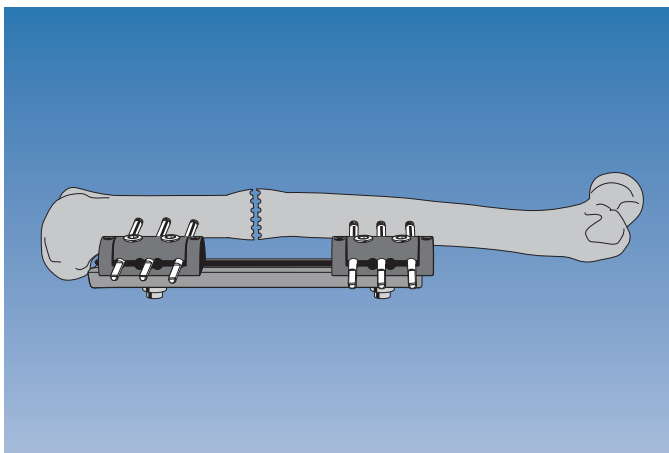
Attach angulation template; adjust to reflect varus deformity; tighten hinge locking screws.



Hold rail 3-4 cm from skin; advance spacing screws in both clamp templates until they touch skin.
Insert screw at 90° to bone axis, just proximal to apex of deformity.
Insert trocar through screw guide in clamp template on arc, down to bone. If template has been set up correctly, trocar will point towards center of bone, 90° to axis of distal femur. If OK, insert second screw. If not, adjust clamp until trocar points to center of bone.



Insert remaining screws, always 3 in each clamp in adults.

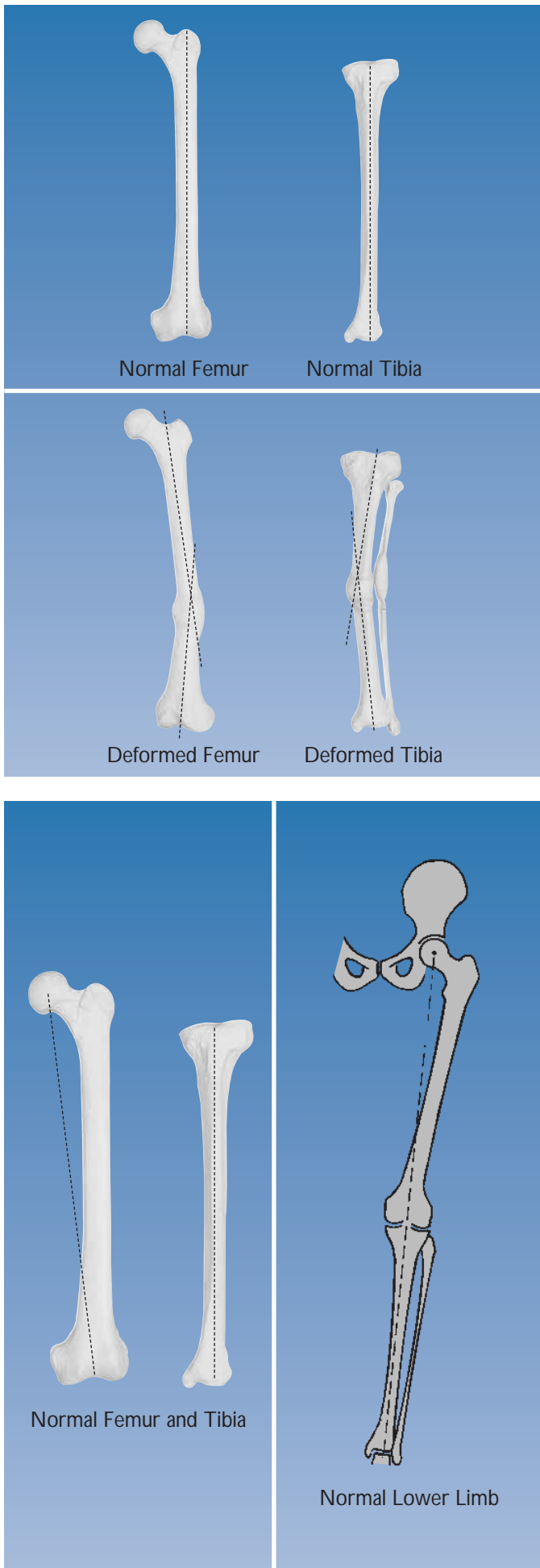


Perform osteotomy at apex of deformity; remove rail, and manipulate limb so that both pairs of bone screws are parallel. Apply LRS rail with standard straight clamps, and tighten clamp locking screws.

Deformity is a three dimensional problem. The correction of a deformity using the LRS, which is a monolateral, monoplanar fixator requires an understanding of the effects of adjustments or alterations in one plane on a three dimensional problem.

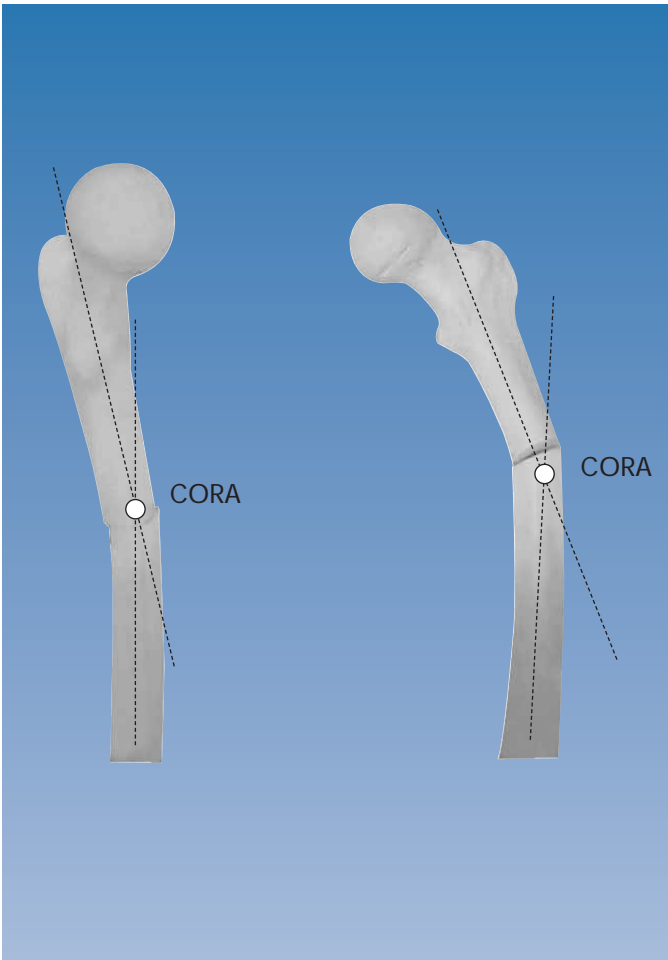
Anatomical Axis

The axis of the diaphysis of a long bone is the anatomical axis. In a deformed bone each segment of the bone will have a separate anatomical axis, and they will intersect.



Mechanical Axis

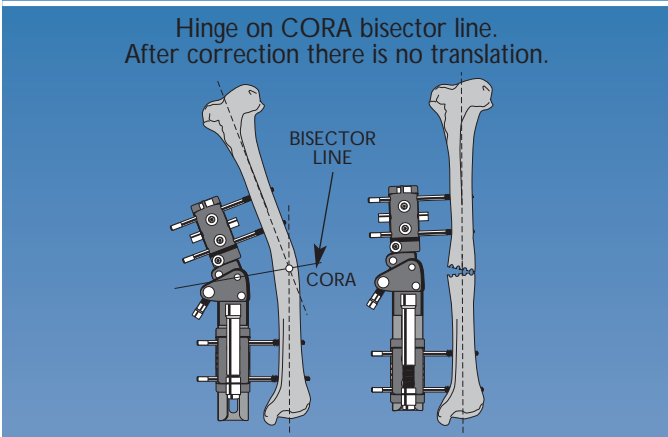
This is the line of force of the axial mechanical load in static weightbearing. In the tibia, it coincides with the anatomical axis. In the femur, it extends from the center of rotation of the femoral head to the center of the knee joint. For the lower limb, it extends from the center of the femoral head to the center of the tibio-talar joint, and should normally pass through the center of the knee joint.



CORA (Center Of Rotation of Angulation)

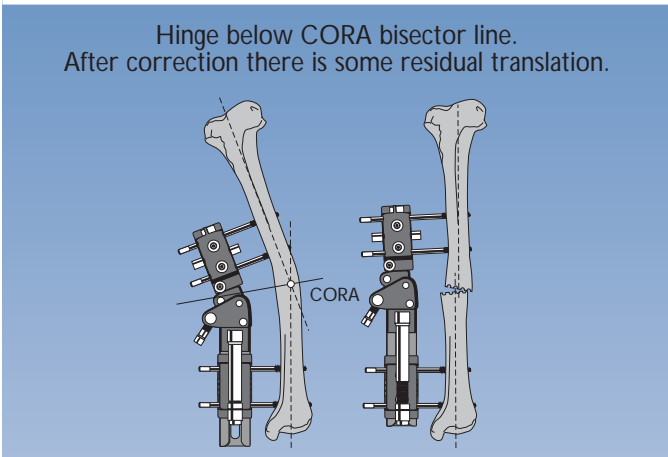
If the anatomical axis of each bone segment of a deformed bone is drawn on an X-ray, the lines will intersect. This is the CORA, and is an important reference point for angular correction. CORA is simple to determine in a deformed tibia, as the mechanical axis on either side of the apex of deformity is drawn along the center of the diaphysis. In a deformed femur, it is slightly more complex; the mechanical axis of the proximal femoral segment is normally estimated to be a line passing through the center of the femoral head, at right angles to a line from the center of the head to the tip of the greater trochanter, whereas the axis of the distal segment can be obtained by extrapolating the axis of the tibia in a retrograde direction, unless there is a knee joint level deformity.

Angulation only; CORA at apex of deformity

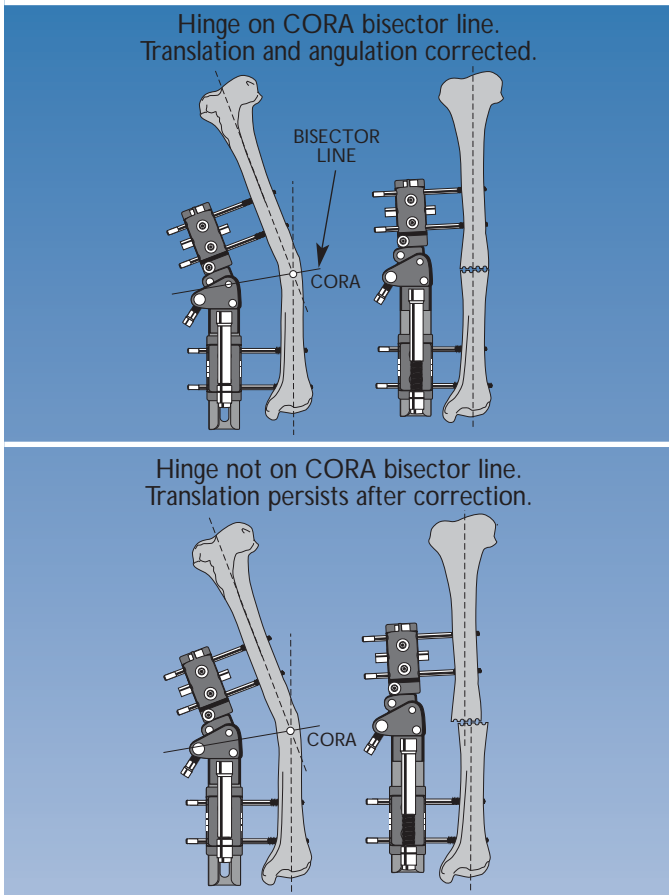


Bisector Line

This is a line which divides the angle of intersection of the axes of the two segments of a deformed bone into two equal halves. The center of rotation of the hinge of a monolateral gradual correction device should lie along this line, to minimise translation during correction. There is a difference here between monolateral and circular correction. In correction of a deformity with a circular frame, the hinges are placed exactly level with the CORA.



Angulation and translation; CORA below apex of deformity



Translation

It is important to recognise when translation is a component of a deformity. When the position of CORA does not coincide with the level of the apex of the deformed bone, the difference is due to translation being a component of the deformity. If the hinge of the monolateral correcting device is placed at the level of the apex of the deformity, correction will not remove the translation. However, if the hinge is placed on the bisector line of the CORA, correction of angulation and translation proceeds simultaneously.

Pre-Operative Planning

For the surgeon to define the goals of surgery precisely, it is essential that careful assessment of the deformity is carried out pre-operatively with:

1. Accurately aligned AP and lateral X-rays, to define the angular deformities in both the sagittal and coronal planes.
2. Calculation, by the graphical or mathematical methods described below, of the true plane of the deformity (see section below on gradual correction).
3. Careful assessment of any rotational deformity.
4. Assessment of any translation, as part of the deformity which requires correction.

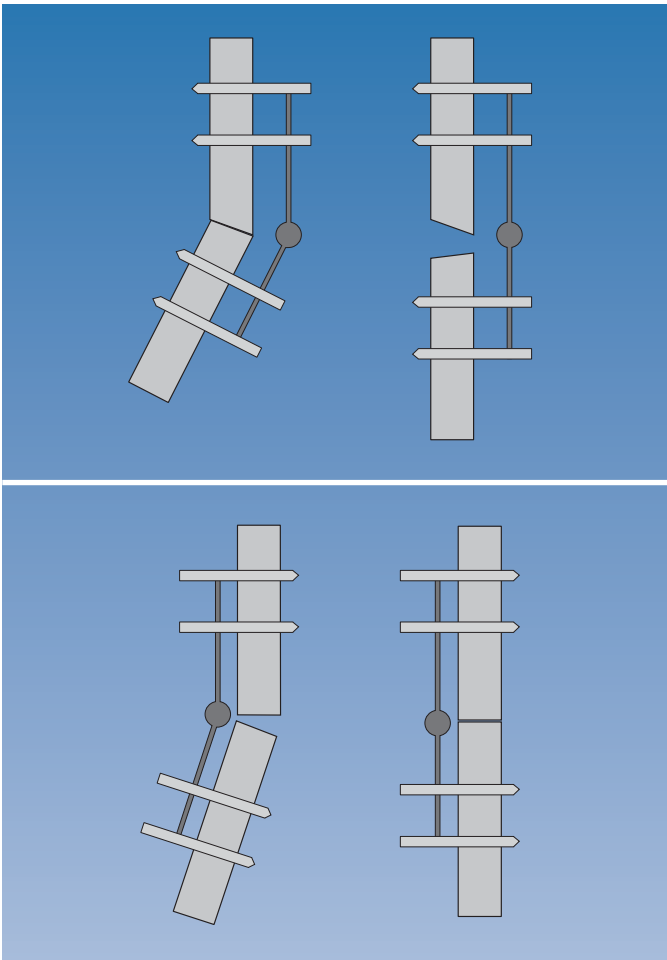
Acute or Gradual Correction of a Deformity?

The deformity may in some instances be corrected acutely at the time of application of the fixator. This is achieved with a controlled offset in two planes between two sets of bone screws during application, by use of the acute correction templates. The extent to which a deformity may be safely corrected acutely depends on the site and effect the correction has on local soft tissue tension. Particular care should be taken when correcting a deformity of the proximal tibia, because of the danger of damaging the peroneal nerve.

Gradual Correction

When monolateral fixation is used, the following points should be born in mind:

- I. In a deformity in which the fixator is placed on the **convex** side of the deformity, angular correction through the micrometric clamp will **distract** the osteotomy.
- II. Conversely, if the fixator is placed on the **concave** side of the deformity, **compression** will occur at the osteotomy. If a sufficient osteotomy gap is not present, the bone ends will jam and prevent further correction.



Acute Correction

The acute correction templates are designed to allow for accurate placement of the two sets of bone screws. They are **not** designed to be left in place while the correction is made. In this way, the above effects of distraction or compression of the osteotomy site during correction are avoided. They are designed to be replaced by two standard straight LRS clamps. If the bone screws have been placed correctly, the manipulation to seat the screws into standard straight LRS clamps should complete the required correction.

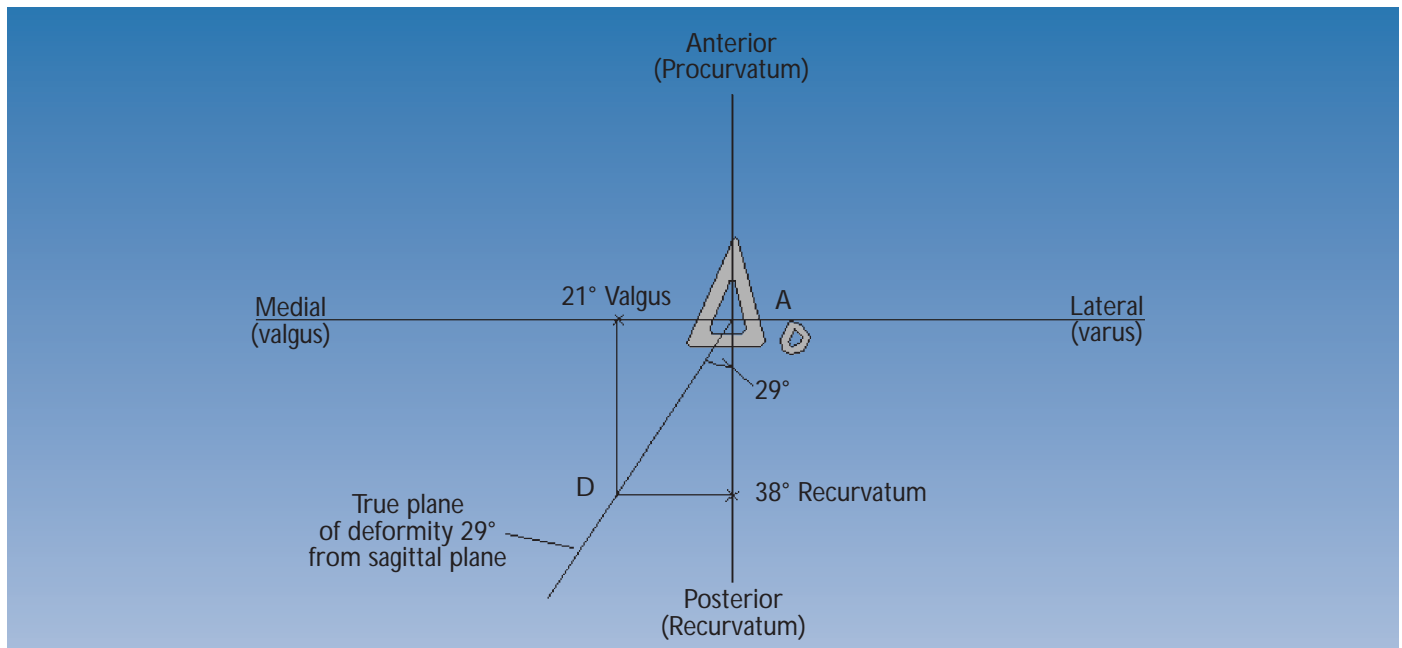
Calculation of the True Plane of the Deformity

Unless the position of the deformity is obvious, as in a malunion of a previously normal limb, initial assessment of any lower limb deformity should include full length weightbearing X-rays of both legs, with a complete axis evaluation to determine the position of the deformities.

The method by which the true plane of deformity (and hence the plane of correction) is derived is as follows. Accurately aligned AP and lateral X-ray views are taken. The angulation of the deformity in each view is measured with a goniometer.

Graphical Method

Using graph paper, X and Y axes are marked with the center of the bone at the intersection (abscissa); anterior, posterior, medial and lateral positions are then indicated. The amount of the deformity, in degrees, is plotted on each axis to the same scale; e.g. a deformity which measures 21° valgus on the AP x-ray is marked along the x-axis in a medial direction - a simple way to remember this is to think of a valgus deformity as one with the apex pointing medially, and to mark the size on the graph paper in the medial direction. Similarly, a recurvatum deformity which measures 38° on the lateral x-ray is plotted in a posterior direction (recurvatum = apex posterior). Orthogonal lines are drawn from these points so that they intersect, and a line drawn from this intersection to the zero position (see figure below). This is the plane of the deformity. The deviation of this plane from the sagittal or coronal planes can be measured directly off the graph paper: if millimeter-square graph paper is used, and the scale adopted for plotting is one millimetre to one degree, then the length of the line (AD), in millimetres, connecting the abscissa to the intersection of the two orthogonal lines, is the size of the deformity in degrees, and the angle it subtends with either the coronal or sagittal planes measures the plane of deformity. In this example, it is 29° from the sagittal plane, or 61° from the coronal plane, lying in a posteromedial to anterolateral direction. Measurement of the length of the line AD will provide the amount of correction required, in this case 43°.



Mathematical Method

Alternatively, these parameters can be derived trigonometrically from the known angles of the deformity in the AP and lateral planes as follows:

X° = the AP (procurvatum/antecurvatum) angulation Y° = the varus/valgus angulation

The deviation of the deformity from the sagittal plane is $X/Y^\circ \tan^{-1}$. So, from the numbers indicated in figure above, it can be seen that this tibia has a deformity of 21° of valgus and 38° of recurvatum. The plane of correction is therefore $21/38^\circ \tan^{-1}$, which again is 29° from the sagittal plane, and the amount of correction required is $\sqrt{21^2+38^2} = 43^\circ$.

The true plane of angular deformity is the plane in which the hinge of the fixator clamp should be positioned.

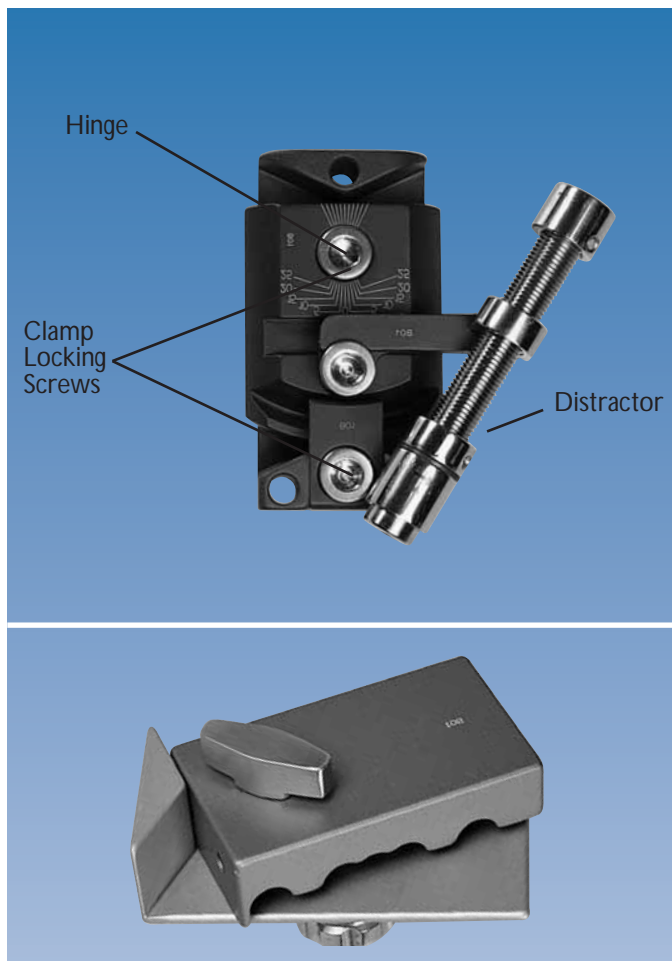
This section focuses on the use of the micrometric clamps in the correction of angular deformity.

THE PLANE OF DEFORMITY


Angular deformity can exist in any plane. If present in the coronal plane, it will be seen in profile on an AP X-ray, whereas the lateral view will show a 'straight' bone. Similarly an angular deformity in the sagittal plane is seen only in the lateral view. If the angulation lies in a plane neither coronal nor sagittal, i.e. an oblique plane, then some deformity is visible on both AP and lateral X-rays. It is a common misconception to think of two deformities, when in reality there is only one, lying oblique to the standard coronal and sagittal planes.

This understanding of angular deformities is central to the use of the LRS with the micrometric clamps, because correction through the clamps must occur in the plane of the deformity. In the simplest example, a valgus or varus deformity is corrected with the adjustments made in the coronal plane.

The Micrometric Swivelling (50111) and Multiplanar Clamps (50580) act by adjustments being made around a center of rotation (hinge). A compression-distraction device, "distractor", is used to drive the correction.



With the Micrometric Swivelling Clamp, the center of rotation functions in the same plane as that of the bone screws. For the clamp to work correctly, the screws (and hence the plane of rotation) must lie in the plane of the deformity, and therefore the LRS rail must be applied in the plane of the deformity. So, in the case of a varus or valgus deformity the LRS is applied in the coronal plane, and for a procurvatum or recurvatum deformity in the sagittal plane. Note that sagittal plane application is possible in the tibia but not in the femur; therefore angular correction with the Micrometric Swivelling Clamp is only possible when the plane of deformity corresponds to a safe corridor for screw insertion.



The Micrometric Multiplanar Clamp overcomes this restriction, enabling the surgeon to deal with angular deformities in planes which do not correspond to a safe corridor for the bone screws. This, like the swivelling clamp, also has a center of rotation, but its plane of action can be altered independently of the plane of the bone screws. The central part of the body containing the hinge is called the angulator and can rotate through 360°. Any angular deformity can therefore be corrected.

The Micrometric Swivelling and Multiplanar Clamps, each with their own template for screw insertion, are only available for use with the Adult LRS Rail. Paediatric versions are not available.

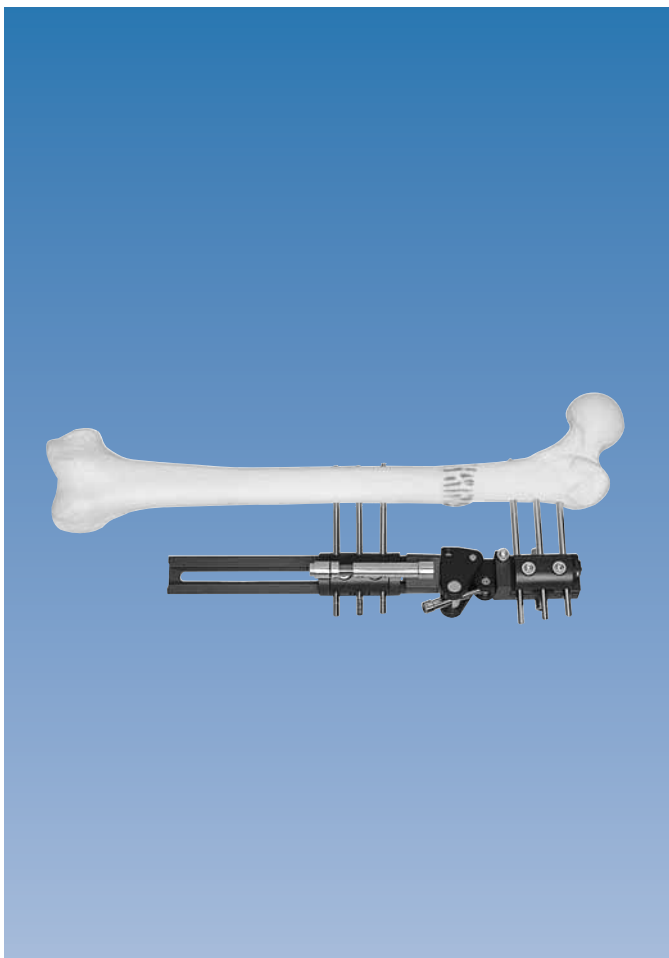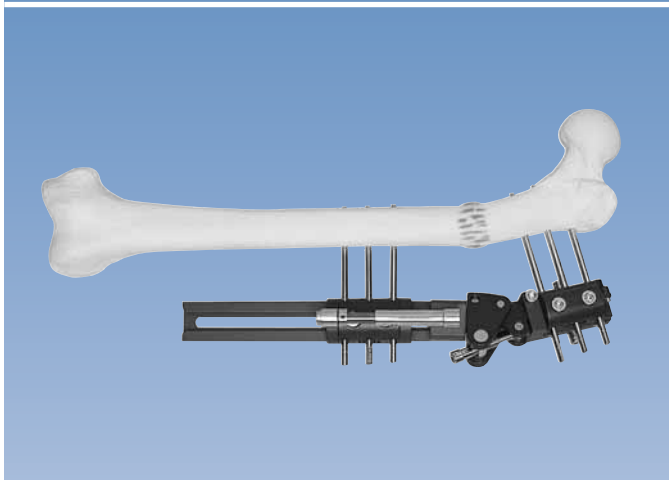
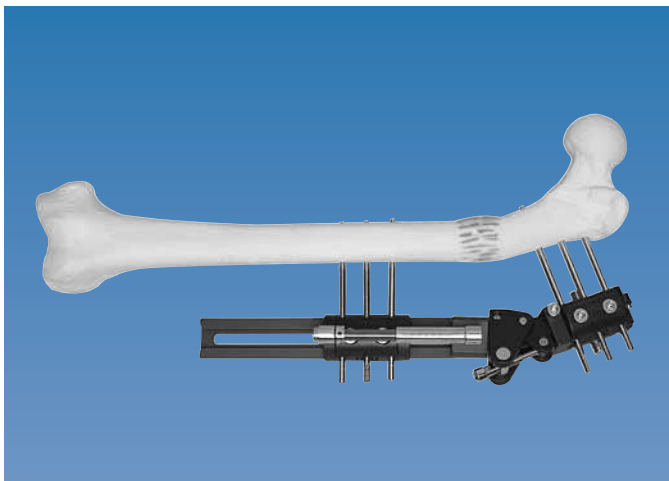
POSITION OF THE CENTER OF ROTATION OF THE CLAMP

The apex of an angular deformity is the center of rotation around which correction of the deformity should occur. However in any monolateral system which performs gradual micrometric correction, the center of rotation of the correcting device seldom coincides with this. It is simply a reflection of the fixator lying to one side of the bone.

Reminder:

- I. In a deformity in which the fixator is placed on the **convex** side of the deformity, angular correction through the micrometric clamp will **distract** the osteotomy (see figure above on page 4).
- II. Conversely, if the fixator is placed on the **concave** side of the deformity, **compression** will occur at the osteotomy. If the osteotomy gap is insufficient, then the bone ends will jam and prevent further correction from being possible (see figure below on page 4).
- III. It is possible with the multiplanar clamp that the angle of required correction will be at 90° to that of the bone screws. This situation would arise when the bone screws are in the coronal plane, but the deformity is solely in the sagittal plane. In this case correction will not produce compression or distraction.

This effect of the location of the center of rotation must be anticipated, because it determines how the micrometric clamps are used. The procedure is a little different depending on whether the fixator is on the concave or convex side of the deformity. One additional compression-distraction unit is needed to alter the distance between the micrometric clamp and the adjacent straight clamp.



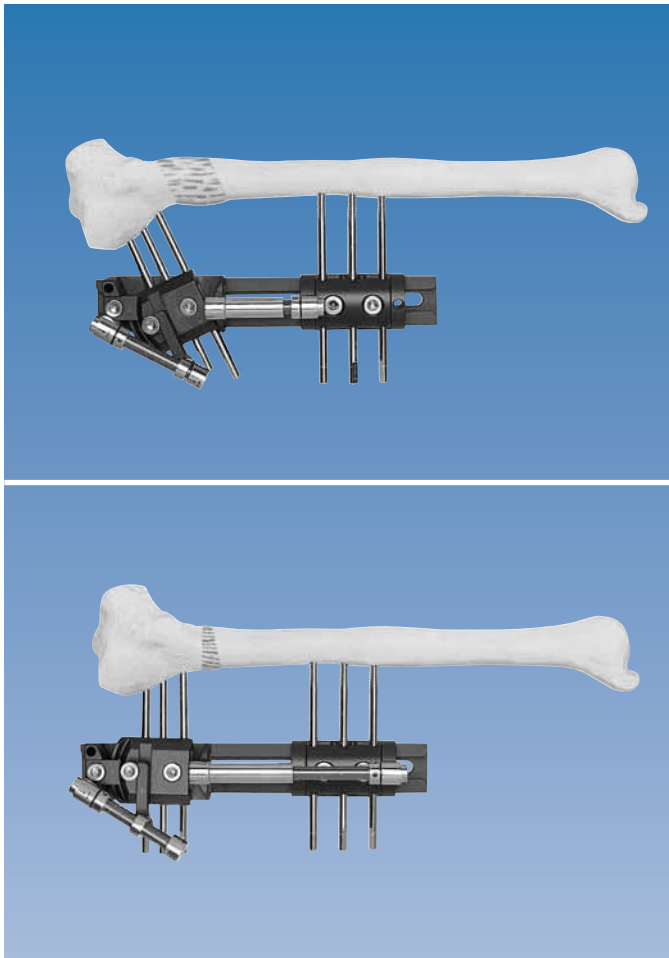
An essential step in the correct use of these devices is to reduce the soft tissue tension before making the micrometric correction of angulation, irrespective of the type of micrometric clamp being used. The technique is as follows:

Fixator on Convex Side of Deformity

- a) The osteotomy is distracted with the compression-distraction unit in accordance with the principles of callotasis. When a sufficient distraction gap has been obtained, angular correction can begin, as follows:
- b) With the patient relaxed on a couch, the soft tissue tension is first reduced by shortening with the same compression-distraction unit acutely by 4-5 mm, i.e. the distraction gap is partially closed.
- c) This is immediately followed by angular correction through the 'distractor' of the micrometric clamp, which is turned until tension is felt to build up again (at this point, the distractor of the micrometric clamp becomes increasingly difficult to turn and little angular correction takes place when turning).
- d) Steps (b) and (c) are repeated until the angular correction is complete. The entire procedure is thus performed in one stage and is relatively painless to the patient, as the column of callus is manipulated gradually, with care taken to reduce soft tissue tension each time. Because the center of rotation of the clamp is on the convex side of the deformity, it will distract at the osteotomy site. On completing angular correction, X-rays are performed to confirm satisfactory conclusion of the procedure and for assessment of length. Any final adjustments in length are performed with the compression-distraction unit.

The initial lengthening is important to provide a column of early regenerate which is then amenable to compression (which reduces soft tissue tension) and manipulation (which achieves the correction). Without this step, there may be excessive friction in the distractor unit of the micrometric clamp during angular correction, causing the unit to jam or strip its threads.

Fixator on Concave Side of Deformity



- a) Initial lengthening as before according to the principles of callotasis.
- b) As previously, when a sufficiently large distraction gap is created, angular correction may then begin, but here, unlike the description above with the fixator on the convex side of the deformity, there is no need to reduce soft tissue tension initially. This is because angular correction performed with the fixator on the concave side will close the distraction gap and simultaneously reduce soft tissue tension. However, if the distraction gap is too small, the bone ends may meet and jam, preventing any further correction. This should be prevented by adequate preoperative planning, which includes an estimate of the initial lengthening required before angular correction begins.

General Points

- a) Note that some lengthening is required before angular correction, whatever the position of the fixator in relation to the deformity. The amount of lengthening will depend on the bone-fixator distance, and the degree of correction to be achieved, and cannot be generally defined. An estimate can be made from a knowledge of these two parameters in the individual patient and the pre-operative plan.
- b) If the patient's deformity is purely an angular one, and does not require lengthening, but is not suitable for acute correction, the patient should be offered the option of a circular frame, which will allow immediate gradual correction without lengthening. However, in the femur the disadvantage of 7-14 days of callotasis may be offset by the advantage of having a monolateral frame.
- c) It is very important that the angular correction facility of the micrometric correction clamps is not used to gain length primarily, when the correction is from the convex side of an angular deformity. The tissue tensions involved may be great, and can be sustained only by the standard compression-distraction units. The technique of lengthening, shortening and then angular correction as described above avoids this problem.
- d) If the angulator of the multiplanar clamp is at 90° to the plane of the bone screws, so that compression or distraction of the osteotomy during correction will not occur, initial lengthening is not necessary.
- e) Careful monitoring of the patient during a micrometric correction is essential.

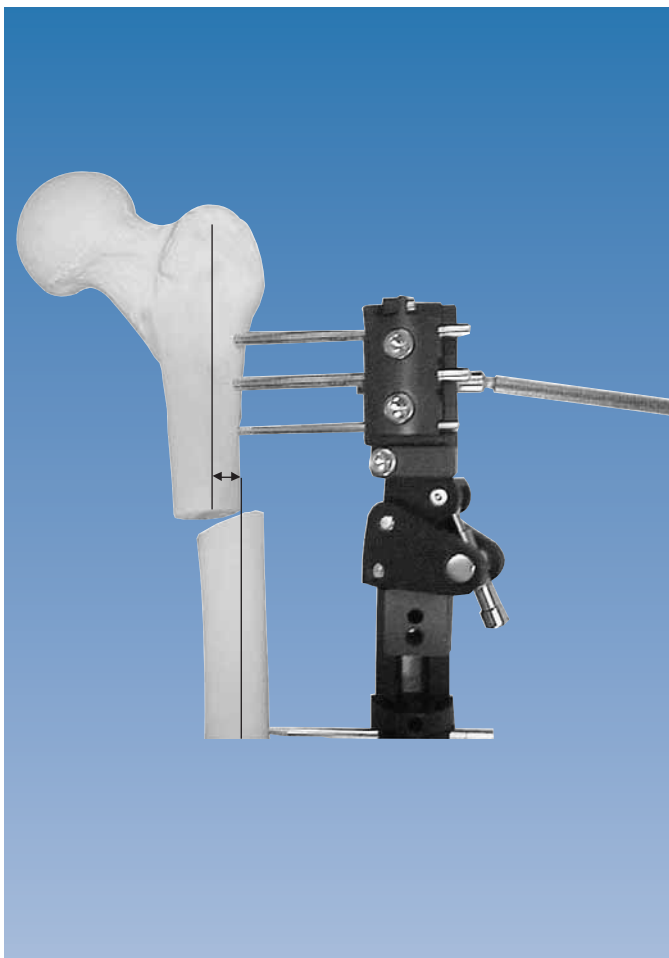
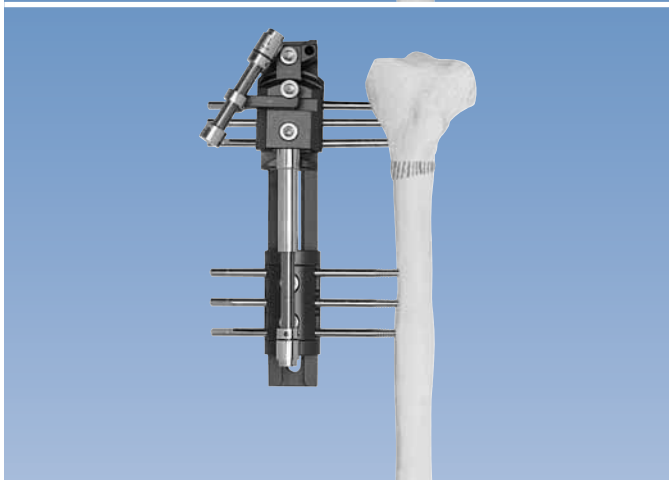
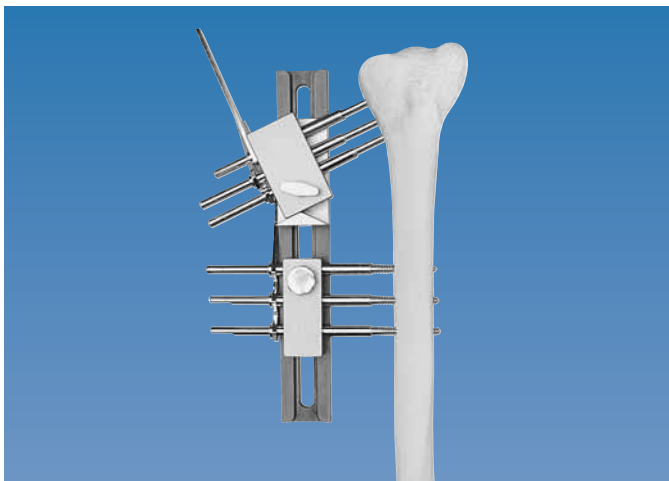
Translation and the Micrometric Clamps


If the center of rotation of the clamp is placed level with the osteotomy site, translation should not occur. If it is sited either above or below the osteotomy, then translation will occur, and sometimes may be required, e.g. if the deformity includes both angular and translational components in the same plane.

Preoperative analysis of the anatomical axis of each segment of the bone must be performed, by drawing on or tracing over the X-ray films. This may show that the true apex of the deformity (CORA: see section on Basic Considerations) lies above or below the apex of the deformed bone, and suggests both angulation and translation are components of the deformity. By matching the location of the center of rotation of the clamp to that of the CORA as indicated from anatomical axis planning, but carrying out the osteotomy at the apex of the deformed bone, both components can be corrected simultaneously.

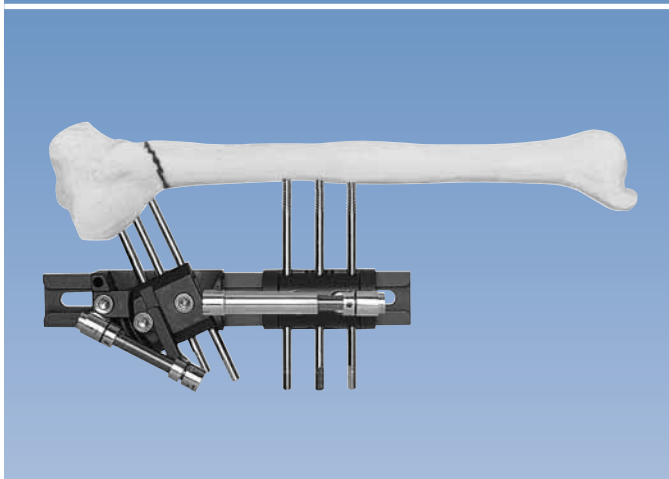
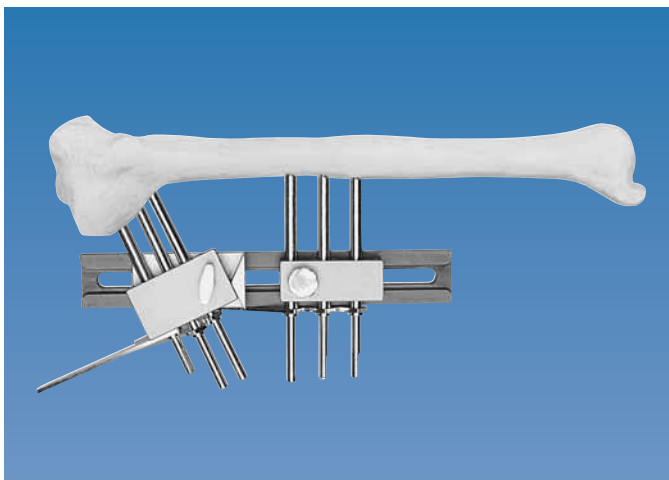
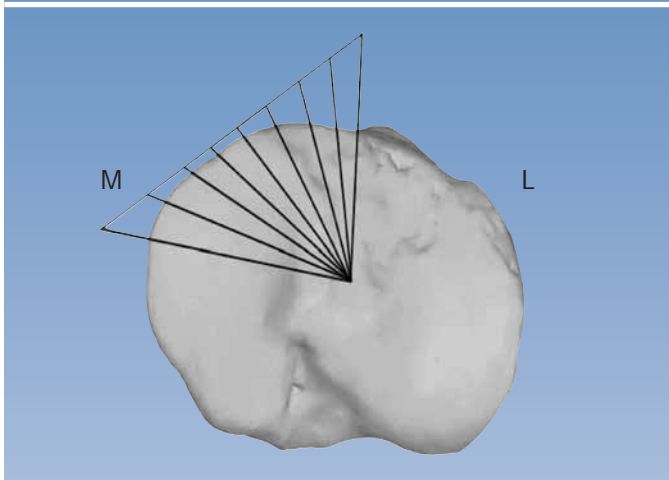
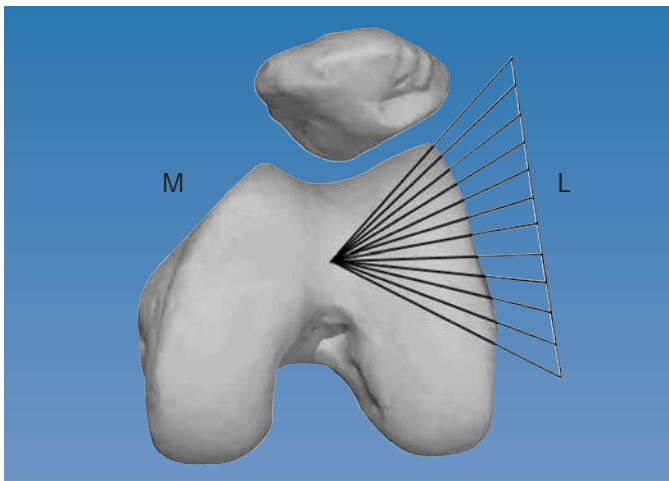
With the Micrometric Swivelling Clamp, translation which occurs as a result of angular correction may or may not need addressing, depending on its magnitude and effect on the position of the mechanical axis of the entire limb. If the translation is large, then correction is achieved by sliding the screws either in or out of the clamp under a general anesthetic.

In the case of the Micrometric Multiplanar Clamp, any unwanted translational effects can be compensated for by a gradual correction facility, which allows a maximum of 12 mm of translation in one direction.





The OF-Garches T-Clamp (50546), and the Pediatric version (55031) can be used for micrometric correction of valgus or varus alignment in the proximal tibia (see page 17). Because the axis of rotation of the T-clamp passes through the center of the osteotomy or lengthened segment, translation should not occur during its use.



With this clamp the plane of correction will be in the plane of the bone screws. It should only be used, therefore, when the plane of required correction is a suitable one for screw insertion. The following figure gives an indication of the possible planes of screw insertion in the femur and the tibia.


This clamp can be used either to correct a deformity intra-operatively, or to make a correction post-operatively by callus manipulation. There are five screw seats which match those of the standard clamp. The clamp is applied by removing a straight clamp from an existing rail and replacing it with the swivelling clamp. Screws are inserted in the plane of the desired correction. The hinge on the clamp should be placed as close as possible to the level of the planned osteotomy. In view of the fact that the hinge will be offset from the pivot point of the bone, a translational effect may be anticipated during the correction. After osteotomy, therefore, the bone should be translated in the opposite direction to compensate for this effect.

1. IMMEDIATE ON-TABLE CORRECTION

Note that the angulation templates may also be used for this purpose (see page 22). These templates can be used for an intra-operative correction, provided that the final position of the bone screws is to be at 90° to the rail, because the screws will be held in a standard straight clamp. However, if these templates are not available, or if the final position of the bone screws is not at 90° to the rail, the swivelling clamp may be used.

The bone screws are inserted in the normal way through screw guides mounted in the swivelling clamp template (adult 14116; pediatric 15520), which has been previously set to the desired angle.

When the remaining bone screws have been inserted, the Limb Reconstruction System is applied with a swivelling clamp in the appropriate position. An osteotomy is performed, at least 15 mm from the nearest bone screw, but as close to the hinge of the swivelling clamp as possible.



It is important to note that for correction to be made, the two outer locking screws (A & B) in the swivelling clamp must be loosened. The central screw (C) should remain tight, because it anchors the distractor unit in place. Correction at the osteotomy site is performed, after which all locking screws are tightened.

As the correction occurs, there will be shortening or lengthening of the bone segment, depending on whether the fixator is on the concave or the convex side of the deformity. In the former case, a compression-distractor unit can initially be used to open the osteotomy gap sufficiently to prevent the bone ends from binding on angular correction. For on-table correction, it may be helpful to loosen the screw which locks the clamp to the rail, to allow for axial movement of the clamp during correction.

Alternatively, the distractor unit can be removed, and the correction can be made by manipulation.

If the final position of the bone screws is at 90° to the rail, the swivelling clamp may be replaced with a straight clamp.

2. LATE CORRECTION THROUGH CALLUS MANIPULATION

This technique with the Micrometric Swivelling Clamp may be used either to carry out a planned correction, or to carry out a correction of an unexpected angular deformity during lengthening. It should be noted that minor degrees of angular deviation are commonly found with larger amounts of lengthening. With the distractor unit in place, the clamp is as strong as a standard straight clamp, and the added ability to correct valgus or varus deformities without the need for further surgery may prove very useful. It is therefore advised that this clamp is included in the original assembly when lengthening in excess of 3 cm is anticipated. However, the soft tissue tension will already be substantial. **It is therefore very important that the surgeon shortens the new callus prior to correction, as described in the protocol for use of the micrometric clamps.**

a) Planned Later Correction

The bone screws are inserted through screw guides mounted in the swivelling clamp template, as above. The two clamp cover locking screws (A) & (B) above, are partially loosened with care. Note that any angular correction must be preceded by lengthening, and the procedure should be carried out according to the protocol described under "Protocol for the Use of the Micrometric Correction Clamps", on pp. 8-11. It is important to note the differences in the described procedure, according to whether the deformity is convex or concave towards the fixator.

b) Correction of an Unexpected Deformity during Lengthening

Once again, it is important to realise that the swivelling clamp can only correct deformities in the plane of the bone screws. In this case the micrometric swivelling clamp is used to replace an existing straight clamp, at any position on the rail. This can only be performed if the rail and clamps are temporarily removed. The segment must first be stabilized by means of a parallel fixator placed externally to the Limb Reconstruction System. The original rail and clamps are removed and the Micrometric Swivelling Clamp is placed on the original rail in exchange for a straight clamp, at the level of the deformity. This rail is now replaced on the bone screws, and all the clamps and clamp locking screws are locked firmly as before. The temporary rail and clamps can now be removed. Correction of the angulation can now be undertaken as described in the previous section, provided that there is still some soft callus present. If the callus has matured to the point where it will be difficult to perform any correction, an osteotomy will be required. If the status of the callus is in doubt, the patient may be given a short general anesthetic, to allow the surgeon to exchange the clamp, and test the callus for maturity, proceeding to an osteotomy if necessary.

This will be used at either end of an LRS rail to correct an existing angular or translational deformity. The plane and size of deformity will have been determined through preoperative planning by one of the methods described above. If only angulation is present, then preoperative anatomical axis planning will reveal an apex (CORA) which coincides with the apex of the deformed bone. When the CORA lies either above or below the apex of the deformed bone, translational deformity co-exists. Translational deformity, if present, will need careful assessment; the size of this deformity and its plane will determine if a monolateral fixator system is appropriate.

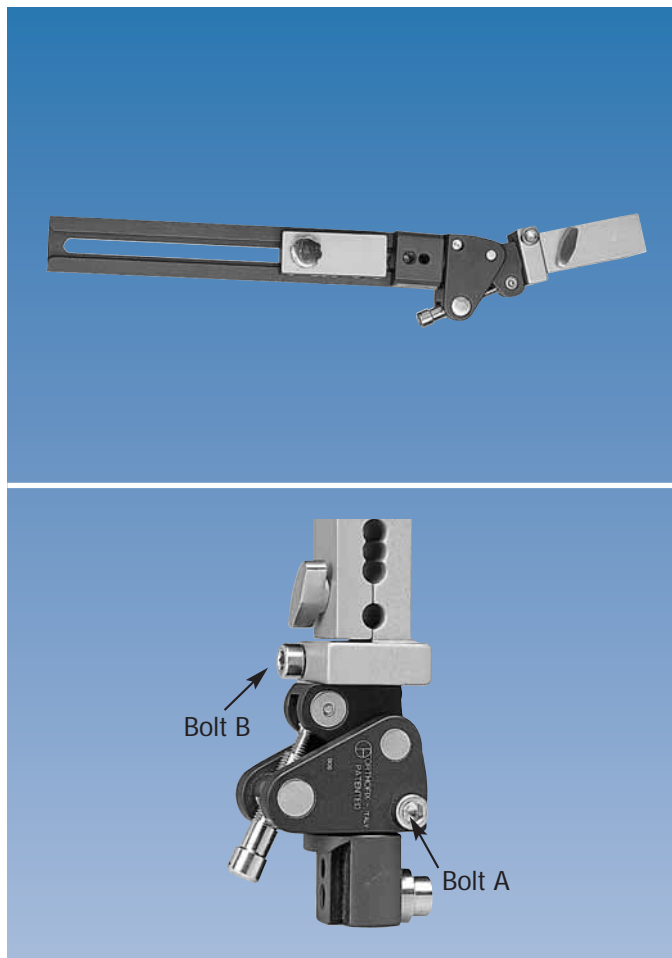
If the CORA is sited in the same position on both AP and lateral X-rays, the translational and angular deformities are in the same plane. In this case, correction with the multiplanar clamp is straightforward. It is achieved by placing the center of rotation (axis of hinge) of the multiplanar clamp at the level of the CORA, and aligning the hinge of the multiplanar clamp so that it acts in the plane of the deformity.

The multiplanar clamp with the LRS is also indicated in deformities where the plane of translational deformity, although different from the plane of angular deformity, coincides with a safe corridor for the insertion of bone screws. The bone screws are inserted through this safe corridor, in line with the plane of translational deformity, and the translation is then corrected through the gradual correction facility on the clamp. Angular correction is dealt with separately by aligning the hinge on the clamp with the plane of the deformity.

If the translational and angular deformities are not in the same plane, and the translational deformity is not in a plane suitable for screw insertion, correction with the multiplanar clamp is not recommended, and a circular frame should be used.

For the multiplanar clamp to function correctly, the following objectives have to be accomplished during surgery:


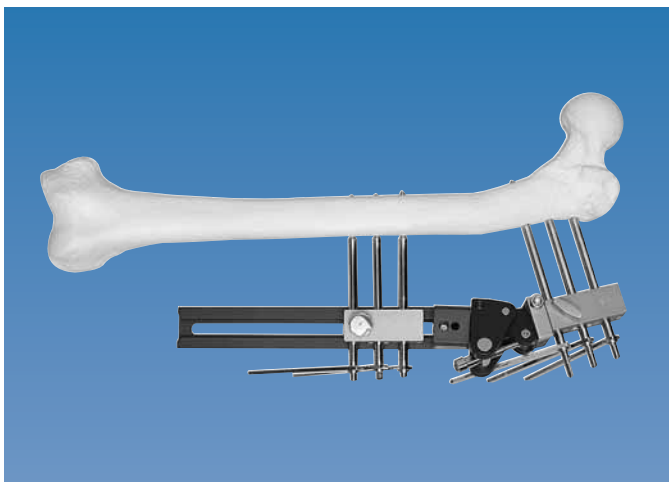
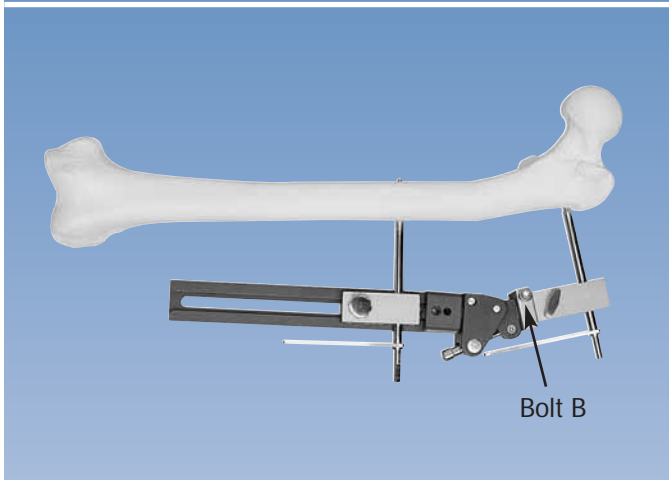

- a) Depending on preoperative planning, the center of rotation (hinge) of the multiplanar clamp must be placed on the bisector line of either:
 - I) The apex of the deformed bone (when translational deformity is absent, or if present, correction is envisaged through the micrometric facility on the clamp), or
 - II) At the apex of the deformity derived from anatomical axis planning (the CORA), when both angulation and translation are to be corrected in the same plane.
- b) Screws are inserted on both sides of the apex of the deformed bone, perpendicular to that segment of bone
- c) The osteotomy is performed at the apex of the deformed bone
- d) The steps in correction are as described in the protocol above, depending on whether the hinge of the multiplanar clamp lies on the convex or concave side of the deformity (see pp. 8-11).



Application Technique

A standard template clamp is mounted on an LRS rail, and the multiplanar clamp (with its template element) attached to one end. Both template clamps are fixed to the LRS rail with the correct locking screws.

The angulator of the multiplanar clamp is set to the plane of the deformity determined by pre-operative planning, and locked in this position by tightening bolt A. This plane is measured relative to the plane of screw insertion, either the sagittal or coronal planes in the tibia, or the coronal plane in the femur. The hinge of the angulator is now set to the angle of the deformity determined from the pre-operative planning, by turning the distractor.



The assembly is held at the correct distance from the skin, and the position of the rail adjusted so that the center of rotation (hinge) of the multiplanar clamp lies at the same level as either the apex of the deformed bone or the bisector line of the CORA, as dictated by the results of pre-operative planning. The positions of the CORA and bone screws are marked on the patient with a skin pen, bearing in mind the plane of screw insertion.

If the pre-operative assessment of the angle and plane of the deformity has been performed correctly, a trocar held in each template clamp should be at 90° to the axis of each bone segment. If this is not the case, the situation should be re-assessed, and the angle or plane of the angulator adjusted accordingly. An appropriately sized bone screw is inserted into the longer bone segment through a screw guide in the straight clamp template, on one side of the apex of the deformity, paying due attention to safe corridors and using X-ray guidance to ensure it lies in the center of the bone, perpendicular to the axis of that segment.

The distance between the rail and the skin is adjusted to 2-3 cm. A screw guide and trocar are inserted through the clamp template on the multiplanar clamp; if the prior frame assembly was correct, the trocar should lie in the plane of the deformity and point at right angles to the segment of bone. If not, minor adjustments through rotation of the clamp template and adjustment of the angulator should be made. The clamp template is then locked in this position by tightening bolt B. A second bone screw is inserted through the clamp template in the usual manner, ensuring it points to the center of the bone. The entire assembly should now be supported on the limb by one bone screw on each side of the deformity.

The remaining bone screws are now inserted through both clamp templates. In an adult, there should be three screws evenly spaced in each clamp.

The definitive clamps are now substituted for the clamp templates. All the clamp locking screws are tightened firmly, and the osteotomy performed through the apex of the deformity in the usual manner for intended callotasis. The steps for correction now follow as described on page 8. Because the multiplanar clamp permits angular correction in a plane different from the plane of insertion of screws (unlike the micrometric swivelling clamp), the protocols described earlier still apply, but it is the hinge position in relation to the convexity or concavity of the deformity which is relevant, not just the position of the fixator. When correction is complete, the Multiplanar Clamp should finish up in line with the LRS rail.

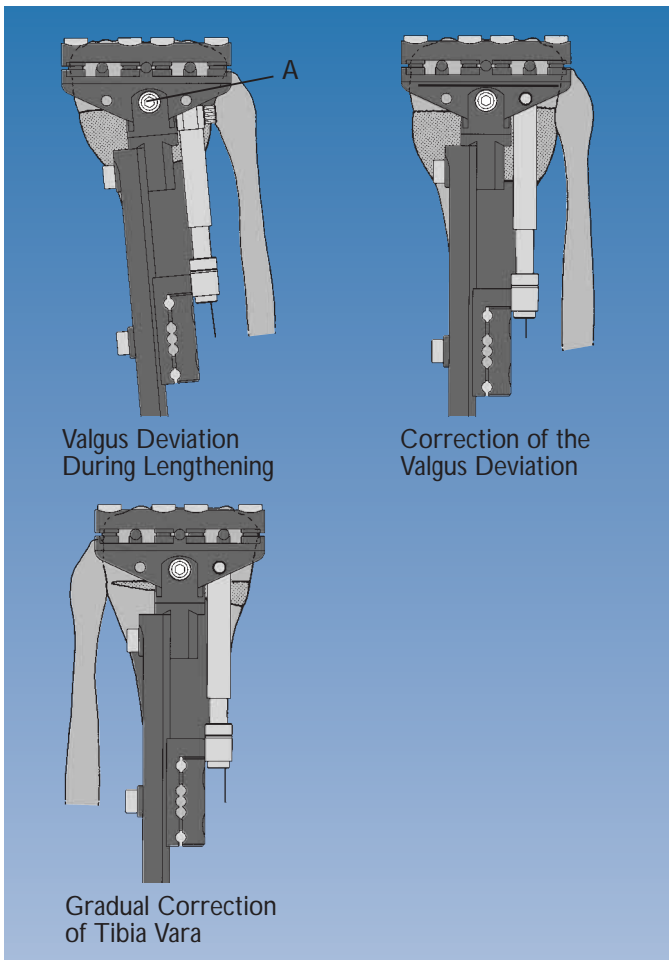
As the Multiplanar Clamp is fixed to the end of the rail, the new bone segment should be dynamized by releasing the clamp locking screw of the adjacent straight clamp, protected if necessary by a Dyna-Ring.

In an ideal world, this situation will never arise, but experience shows that it will occur occasionally. Correction should be complete when the micrometric clamp has been moved to a position in line with the axis of the rail. Two situations are possible:

- I. The micrometric swivelling clamp has been applied in an incorrect plane. In this case correction may have produced another deformity in a plane different from that of the bone screws. Correction of this can only be achieved by substituting a multiplanar clamp for the swivelling clamp. This will normally be performed under general anesthetic.
- II. The angulator of a multiplanar clamp has not been set in exactly the correct plane. In this case there will be a residual deformity when correction is complete.

In both cases, the procedure below can then be carried out.

- I. The multiplanar clamp should be adjusted until the clamp is exactly in line with the rail.
- II. Accurately aligned new AP and lateral X-rays are taken.
- III. The residual deformity is measured carefully as described on page 5, considering both the angle and plane of the deformity.
- IV. The angulator of the multiplanar clamp is now turned to the new plane of deformity, by temporarily unlocking the two screws which control rotation (A & B in figure on page 7). Note that this can only be performed when the angulator is set at zero degrees, and the clamp is in line with the rail.
- V. Gradual correction can now be resumed by callus manipulation, according to the protocol on page 8.



The OF-Garches T-Clamp (50546) may be attached to one end of the rail to permit tibial lengthening in the proximal metaphyseal region, with good control of varus or valgus deviation. It can also be used in cases of tibia vara or tibia valga for gradual or immediate angular correction.

A Pediatric OF-Garches T-Clamp Kit is also available (55031), and is applied directly without a template.

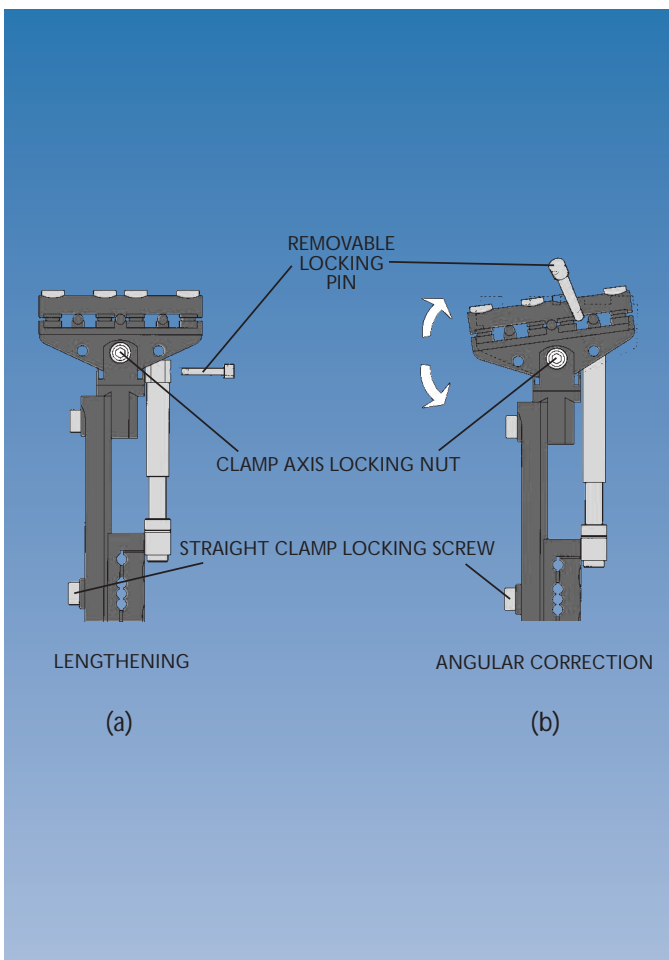
The OF-Garches T-Clamp is designed to allow angular correction in one plane only. It has swivelling screw seats to permit convergent positioning of the outer screws in the proximal tibia. It is normally placed anteriorly to adjust varus/valgus alignment, but this can be altered to allow oblique plane correction if desired. Because it is anterior, simultaneous application on both tibiae is possible. When positioned with the center of rotation of the T-clamp (A in diagram) over the center of the bone, at the same level as the proposed correction, translation does not occur during correction.

Principles of Use

The OF-Garches T-Clamp may be used for lengthening, angular correction or a combination of the two. This is governed by which locking screw is released, and the position of the compression-distraction unit. In figure (a), the fixator is configured for lengthening. The compression-distraction unit is located proximally in the base of the T-clamp and in the distal straight clamp. The clamp axis locking nut is **LOCKED**, and the straight clamp locking nut is **LOOSENED**. Extension of the compression-distraction unit lengthens the bone without any angular correction.

In figure (b), the fixator is configured for angular correction. The straight clamp locking screw is **LOCKED**, the proximal locking pin of the compression-distraction unit removed, and the proximal end rotated through 90°. It is lengthened so the seat for the locking pin is in line with the hole in the base of the T-clamp, and the locking pin inserted fully. The clamp axis locking nut is **LOOSENED**, and alteration of the length of the compression-distraction unit now changes the varus/valgus alignment of the T-clamp, without any risk of shortening a previously lengthened segment.

This clamp can therefore be used for angular correction during proximal tibial lengthening, or for the planned correction of a valgus or varus deformity of the proximal tibia. It is commonly used for the realignment of tibia vara in association with medial compartment osteoarthritis of the knee.



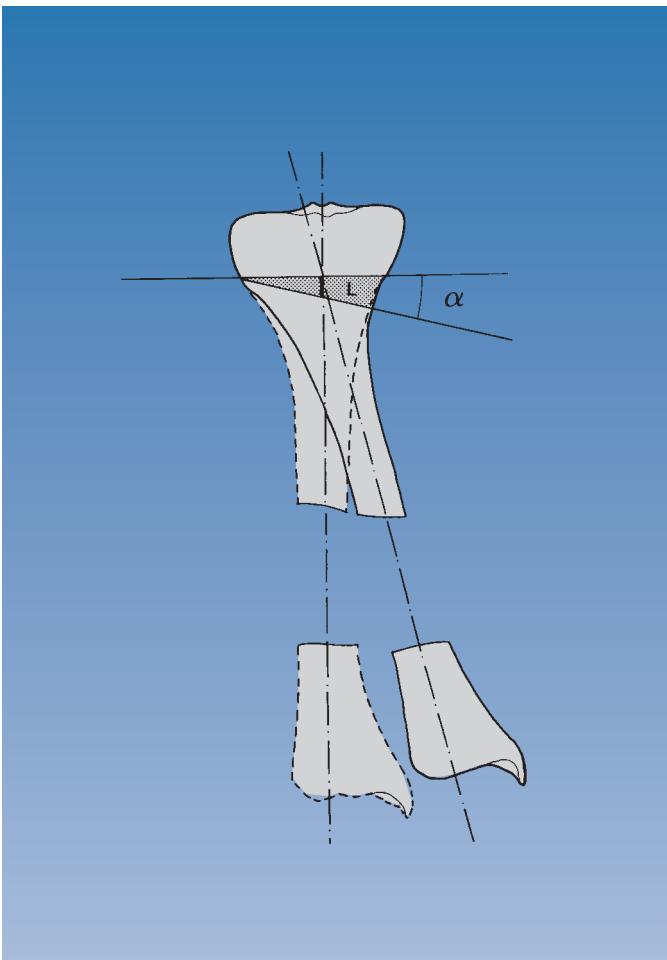
CORRECTION OF VARUS OR VALGUS DEVIATION

Gradual Correction

An angular deviation (tibia valga, tibia vara) can be gradually corrected with this module.

The application technique is essentially the same as that used for a tibial lengthening (see Manual 11, Part A: General Principles, pp. 43-45).

The surgeon should determine pre-operatively the distance L shown opposite by drawing the anatomical axis for both the deformed and the corrected tibia.

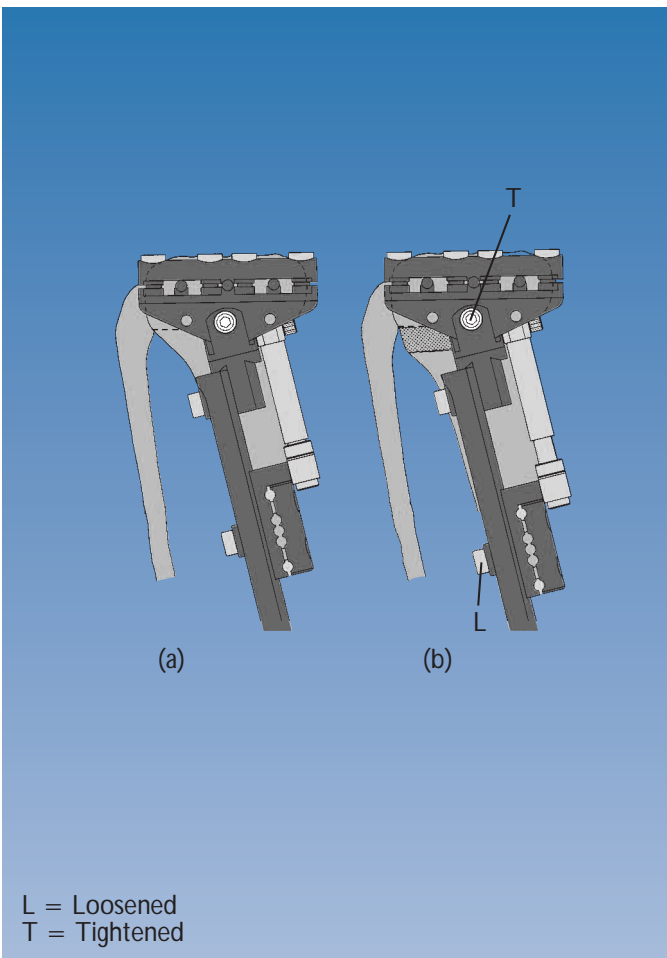


Fibular osteotomy should be performed, and a complete tibial osteotomy performed just below the insertion of the patellar tendon.

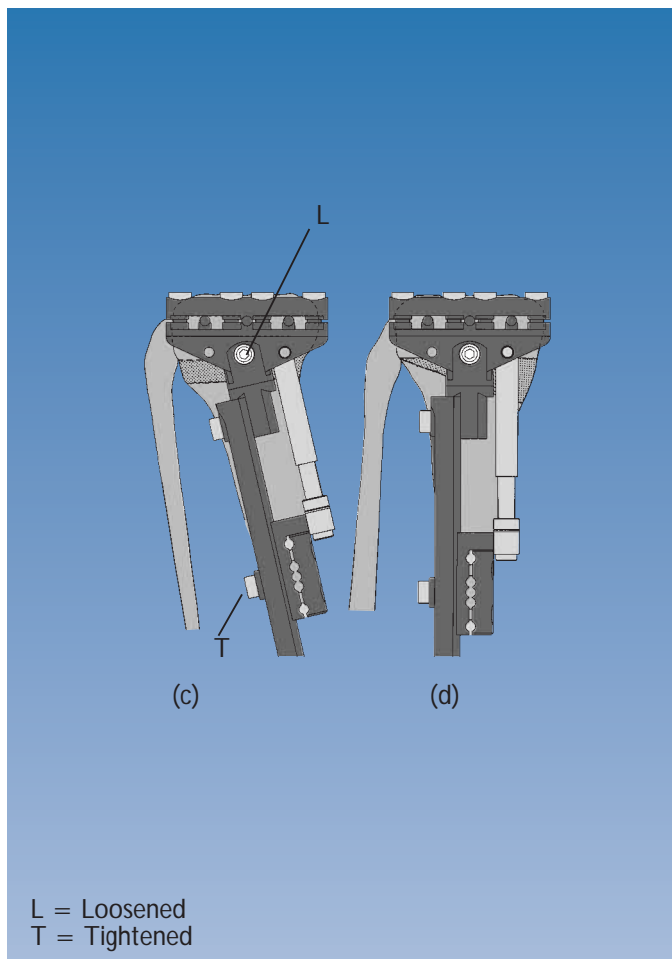
The compression-distraction unit is placed in the concavity of the deviation (a) with the removable locking pin positioned as shown in figure (a) on page 17.

The waiting period before starting distraction is normally ten days in adults, and less in children and patients with rapid ossification.

With the **clamp axis locking nut TIGHTENED** and the **straight clamp locking screw LOOSENED**, the osteotomy site is then gradually **distracted** (b) according to the principles of callotasis, to an amount equal to the distance L (see figure above).



L = Loosened
T = Tightened



Once this initial distraction has been carried out, the **straight clamp locking screw** is **TIGHTENED** and the position of the removable locking pin changed to that shown in figure (b) on page 17. The **clamp axis locking nut** is then **LOOSENED** and **distraction** carried out at a rate of 1/4 turn four times a day. Once the compression-distraction unit has **again** been extended by the distance L, the angular deformity should have been corrected (d). Once correction has been achieved, the **clamp axis locking nut** is **TIGHTENED**.

If limb length discrepancy is noted after angular correction has been achieved, this can be corrected by lengthening with the compression-distraction unit attached as shown in figure (a) on page 17, with the clamp axis locking nut **TIGHTENED**, and the straight clamp locking screw **LOOSENED**.

Immediate Correction

The application technique is essentially the same as that used for a tibial lengthening (see Manual 11, Part A: General Principles, pp. 43-45). Tibial osteotomy is performed, using a subtraction or dome technique, 1 cm below the upper screws. Fibular osteotomy is always performed.

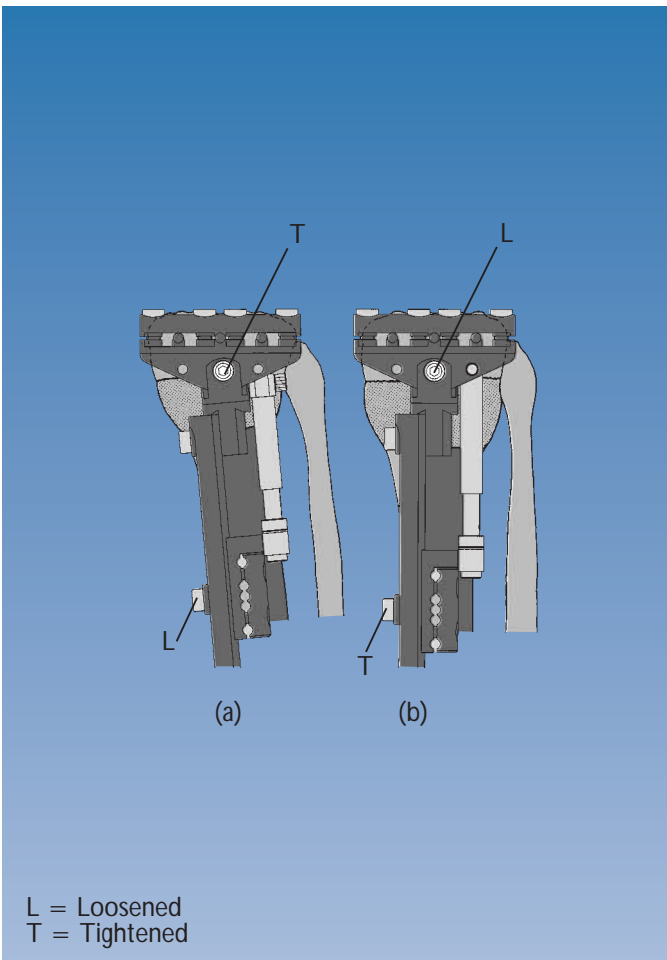
Correction is by manipulation, and the fixator is locked with the osteotomy closed. Post-operatively, partial weightbearing is permitted from the day following operation.

Optimal alignment is best judged by means of an AP X-ray of the entire lower limb with the patient standing. Any additional correction may be achieved where necessary by means of either distraction or compression using the compression-distraction unit. A lateral X-ray is also important in order to detect any interfragmentary gap, which may be corrected by means of axial compression.

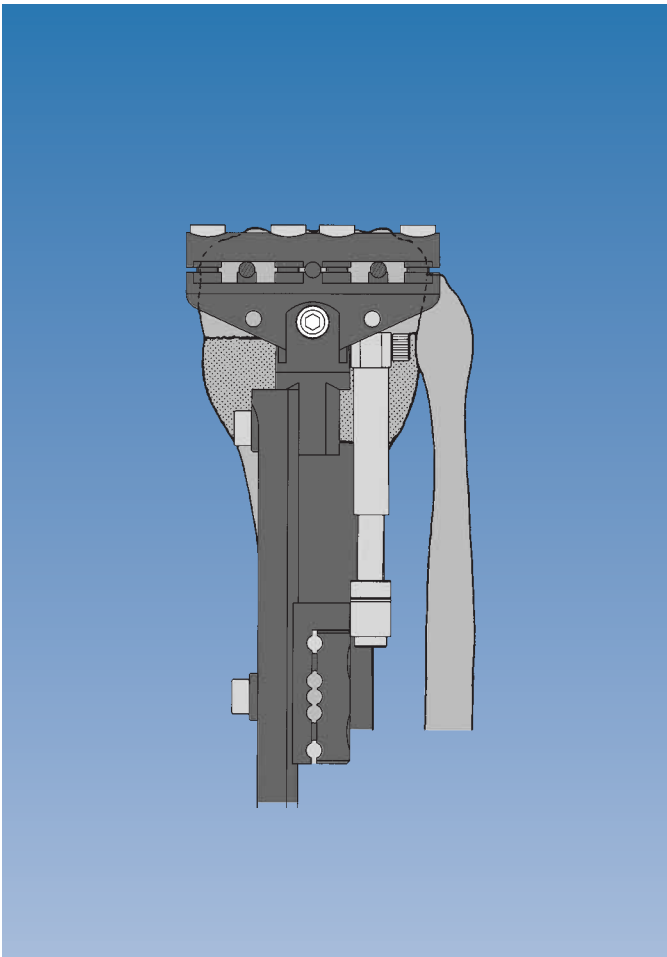
Lengthening, if required, may be carried out after the normal waiting period according to the principles of callotasis, with the compression-distraction unit positioned as shown in figure (b) on page 17.

Lengthening with Correction

The following technique may be used when there is angular deviation together with a shortening more than 2 cm. After a waiting period of 10 days, the compression-distraction unit is placed in the concavity of the deviation with the removable locking pin as shown in figure (a) on page 17 and distracted by 1-2 cm (a) at a rate of 1 mm per day (1/4 turn four times a day) with the **clamp axis locking nut TIGHTENED** and the **straight clamp locking screw LOOSENED**. After 1-2 cm of distraction, the **straight clamp locking screw is TIGHTENED**, the removable locking pin positioned as in figure (b) on page 17 (b) and the **clamp axis locking nut LOOSENED**. Correction is implemented at a rate of 1/4 turn four times per day.



When the tibia is correctly aligned, the clamp axis locking nut is tightened, and the removable locking pin positioned as shown in figure (a) on page 17. Lengthening recommences at a rate of 1 mm per day (1/4 turn four times a day).



These templates may be used to correct a deformity which consists of angulation, rotation or a combination of the two. They may be used for angular correction in the sagittal, coronal or oblique planes and for derotation. The extent to which a deformity may be safely corrected acutely depends on the site and the effect the correction has on local soft tissue tension.

General Principles

These templates are designed to permit accurate screw placement in each segment of a bone on either side of the apex of a deformity. The bone screws are inserted perpendicular to the anatomical axes of the relevant bone segment. An osteotomy is carried out at the apex of the deformity. The templates are then removed, and the limb manipulated so that the two sets of bone screws can be seated into standard LRS clamps. This produces the required correction.

Preoperative planning will determine whether a deformity may be resolved by a correction at one site (monofocal) or two (bifocal). Additionally, each site may have only one parameter for correction, e.g. rotation (and is classified as simple), or it may require the correction of several parameters, e.g. angulation, rotation and length (and is therefore classified as complex). In a complex monofocal deformity, both angulation and rotation may be corrected acutely and simultaneously; length can then be restored gradually in accordance with the principles of lengthening through callotasis.


Caution with Acute Correction

Generally, acute correction is only carried out if the parameters of a deformity are all less than 20°. For larger deformities, gradual correction is more appropriate. Soft tissue considerations are important, particularly with regard to the peroneal nerve in the proximal tibia. Prior mobilization of the nerve may be necessary. Distal tibial corrections are less liable to cause problems, but care should be taken to ensure that the peroneal nerve is not stretched. Gradual correction with a circular or monolateral frame may be a safer procedure. In the femur there are no such neurovascular constraints to acute correction. However, correction of rotational deformities in the distal femur will have an effect on the tracking of the patella. If the patella tracking is correct, it is safer to make a rotational correction in the proximal femur. If patellar tracking is incorrect, because of a rotational malunion, correction distally may be preferable to realign the patella mechanism at the same time.

Each template can be used with either the adult or pediatric limb reconstruction systems. Careful pre-operative planning is necessary to achieve a good result, with accurate X-rays, as described on pp. 3-4.

Angulation Templates

Angular correction is performed by means of the angulation templates, which are attached to the end of the Limb Reconstruction System rail, and are of three types, corresponding to the straight clamp, the T-clamp, and the T-Garches clamp. Note that there are two hinges, one designed to alter alignment in the coronal plane, and the other in the sagittal plane. The antero-posterior (sagittal plane) and medio-lateral (coronal plane) deformities are measured from appropriate radiographs with a goniometer. An LRS rail is assembled with an angulation template attached at one end. The locking screws for the two hinges of the angulation template are loosened, and the template adjusted in each plane to match the deformities measured on the antero-posterior and lateral X-rays. The hinge locking screws are tightened. The assembly is now aligned to mimic the deformity in the bone. These templates may be used in combination with a straight template clamp mounted on the rail, or with the rotational template clamp, if this deformity is also present.




Rotational Templates

A rotational deformity can be corrected by inserting pairs of bone screws at a defined angle to each other in the transverse plane. After an osteotomy has been performed between the pairs of bone screws, they can be brought into the same plane, and held in a pair of straight clamps while the bone heals. This can be done as an isolated procedure, or in combination with an angulation template for the correction of a combined angular and rotational deformity. It is also possible, if necessary, to combine this acute correction with later lengthening. The rotational templates allow the surgeon to place the pairs of bone screws at a precise angle to each other to allow accurate correction of the deformity, which is measured clinically or by CT scan.

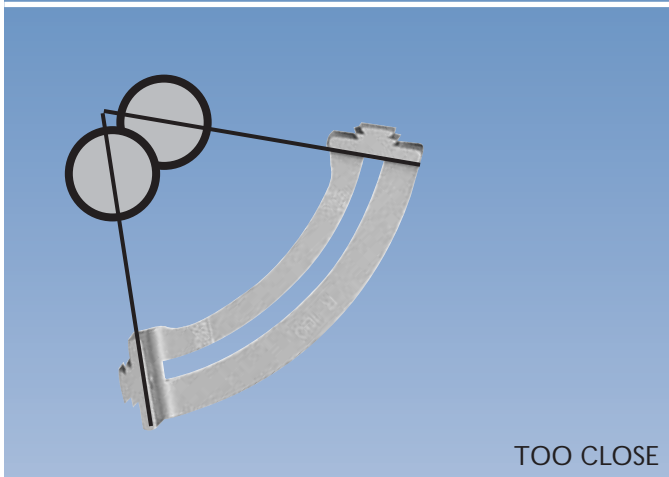
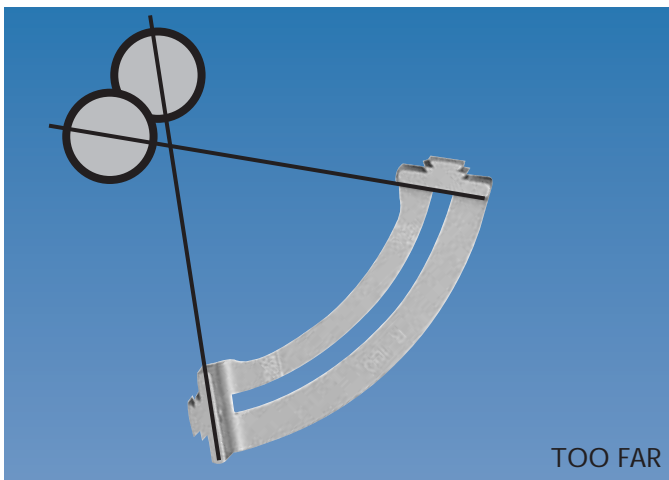
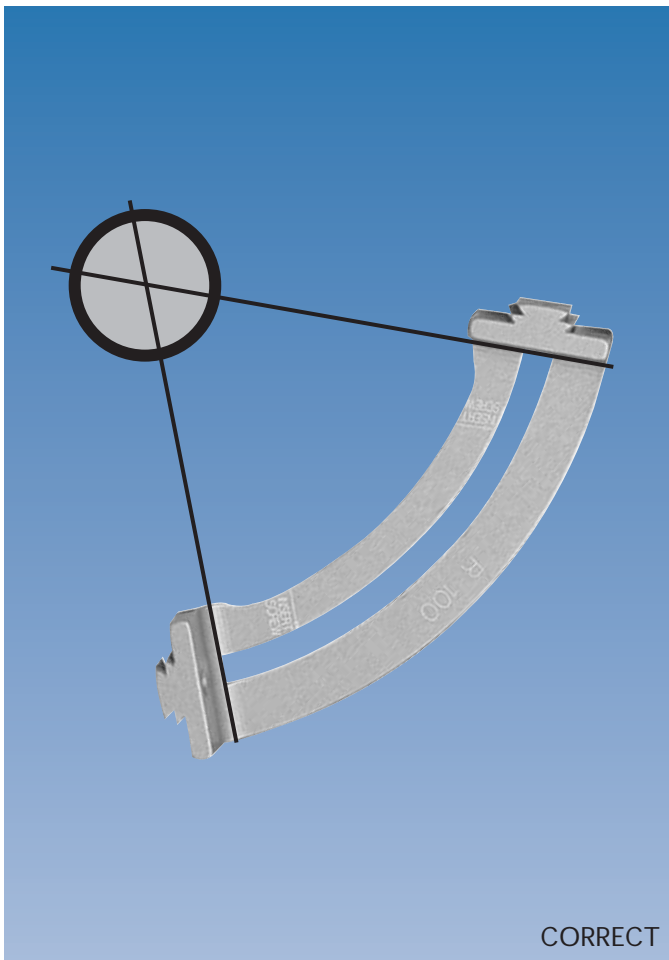
The template consists of two components:

1. An arc, of which there are three sizes, with radii of 60 mm, 100 mm and 130 mm, to accommodate soft tissues of varying bulk; the arcs are designed with flange attachments at each end which allow use with the adult or pediatric LRS rails, and are free to slide along the length of the rail. They should be placed so that they curve towards the limb.
2. A template clamp, which can be slid round the arc to a defined number of degrees of correction. The maximum amount of correction possible is 39° with the 60 mm arc, 47° with the 100 mm arc and 50° with the 130 mm arc.




Choosing the Correct Arc Size

The rotational template allows the surgeon to insert screws into a bone at a pre-determined angle from those inserted via a standard template. However, the screws must be inserted correctly, so that they pass through the center of the bone. To achieve this, the LRS rail must be at a distance from the center of the bone equal to the radius of arc chosen.




If the distance between rail and bone is not equal to the radius of arc selected, there may be some translation between the two bone segments after correction. There are two ways to calculate this distance:


- I. Most plain X-rays will allow direct measurement from the center of the bone to the surface of the skin on the side to which the LRS is to be applied. 40 mm is added to this measurement, to allow for the distance from the rail to skin. This figure will indicate which arc radius to select. The nearest size is selected, altering the distance between the rail and skin to achieve a close match.
- II. During surgery a K-wire of known length is passed perpendicularly from the rail to the bone. The length of wire between the surface of bone and the center of the rail is noted. To this is added an estimate of the radius of bone: this figure will indicate which arc radius to choose. Again the nearest size is selected, altering the distance between the rail and skin to achieve a close match.



(a)



(b)




25°

Rotational Template Assembly

The arc can be attached and slid into any position on the rail, but must be positioned with the arc curving towards the patient. It is important that the template clamp is attached to the arc in the correct manner. Note that the template clamp has six threaded holes on the larger end. These are in two groups of three to allow left or right attachment of the three sizes of arc. The template is assembled as follows:

1. The correct size of arc is chosen, and attached and locked to the rail so that it curves towards the patient. The template clamp is placed flat on the rail on the side away from the flanges on the arc, with the peg engaging in the slot on the arc (see figure (a) and (b)).
2. The locking screw is inserted into the screw hole labelled with the correct radius for the arc being used, and tightened. It should be confirmed that the template clamp is lying flat on the rail when this screw is tightened (b). In the example illustrated, the 130 mm arc is shown, so the template is locked to the arc through the upper hole, labelled 130 (see figure on page 22).
3. The locking screw is now loosened enough to allow the template clamp to rotate round the arc to the correct position for screw insertion. The base of the main part of the clamp body should be opposite the chosen degree mark on the arc, in this case 25°.

Note: If it is fixed to the arc with the incorrect screw hole, the template clamp will be tilted relative to the rail when it is in the zero position, and correct screw insertion will not be possible without removing the clamp from the rail.



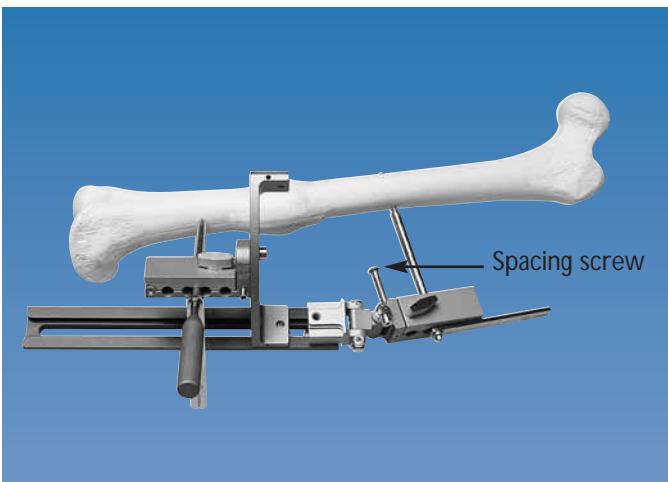
Example Application Showing Use of Angulation and Rotational Templates

In the example below a 20° varus and a 25° internal rotation deformity in the midshaft of the left femur will be corrected acutely, using both the angulation and rotational templates. However, for an isolated angular or rotational deformity, either can be used alone with the technique described below, combined with a standard clamp template on the rail. The antero-posterior (sagittal plane) and medio-lateral (coronal plane) deformities are measured from appropriate radiographs with a goniometer. Rotational deformity is assessed clinically and, where required, by CAT scan. A detailed pre-operative plan is made, as described on pp. 3-4.


In this case the proximal angulation template has been adjusted to reflect the varus deformity, and the hinge locking screws tightened. The distal clamp is mounted on an appropriate arc to reflect the rotational deformity.



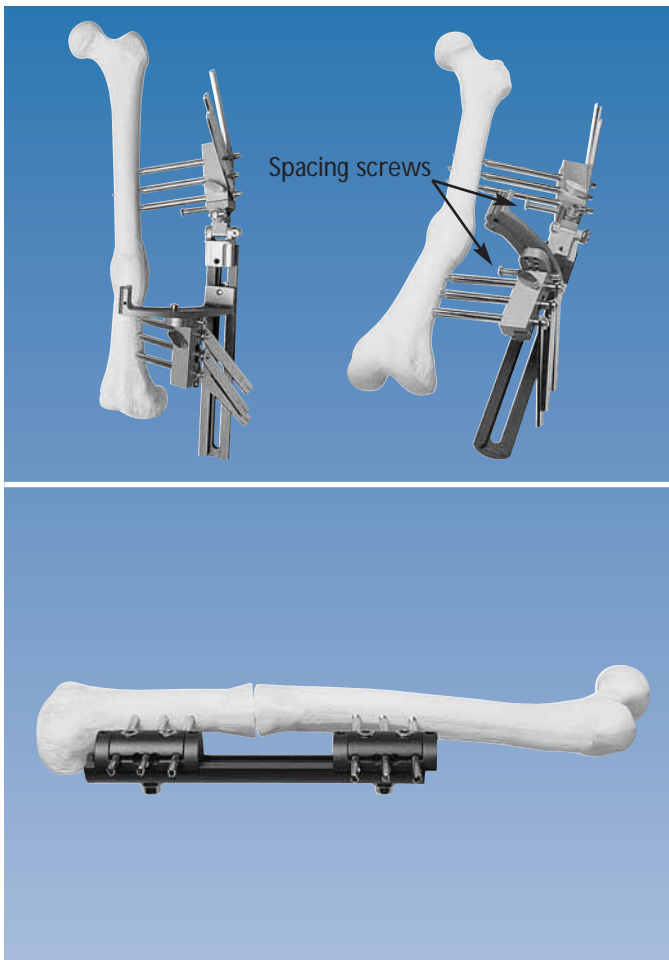
With a skin pen, the level of the apex of the deformity and the prospective sites for screw insertion are marked out. The hinge of the angulation template should be positioned opposite the deformity; the position of the arc on the rail is adjusted to ensure an appropriate distance between the apex of the deformity and the two clamps. A straight trocar is used, with a screw guide, to confirm that each set of bone screws will be at 90° to the corresponding bone segment. The screws must be placed in such a way that after the correction has been achieved they lie parallel in two planes ready for attachment to the rail using two straight clamps. Screw insertion positions may be referenced to the axis of each segment, or a joint plane. The limb is now positioned with the patella facing anteriorly. The rail with templates attached is placed so that the hinge in the angulation template is opposite the apex of the deformed bone. A screw is inserted at right angles to the axis of the proximal femoral segment, just proximal to this apex. The rail is held 3-4 cm from the skin, and the spacing screws in both clamp templates advanced until they touch the skin. The distance between the rail and the center of the bone is now checked, as described in figure here below, and confirmed to be equal to the radius of the arc. **It is important that this is checked at this time; later correction will not be possible.**



A trocar is now inserted down to the distal segment through a screw guide in the clamp template mounted on the arc. If the template has been set up correctly, the trocar will point towards the center of the bone, perpendicular to the axis of the distal femur. If it is not at 90° to the axis of the distal segment or does not point to the center of the bone, then the settings of the angulation template and the distance of the rail from the bone should be reviewed. Note that if the distance between the rail and the bone has changed or is not correct, the second screw will not pass through the center of the bone. If the rail is too close, it will be anterior, or posterior if the rail is too far away. Care should be taken to ensure that it is inserted across the center of the bone. An eccentrically placed screw will result in translation when the definitive fixator is applied, and may weaken the bone.



The spacing screws (shown here and on page 26) are adjusted so that the rounded ends are in contact with the skin and maintain the correct skin-fixator distance. Once it is confirmed that the trocar is in the correct position, the second screw is inserted.



With the rail and templates thus held in a fixed relation to the limb, screws are inserted in the remaining seats of each template clamp (1 and 5 seats in children and smaller adults, 1, 3 and 5 seats in larger adults).

The osteotomy is now performed at the apex of the deformity, as described previously for callotasis. The template is removed, and the limb manipulated so that the two pairs of bone screws are now parallel. The LRS rail is now reapplied with standard straight clamps, and the clamp locking screws tightened so that the rail is at the same distance from the skin. The Image Intensifier is used to check that there is no gap or translation at the osteotomy, and the clamps are locked into position. At the end of the procedure the Bovie (diathermy) cord is placed over the limb between the center of the femoral head and the mid-point of the ankle joint to confirm the correction. Correction of the deformity may have caused some skin tethering by the bone screws. This should be corrected by release incisions as necessary. If required, lengthening can be performed at the osteotomy site after the usual resting period.

Post-Operative Management

The clamps should both be locked firmly to the rail for the initial post-operative period, to provide stability. As soon as practical, careful assessment of limb length should be undertaken. If any lengthening is required, this should be initiated after the appropriate waiting period according to the age and general health of the patient, as described under "Segmental Transport" in Manual 11, Part A: General Principles, page 29. In the example above, the angular deformity was in the diaphysis. If additional length is required, this may be better achieved with a proximal metaphyseal osteotomy, and a third proximal straight clamp, because better callus is formed after a metaphyseal osteotomy. The pin sites should not be a problem, provided that skin tethering has been avoided, and the usual careful skin care carried out. For a prolonged procedure, often associated with lengthening, the use of hydroxyapatite coated screws is recommended.

Bone transport and allied techniques are complex and require a high degree of cooperation. In particular, it is difficult, in some cases, to control the degree of mobilization, since some children are very active and others find it difficult to use mobilization aids such as crutches and walking frames.

The parents and child should be counselled as much as possible pre-operatively. As a general rule, even in ideal circumstances, it is better to avoid operating on children under the age of five. The procedures are similar to those described above.

Screw Size

As a general rule, if the hole to be drilled is less than 30% of the diameter of the bone, adult size bone screws should be used where possible, as the strength of the bone will not be significantly affected, provided that the screw hole is drilled in the center of the bone. The use of screws with smaller threads, diameter 4.5-3.5 mm, should be reserved for young children with small bones. The choice of screw size should be made according to the size of the child and the bone to be treated, and cannot be determined by age.

EXTERNAL FIXATION

- PM 010 ORTHOFIX EXTERNAL FIXATION:
BASIC CONSIDERATIONS
- PM 020 GROWTH PLATE DISTRACTION
 - Chondrodiatasis
 - Hemichondrodiatasis
- PM 030 LIMB LENGTHENING AND CORRECTION
OF DEFORMITIES BY CALLUS DISTRACTION
 - Callotasis
 - Hemicallotasis
 - Tibial lengthening and angular correction
with the OF-Garches limb lengthener
- PM 040 ARTHRODIATASIS
(Articulated Joint Distraction)
 - Hip
 - Ankle
- PM 050 ARTHRODESIS (Joint Fusion)
 - Shoulder
 - Hip
 - Knee
 - Ankle
- PM 060 DIAPHYSEAL FRACTURES
 - Humerus
 - Forearm
 - Femur
 - Tibia
- PM 070 DISTAL TIBIAL AND PILON FRACTURES
- PM 080 PELVIC APPLICATIONS
- PM 090 TREATMENT OF FRACTURES AND
DEFORMITIES IN SMALL BONES
- PM 100 THE PENNIG DYNAMIC WRIST FIXATOR
- PM 110 THE LIMB RECONSTRUCTION SYSTEM
 - Part A: General Principles
 - Part B: Correction of Deformities
- PM 120 THE RING FIXATION SYSTEM
 - Part A: The Hybrid Fixator
 - Part B: The Sheffield Ring Fixator -
Standard Trauma Applications
 - Part C: The Sheffield Ring Fixator -
Limb Reconstruction and Complex Trauma

INTERNAL FIXATION

- PM IKD Intramedullary Skeletal Kinetic Distractor:
Tibial Surgical Technique
- Intramedullary Skeletal Kinetic Distractor:
Femoral Surgical Technique
- PM IMT The Orthofix Tibial Nailing System
- PM IMF The Orthofix Femoral Nailing System
- PM AAN The Ankle Arthrodesis Nail
- PM RFN The Retrograde Femoral Nailing System
- PM PRD PORD™ DEVICE
Posterior Reduction Device for Hip and Femoral
Fractures
- PM PCP THE GOTFRIED PC.C.P
for Percutaneous Compression Plating
of Pertrochanteric Hip Fractures
- PM HUN THE ORTHOFIX HUMERAL NAILING SYS-
TEM

Orthofix Srl
wishes to thank:

Dr. S: NAYAGAM B.Sc., Mch, FRCS

Consultant in Orthopaedic and Trauma Surgery,
Royal Liverpool Children's
and Royal Liverpool University Hospitals,
Liverpool, United Kingdom

**for his invaluable help
in the preparation of this manual.**

Orthofix Srl
also wishes to thank:

Dr. R.W. BRIGHT, MD

Orthopaedic Associates
Glen Burnie, MD - USA

Prof. M. SALEH, MSc, FRCS

Department of Orthopaedic Surgery
University of Sheffield - UK

**for their contribution to the design and refinement
of the equipment described.**

Manufactured by: ORTHOFIX Srl
Via Delle Nazioni 9
37012 Bussolengo (Verona)
Italy

Telephone +39-0456719000
Fax +39-0456719380



Your Distributor is:

Deformity Correction | Trauma | Pediatrics | Bone Growth Stimulation