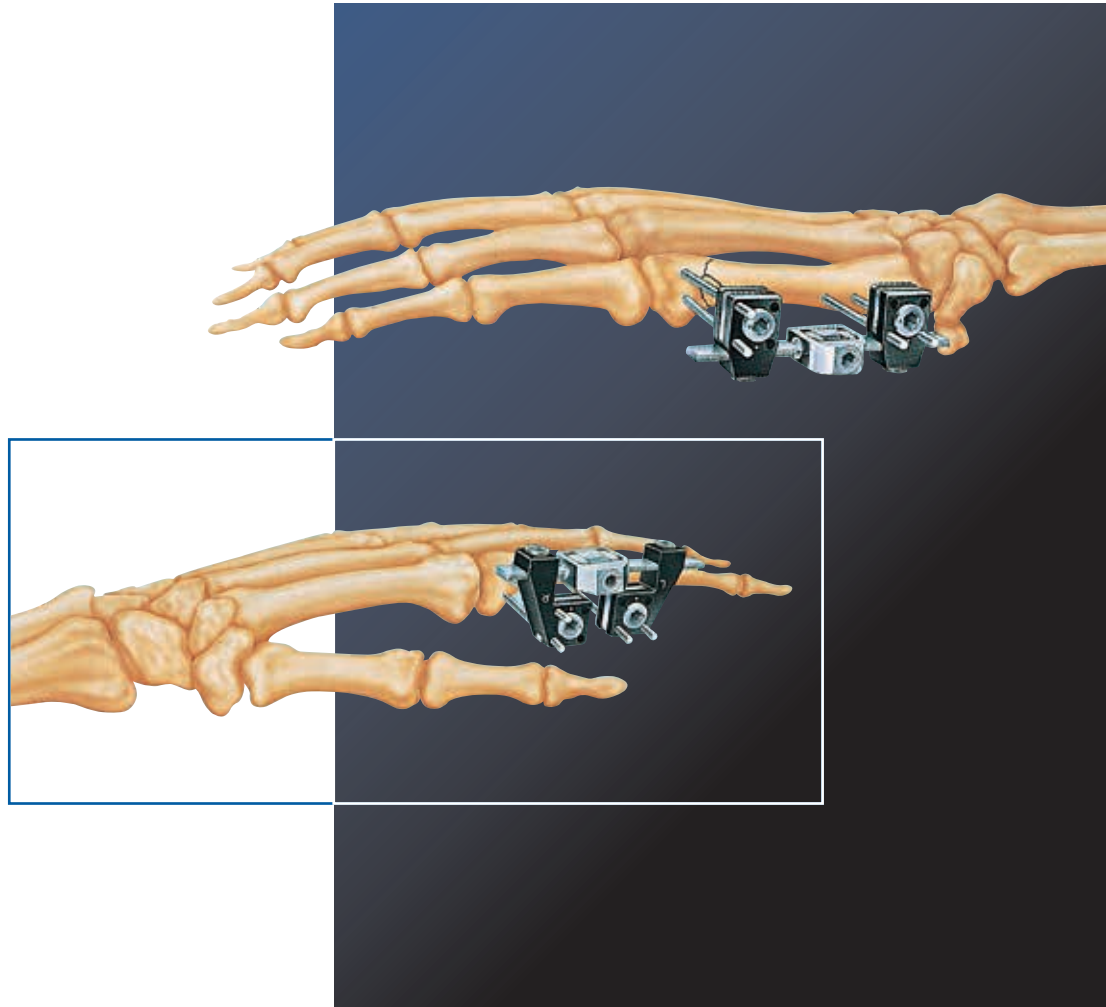

# Treatment of Fractures and Deformities in Small Bones

The Pennig Minifixator

By Prof. Dr. D. Pennig

<b>INTRODUCTION</b> .....	1
Bibliography.....	1
<b>EQUIPMENT REQUIRED</b> .....	2
<b>MAINTENANCE OF ORTHOFIX EQUIPMENT</b> .....	2
<b>CLEANING AND STERILIZATION</b> .....	2
<b>DESCRIPTION OF COMPONENTS</b> .....	3
<b>OPERATIVE TECHNIQUE</b>	
<b>METACARPAL FRACTURES</b> .....	6
Shaft Fractures of the Fifth Metacarpal.....	6
The First Threaded Wire.....	6
The First Clamp.....	6
The Second Threaded Wire.....	7
Fixator Selection and Application.....	8
The Threaded Wires of the Second Clamp.....	9
Locking of the Cams and one Clamp.....	9
Reduction.....	10
Final Locking.....	10
Sub-capital Fractures of the Fifth Metacarpal.....	11
The First Threaded Wire.....	11
Completion of the Application.....	12
Shaft Fractures of the First Metacarpal.....	12
Fractures at the Base of the First Metacarpal.....	13
The Threaded Wires of the First Clamp.....	13
Fixator Application.....	13
The Threaded Wires of the Second Clamp.....	14
Special Considerations in other Metacarpal Applications.....	14
<b>PHALANGEAL FRACTURES</b> .....	15
Fractures of the Proximal Phalanx of the Index Finger.....	15
The First Threaded Wire.....	15
The First Clamp.....	16
The Second Threaded Wire.....	16
Fixator Application.....	17
Completion of the Application.....	17
<b>METATARSAL FRACTURES</b> .....	18
<b>SPECIAL INDICATIONS</b> .....	19
Aseptic or Infected Non-unions.....	19
Corrective Osteotomy.....	20
Lengthening and Bone Transport.....	21
Replantation Surgery.....	22
Soft Tissue Correction and Arthrodiatasis (Articulated Distraction).....	22
<b>CONTRAINDICATIONS</b> .....	22
<b>POST-OPERATIVE MANAGEMENT</b> .....	23

Where open reduction and internal fixation is used in metacarpal or phalangeal fractures of the hand, the margin of error in an anatomically difficult area is very small. If conservative treatment is used, however, joints and dynamic structures in the hand are immobilized, possibly to their detriment, and even so, reduction may not be successfully maintained.

External fixation with the Pennig Minifixator, combines the advantage of secure fragment fixation with a minimally invasive procedure. Soft tissue dissection is not necessary, since in general, indirect reduction is employed.

Until now, external fixation in the hand has required bridging of the joint in more than 40% of cases (Asche and Burny) because of the design of the fixator clamp. The Pennig Minifixator allows for the placement of threaded wires parallel to the joint surface and thus requires only minimal space for its application. Inventory is reduced, since the threaded wires do not need predrilling and are trimmed to length.

With this system, the traditional three "R's" of fracture treatment: Reduction, Retention and Rehabilitation are accomplished with a highly favorable risk/benefit ratio for both patient and surgeon.

Indications for its use in the hand and foot include:

- FRACTURES
- ASEPTIC AND INFECTED NON-UNIONS
- CORRECTIVE OSTEOTOMY
- LENGTHENING
- REPLANTATION
- SOFT TISSUE CORRECTION

## BIBLIOGRAPHY

ASCHE G., BURNY F. - Indikation für die Anwendung des Minifixateur externe, eine statistische Analyse. Aktuelle Traumatologie, (1982), 12: 103-110.

ASCHE G. - Stabilisierungsmöglichkeit einer intraartikulären Trümmerfraktur des I. Mittelhandknochens mit dem Minifixateur externe. Handchirurgie, (1981), 13: 247-249.

BARTON N.J. - Fractures of the hand. J. Bone Joint Surg., (1984), 66-B: 159-167.

DOBYNS J.H., LINSCHIED R.L., COONEY W.P. III - Fractures and dislocation of the wrist and hand, then and now. J. Hand Surg., (1983), 8: 687-690.

HEIM V., PFEIFFER K.M. - Small fragment set manual. 1st and 2nd eds. (1974, 1982), Berlin, Heidelberg, New York; Springer-Verlag.

JAMES J.I.P. - Fractures of the proximal and middle phalanges of the fingers. Acta Orthop. Scand., (1962), 32: 401-412.

PENNIG D., GAUSEPOHL T., LUKOSCH R. - The multidirectional minifixator. In: Cziffer E (Ed.). Minifixation. External Fixation of small bones. Literatura Medica, Budapest 1994; 27-32.


PENNIG D., GAUSEPOHL T., LUKOSCH R. - Externe Fixation zur Unterstützung der Weichteilrekonstruktion in der Handchirurgie. Handchir. Mikrochir. Plast. Chir. 1995; 27: 264-268.

PENNIG D., GAUSEPOHL T., MADER K., WULKE A. - The use of minimally invasive fixation in fractures of the hand - The Minifixator concept. Injury, 2000; 31 Suppl. 1: 102-112.

PENNIG D., GAUSEPOHL T. - Metacarpal Fractures, Phalangeal Fractures and Reconstructive Procedures: The Pennig Minifixator in the Hand. In: Orthofix External Fixation in Trauma and Orthopaedics. G. De Bastiani, A.G. Apley, A. Goldberg (Eds), Springer, 2000: 195-218.

SEGMÜLLER G. - Surgical Stabilization of the Skeleton of the Hand (1977). Williams and Wilkins, Baltimore.

## EQUIPMENT REQUIRED



### Orthofix Equipment

The equipment available includes the following items, not all of which will be needed on every occasion:

- |   |   |
|---|---|
| a) Short PMF body (M402)                                | h) L-clamps (M410, left and right)        |
| b) Standard PMF body (M403)                             | i) 2.0mm threaded wires (M426, pack of 4) |
| c) Long PMF body (M404)                                 | j) 1.6mm threaded wires (M420, pack of 4) |
| d) Short lengthening bar complete with spacer (M415)    | k) Compression-distraction nuts (M412)    |
| e) Standard lengthening bar complete with spacer (M416) | l) Two 3.0mm Allen wrenches (10012)       |
| f) Long lengthening bar complete with spacer (M417)     | m) Threaded wire extractor (M442)         |
| g) Standard clamps (M411, pack of 2)                    | n) Reduction forceps (M441, set of 2)     |

One Allen wrench and the wire extractor are included for outpatient removal of the Minifixator.

### General Equipment

The general equipment required comprises an air drill with reverse, a wire cutter and other equipment which might be necessary in certain situations. The Minifixator should be applied under Image Intensifier control.

## MAINTENANCE OF ORTHOFIX EQUIPMENT


All the equipment should be checked before use: the appropriate number of threaded wires should be inserted into the clamps, and the cams on the clamps tightened with the 3mm Allen wrench. **If the dot on the cam moves more than 170 degrees, the clamp should be replaced.**

Both the locking of the clamp on the bar and the locking of the double ball-joint should also be checked before use.

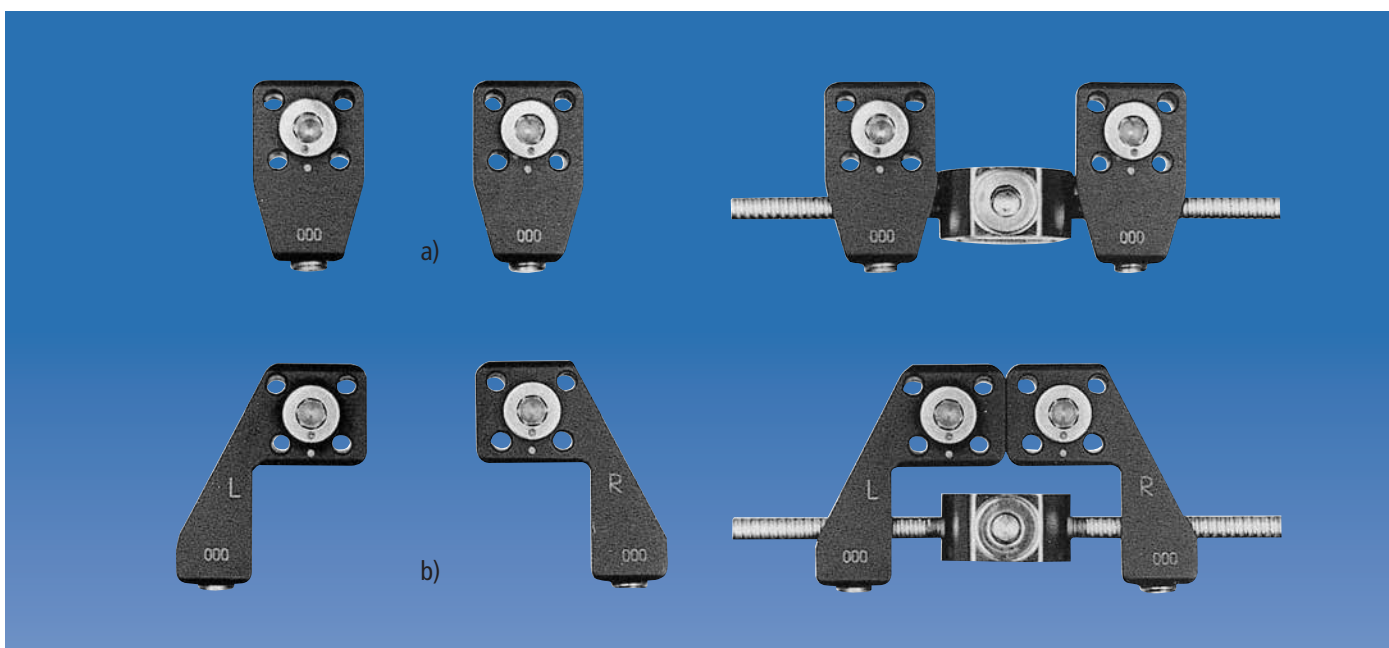
**THREADED WIRES SHOULD NEVER BE RE-USED.**

## CLEANING AND STERILIZATION

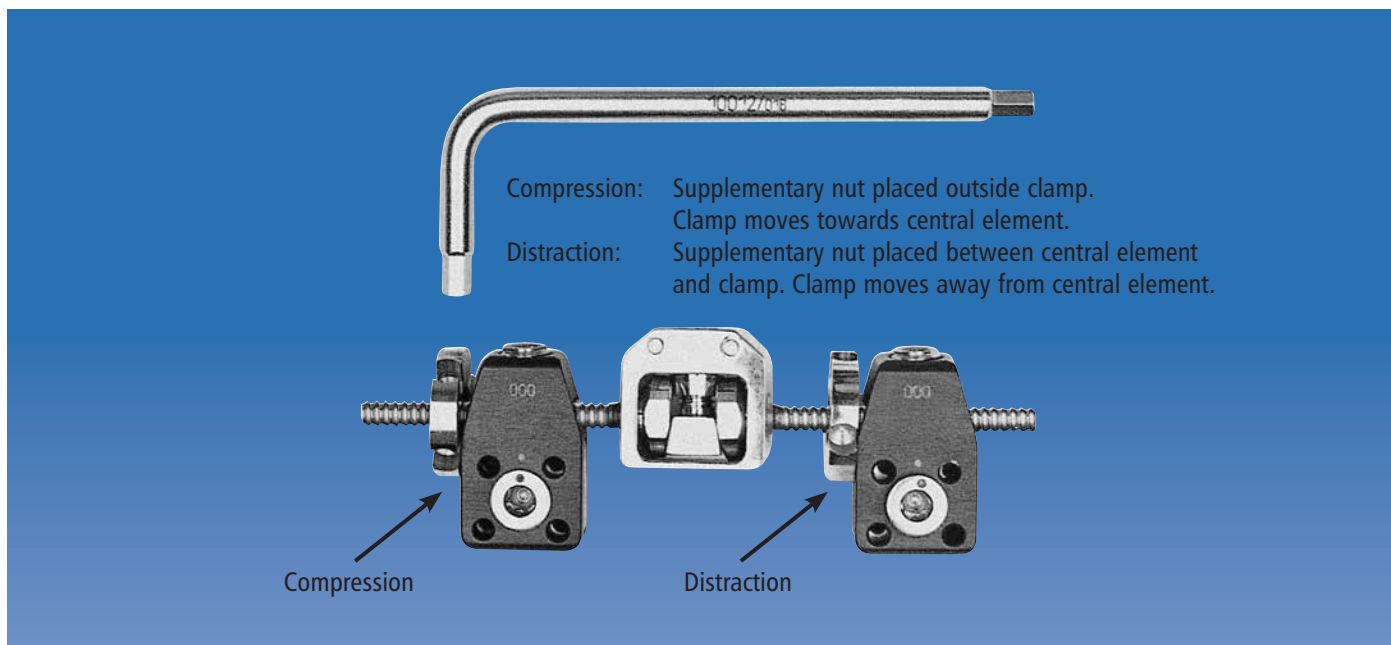
When products are used for the first time, they should be removed from their containers and properly cleaned using medical grade alcohol 70% + distilled water 30%. After cleaning, the devices should be rinsed with sterile distilled water and dried using clean non-woven fabric. Prior to surgical use, the fixator, as well as the threaded wires and instrumentation should be cleaned as described above and sterilized by steam autoclaving following a validated sterilization procedure, utilizing a prevacuum cycle (Orthofix recommends the following cycle: steam autoclave 132°-135°C [270°-275°F], minimum holding time 10 minutes). After every use, the clamps should be removed from the bars and all locking screws and cams loosened prior to cleaning and sterilization.




The central element of the Pennig Minifixator is a double ball-joint with a single screw locking mechanism embedded in a module 15.5x15mm square. The central element connects two threaded bars to constitute short (a) (bars 28.1mm and 18.1mm), standard (b) (both bars 28.1mm) and long (c) (bars 28.1mm and 43.1mm) Minifixators.




The threaded bars are attached in turn to the clamp modules, of which there are two types: a standard clamp (a) and an L-clamp (b). The L-clamp is designed to be used when the distance between the bone fixation points is very small. Two L-clamps facing one another, as shown above, will permit the insertion of two pairs of wires as little as 6mm apart. In view of this, and because the hexagonal locking screw must always face the surgeon, the L-clamp is available in two models, left (L) and right (R). The standard clamp is normally used for metacarpal or metatarsal bones, and the L-clamp for the phalanges.




Compression and distraction are possible using supplementary nuts in association with the threaded bars to move the clamps in the desired direction. The nuts are turned using the 3mm Allen wrench and one full turn of the nut through 360 degrees will compress or distract respectively, by one millimeter. The nuts are not generally used in association with fresh fractures.



The clamp modules can each accommodate threaded wires in four different positions. Two wires are sufficient in most circumstances. The wires are specifically designed for use with the Minifixator to ensure good bone purchase. **Standard Kirschner wires are inadequate for the purpose and should not be used.** The threaded wires are supplied in two combinations of thread diameter and total length: 2.0mm thread diameter and 100mm long (a), or 1.6mm thread diameter and 70mm long (b). In both sizes the threaded portion is 15mm long and the diameter of the unthreaded portion is 2.0mm. The wires are trimmed to length following insertion, increasing the versatility of the system and reducing the inventory required.



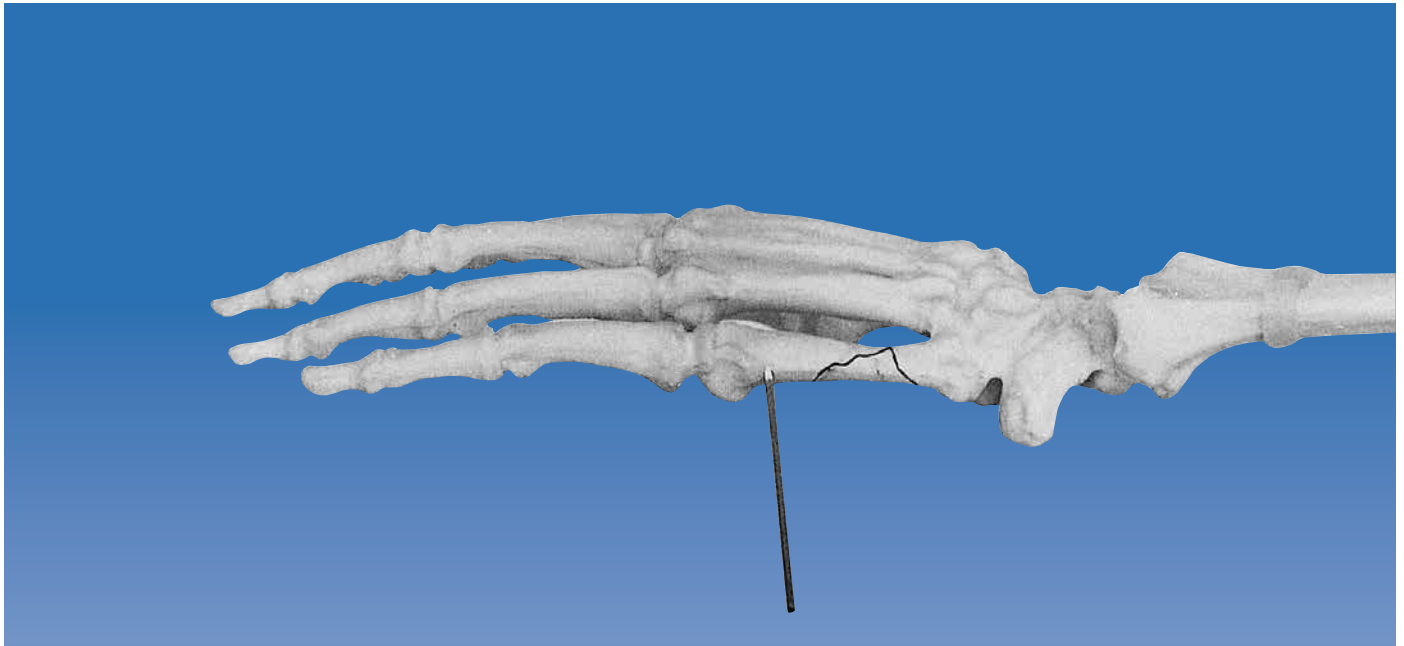Before the threaded wires are inserted into the clamp, the dot on the surface of the cam must be aligned with the white dot on the surface of the clamp. This opens up the holes in the clamp, allowing easy passage of the wires. When the wires are inserted into the clamps in a plane along the axis of the bone (a), they emerge parallel; when they are inserted in a plane at right angles to the diaphyseal axis (b), they converge. This is particularly useful when it is necessary to insert wires close to the joint, or into very small fragments. Note: Once converging wires have been inserted, the clamps can no longer slide on the wires. It is therefore important to determine the desired angle of wire convergence and the final distance of the fixator from the skin before inserting the second wire. The wires are locked into the clamp by tightening the cam. **When wires are inserted into the bone**, the clamp will always be stable provided the cam is securely tightened. Reduction can be carried out with the fixator in situ, using the manipulation forceps, and the maintenance of reduction is facilitated by the small number of locking screws requiring only one size of Allen wrench.



For lengthening or bone transport, the ball-jointed PMF body should be replaced by a lengthening bar. These are supplied in three sizes: (a) short (80mm); (b) standard (100mm) and (c) long (120mm), and are used in association with either standard or L-clamps, and 2mm wires. A third wire may be added in each clamp to improve stability especially in osteoporotic bone and in the metatarsals. The lengthening bars are available complete with spacers, which should be placed with the angled side in contact with the standard clamp and the flat side in contact with the compression-distraction nut (see inset). In this way, complete surface contact between the nut and the standard clamp is ensured during distraction. When distraction is performed using an L-clamp, there is no need for the spacer (see inset).

## METACARPAL FRACTURES

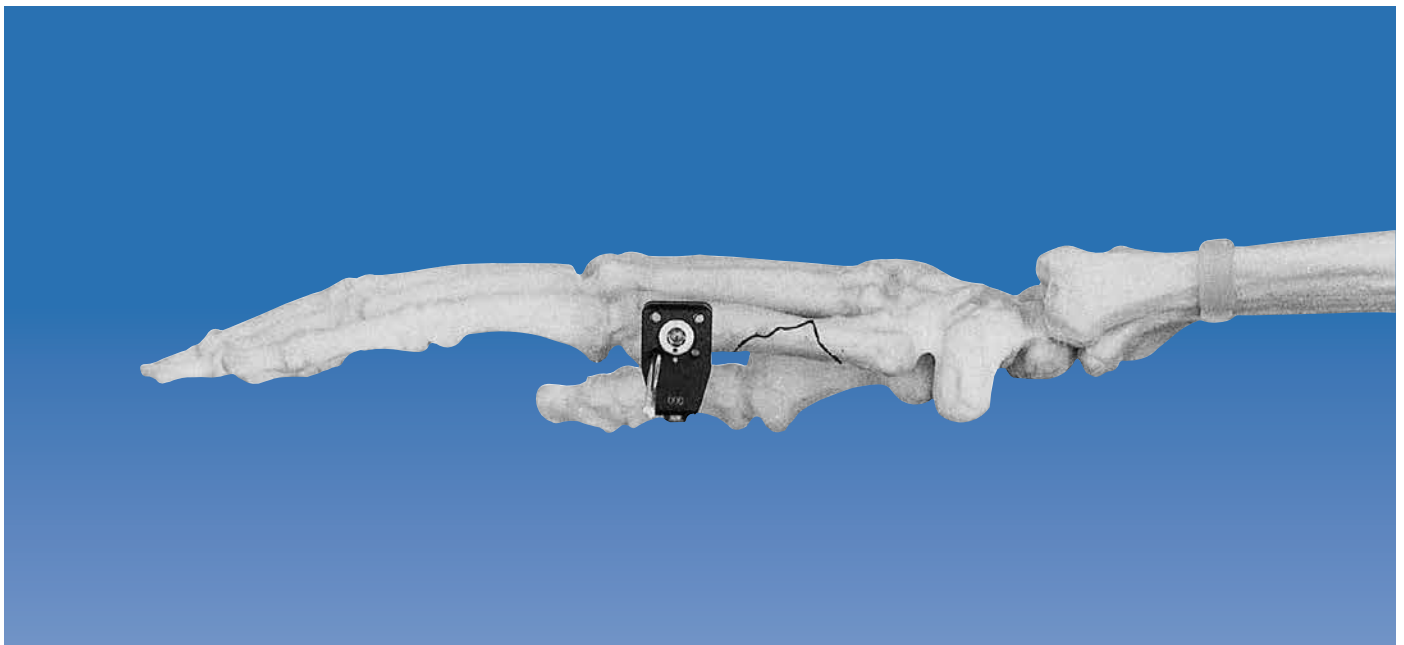
### Shaft Fractures of the Fifth Metacarpal



For metacarpals, the 2mm threaded wires (100/15) are used. A decision must be made, based on the X-rays, as to whether the wires can be inserted in an axial plane (i.e. parallel wire placement) or whether they will need to be introduced in a plane transverse to the bone axis (i.e. convergent wire placement). If there is one small fragment, convergent placement of the wires in this fragment is advisable. The minimum distance between a wire and the fracture should not be less than 3mm.

#### The First Threaded Wire

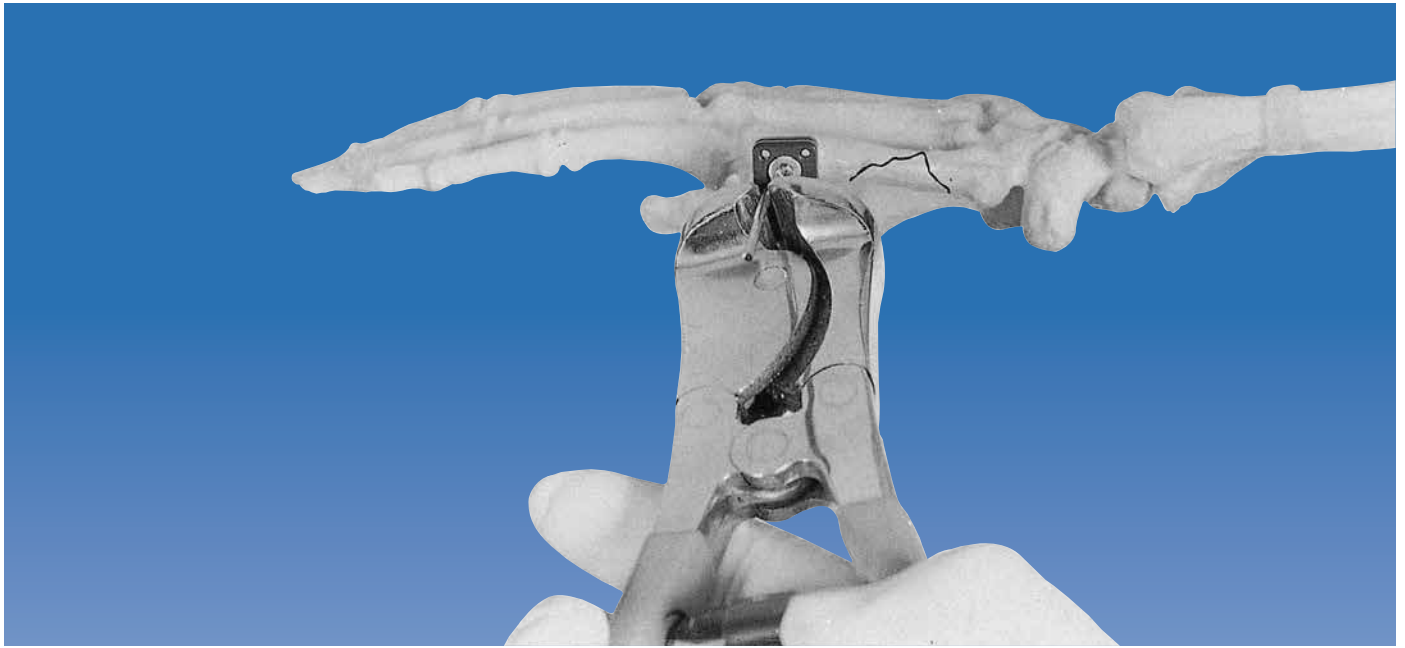The first wire to be inserted is the one closest to the joint. It is introduced in the frontal plane using power instrumentation and, since its thread is not conical, it can be backed out if it has been advanced too far. With all applications of the Minifixator, the wires should just penetrate the far cortex, protruding no more than one millimeter beyond it, to avoid damage to adjacent structures. This should be confirmed using image intensification.



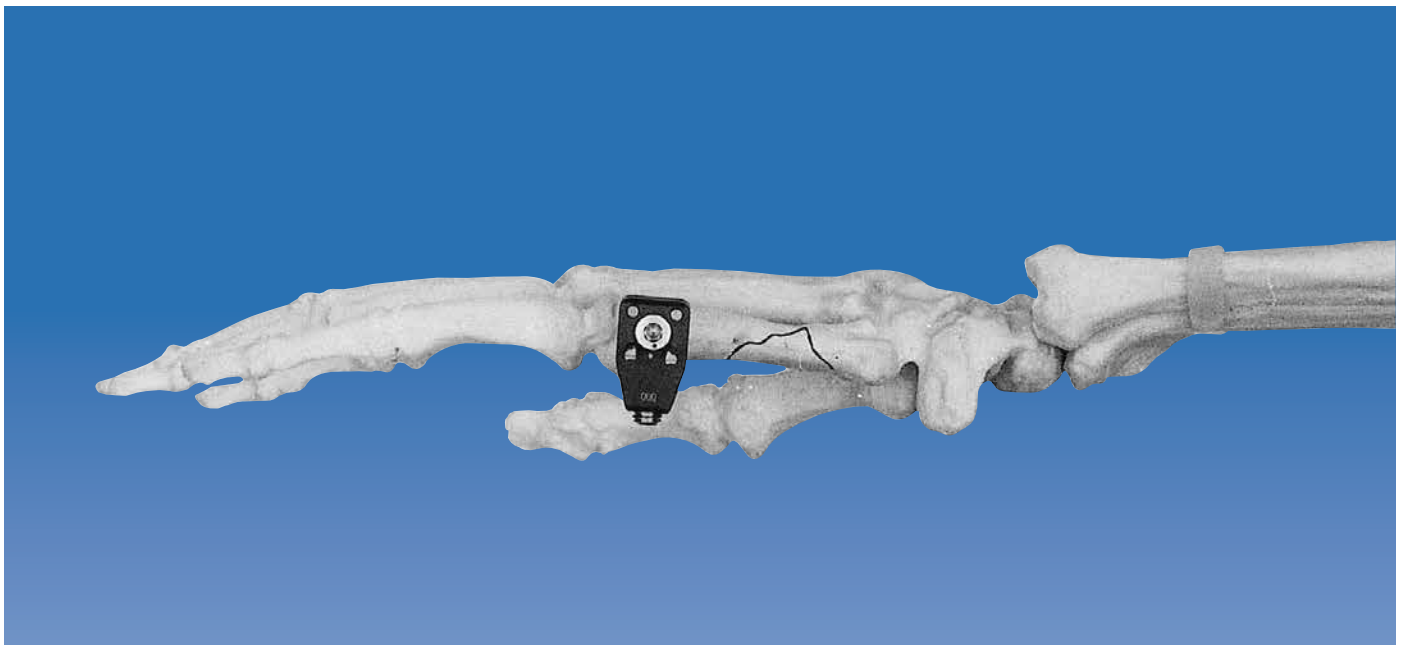
#### The First Clamp

A standard clamp is applied over the wire, ensuring that the dot on the surface of the cam is in line with the dot on the clamp surface. The clamp must always be positioned so that the head of the cam faces away from the bone, to allow for subsequent tightening of the cam.






As a general rule, the clamp should be positioned about 5-10mm from the skin, to allow for some post-operative swelling. The first wire is then trimmed so that about 5mm project beyond its margin. It should be noted that each wire must be trimmed after insertion, to avoid obstructing the drill during insertion of the next wire.



### The Second Threaded Wire

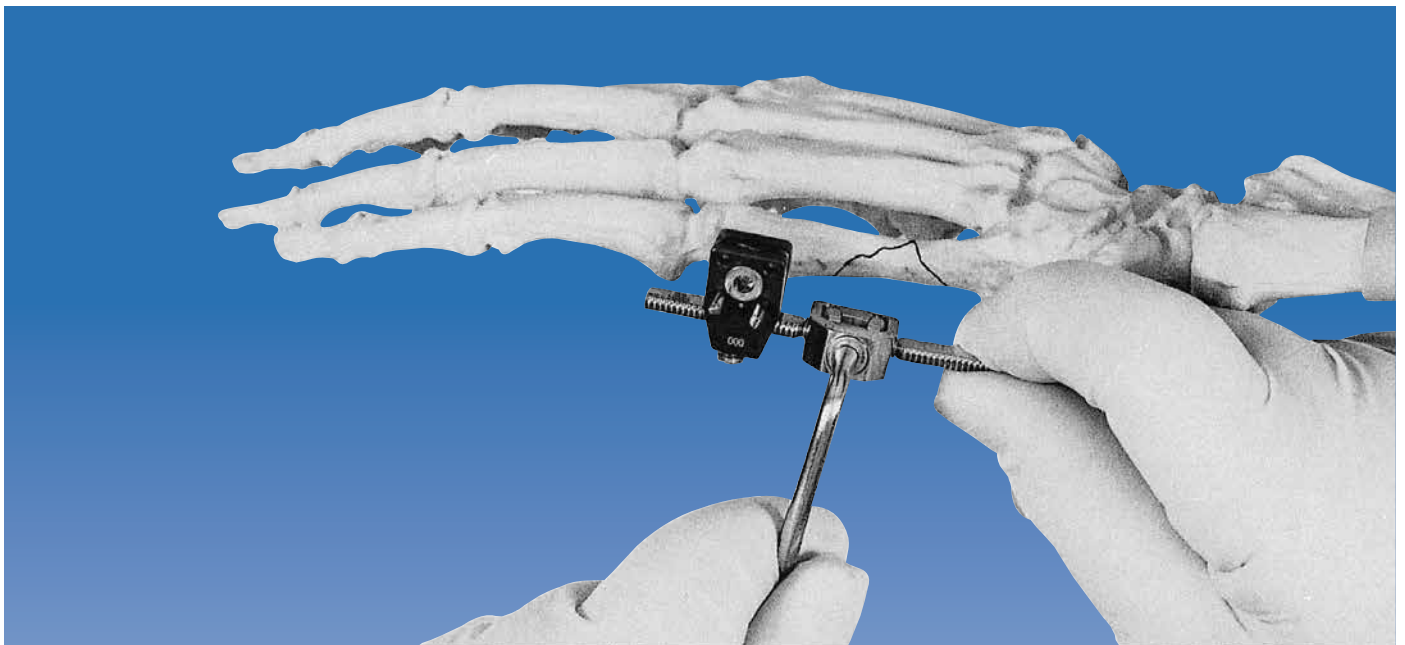
The second wire is inserted either parallel or convergent with respect to the first, according to the length of the fragment. When inserted in a transverse plane the wires converge, so that they can be inserted into very small fragments. The second wire is now inserted under image intensification, and trimmed to length.

Note: Some surgeons prefer to place an Allen wrench in the cam during wire insertion to prevent vibration and subsequent movement of the cam away from the dot on the clamp surface.

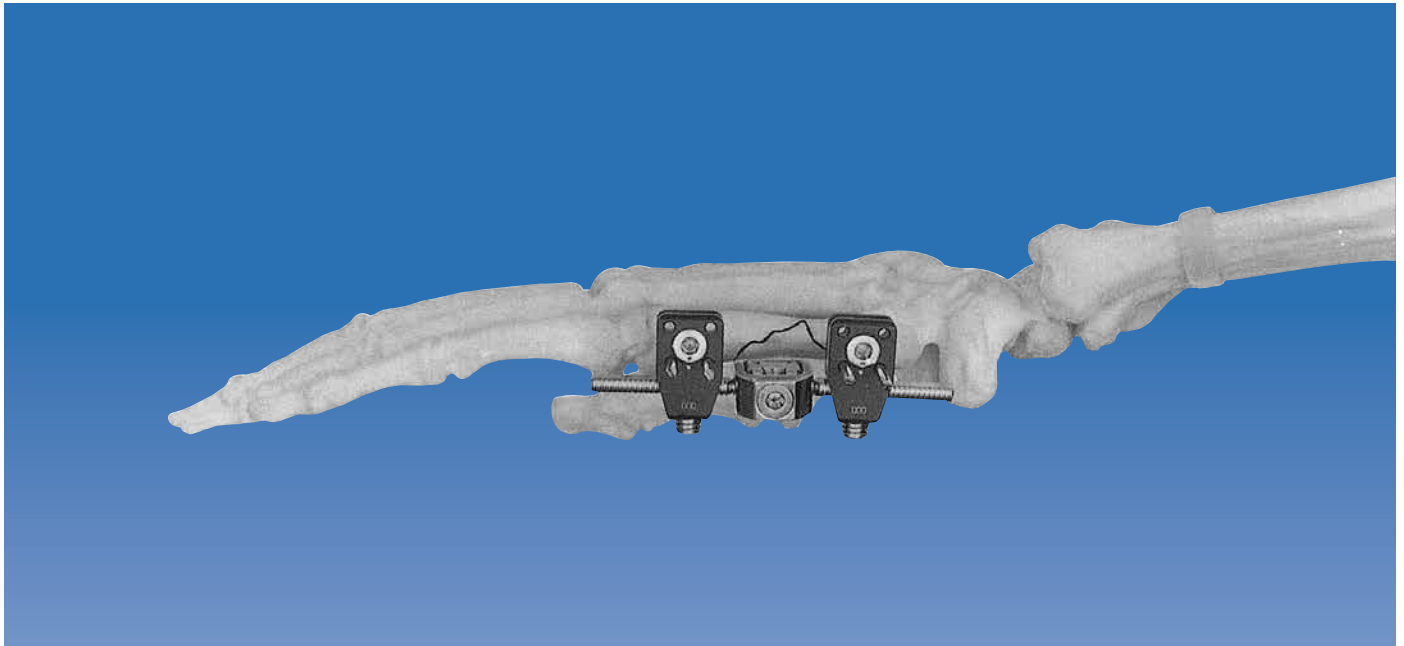


### Fixator Selection and Application

Depending upon the dimensions of the bone and the site of the fracture, a short, standard or occasionally, a long Minifixator body is selected. One threaded bar is attached to the clamp holding the two wires.

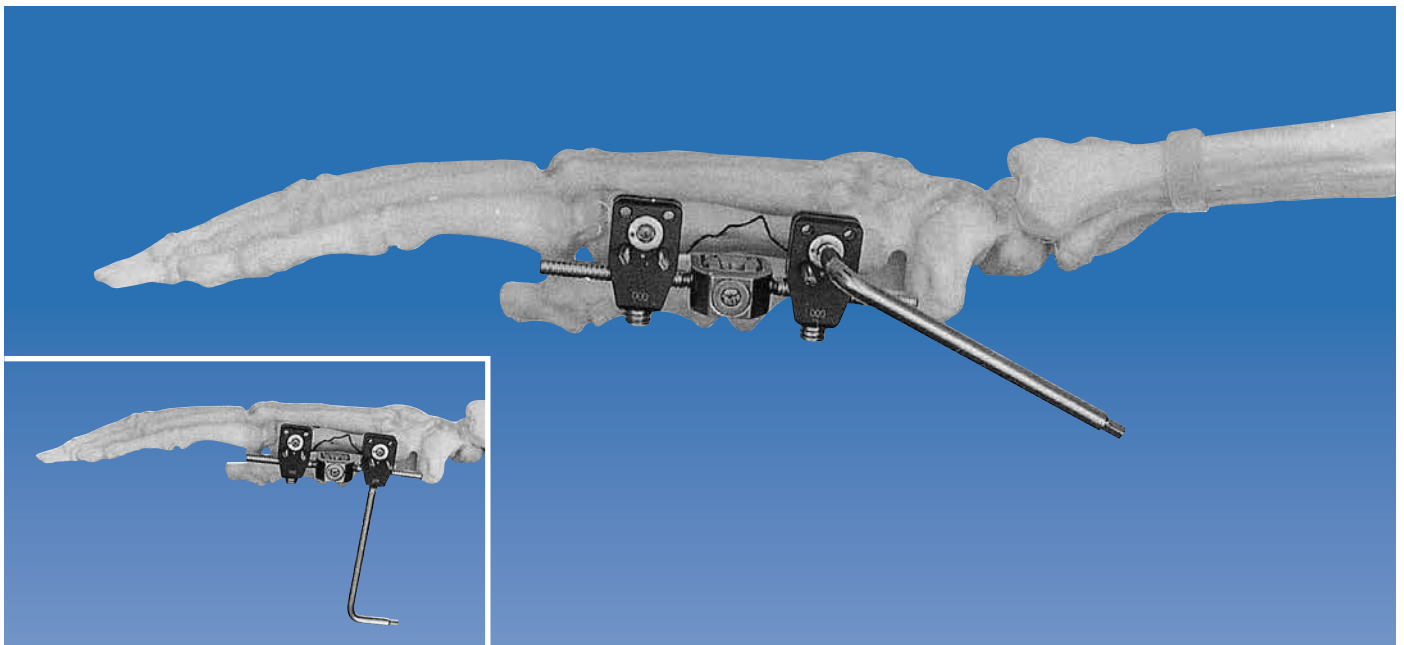


The double ball-joint locking cam is then turned clockwise a little, so that ball-joint movement becomes slightly stiff. The long axis of the fixator can now be aligned with the long axis of the metacarpal, which should be reduced clinically. The second clamp is now attached to the other threaded bar.



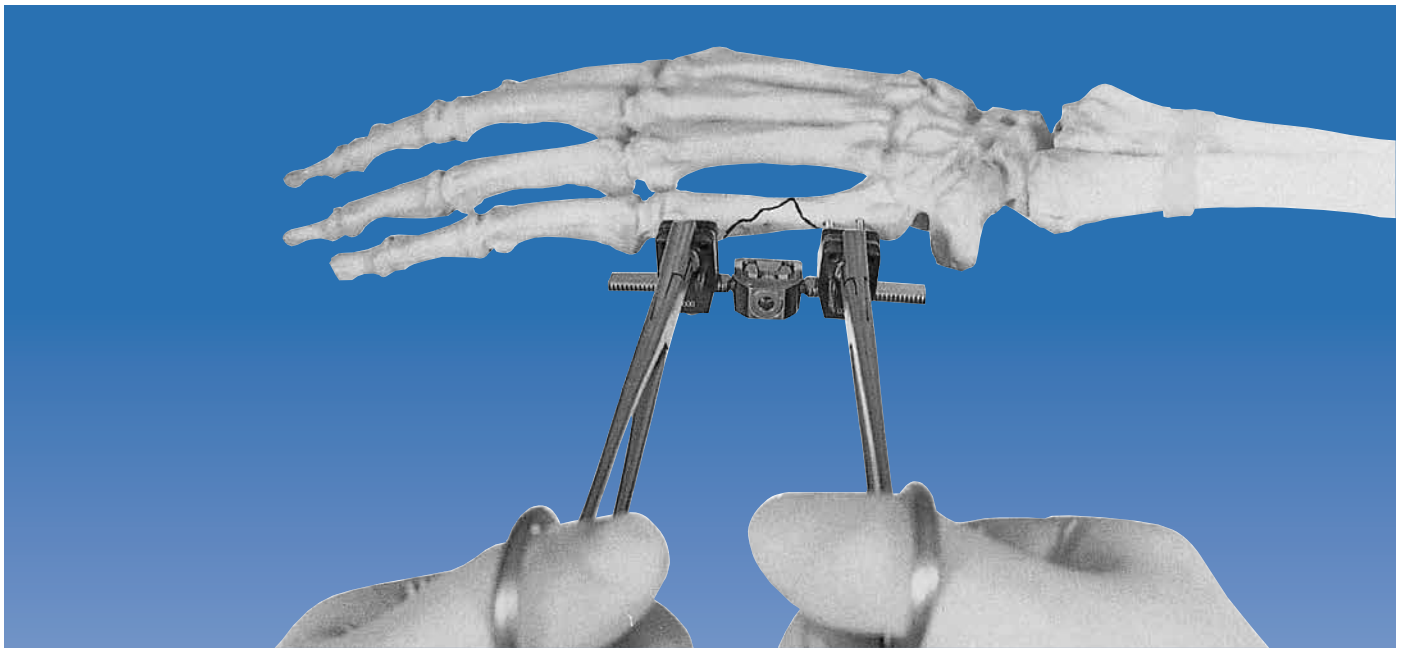
### The Threaded Wires of the Second Clamp

The second set of wires is now inserted, usually longitudinal (i.e. parallel wire placement) to, but occasionally at right angles (i.e. convergent wire placement) to the diaphyseal axis. When choosing the position for these wires, care should be taken to ensure that the clamps have sufficient room on their respective bars to allow for final reduction. This again is monitored in both planes using the Image Intensifier.



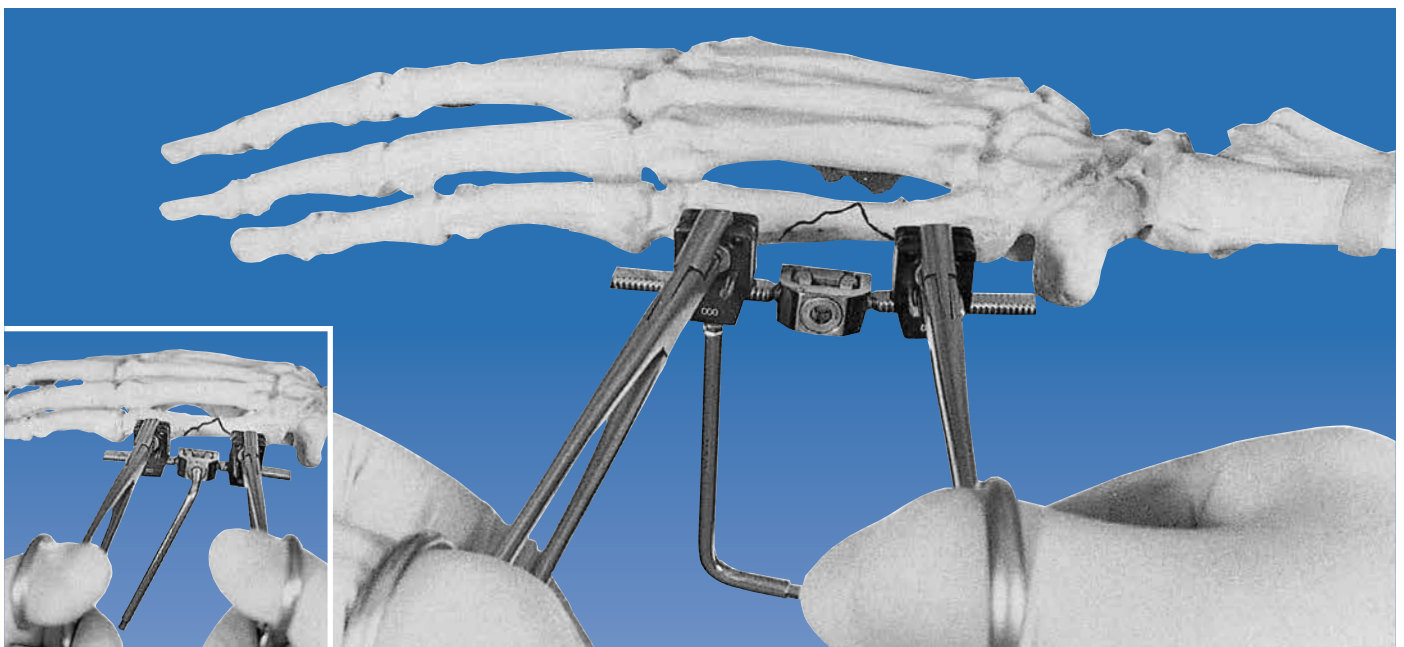
### Locking of the Cams and one Clamp

Once all the wires have been inserted, the clamps are locked to them, by turning the cam on each firmly. Before final reduction, one of the clamps can be locked to its bar with the clamp locking screw, checking that the other clamp has room to move along its bar during the reduction procedure.



**Reduction**

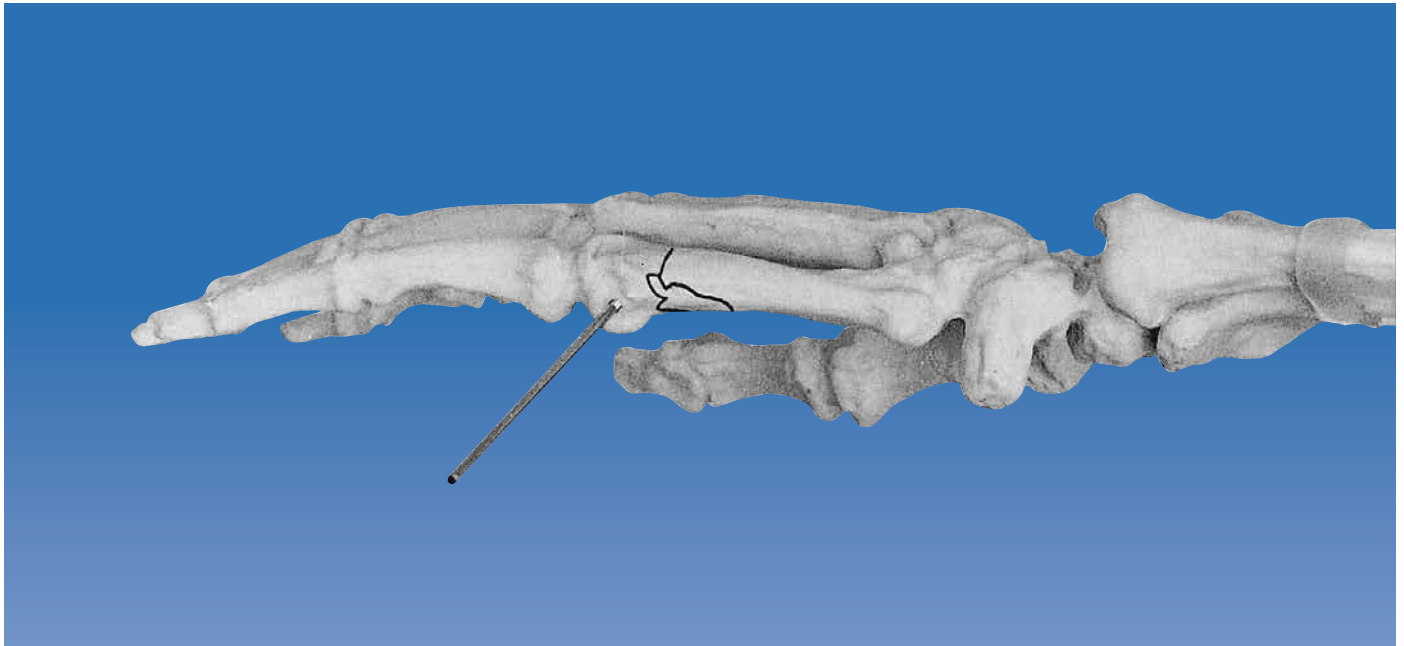
The fracture is now reduced using traction and counter-traction, taking particular care to avoid any rotational deformities, and bearing in mind that in flexion, all fingers converge on the topographic location of the scaphoid. The reduction forceps are provided to distance the surgeon's hands from the radiation source. For additional protection, radiation gloves are available, and may be worn for this manoeuvre. The forceps grip the clamps to permit manipulation and, after reduction, tightening of the necessary screws without loss of position.



**Final Locking**

While the reduction is held as shown above, the second clamp is locked to the bar, maintaining the length of the bone. Following this, the double ball-joint of the Minifixator body is locked to control angulation, by turning the cam in the center of the Minifixator body clockwise. At the end of the operation, a check should be made to ensure that sufficient space has been left between the skin and the fixator (minimum 5mm). The wires are finally trimmed such that 2mm of wire protrudes from each clamp. This helps to prevent the sharp ends of the wires catching in the patient's clothes. A dressing is applied in such a way that the Minifixator is fully covered. No circumferential dressing is necessary. The patient is encouraged to move fingers and adjacent joints from the day of operation. It is not possible, however, for the patient to carry out heavy work at this stage.

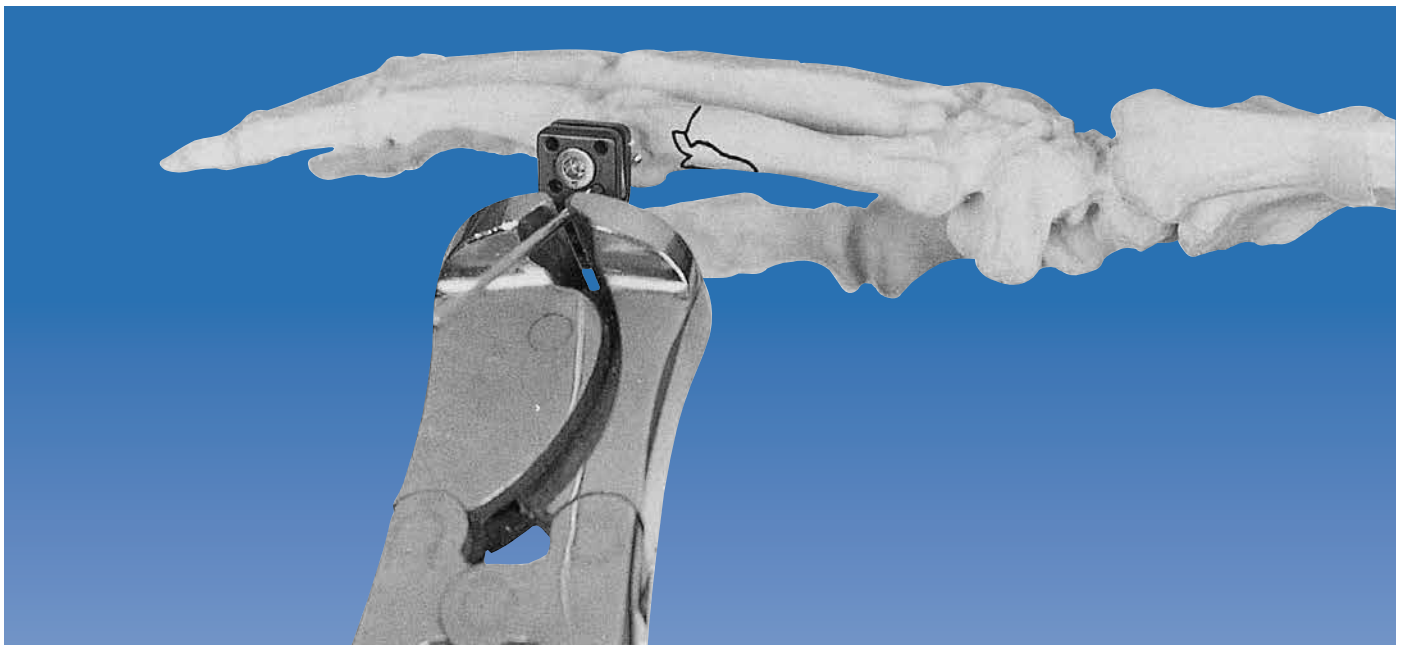
Sub-capital Fractures of the Fifth Metacarpal



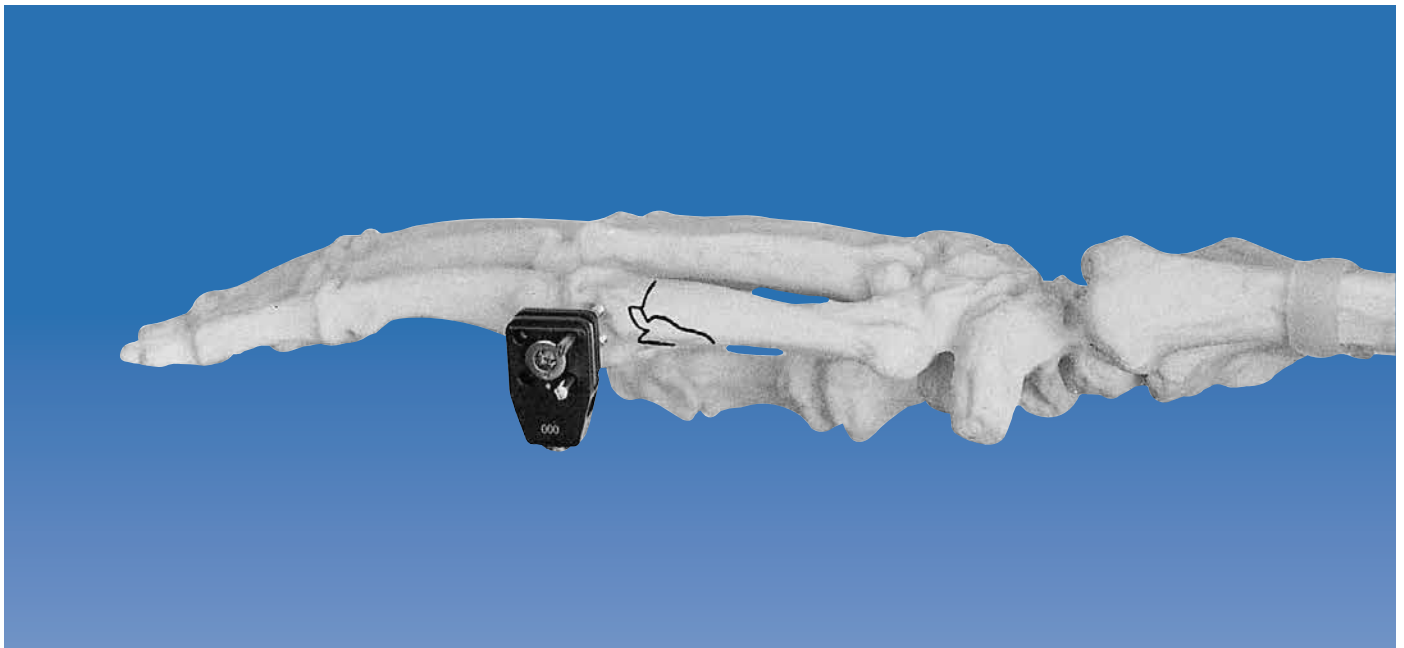
The Minifixator is applied so that in one clamp the wires converge in the small distal fragment. The other clamp is applied in the same manner as described for a shaft fracture of the fifth metacarpal.

**The First Threaded Wire**


The first wire to be inserted is the most volar wire in the distal fragment. This wire is placed in the frontal plane, parallel to the articular surface. If possible, the joint capsule should be avoided. In very distal fractures, however, this may not always be feasible.



The clamp is now applied over the wire and the wire trimmed.



The second wire is now inserted in the clamp hole dorsal to the first, so that this pair is in the transverse plane. The second wire will converge with the first as it is being introduced, so that even small fragments can be penetrated by both wires. Convergence of the wires will only occur when the clamp is oriented correctly. **If the clamp is mounted with the cam facing the bone, the wires will diverge.** Penetration of the wires must be checked in both planes with the Image Intensifier.



### Completion of the Application

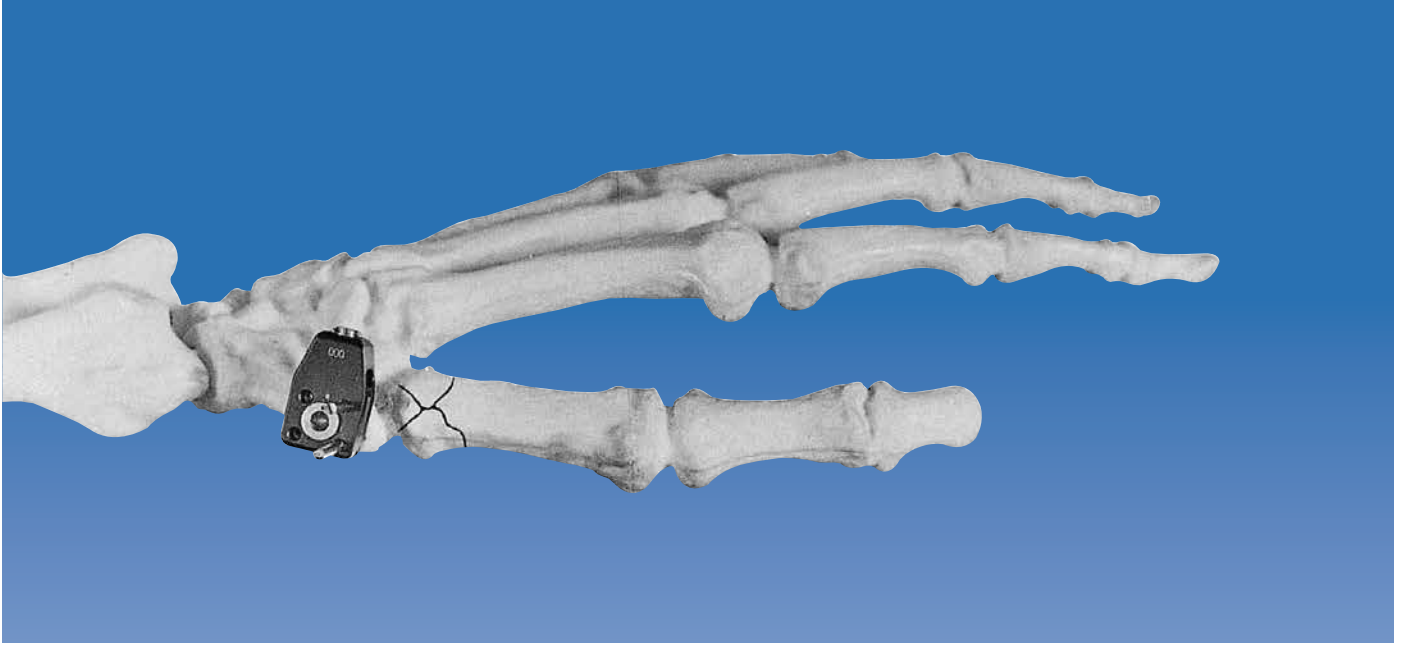
The remainder of the application follows that for shaft fractures of the fifth metacarpal. Rotational deformities very often occur in association with sub-capital fractures, and particular attention should therefore be paid to ensure correct rotational alignment.

### Shaft Fractures of the First Metacarpal

Shaft fractures of the first metacarpal are treated in the same way as those of the fifth metacarpal (see pages 6-10). It is important, however, to avoid any tethering of the extensor and abductor tendons.



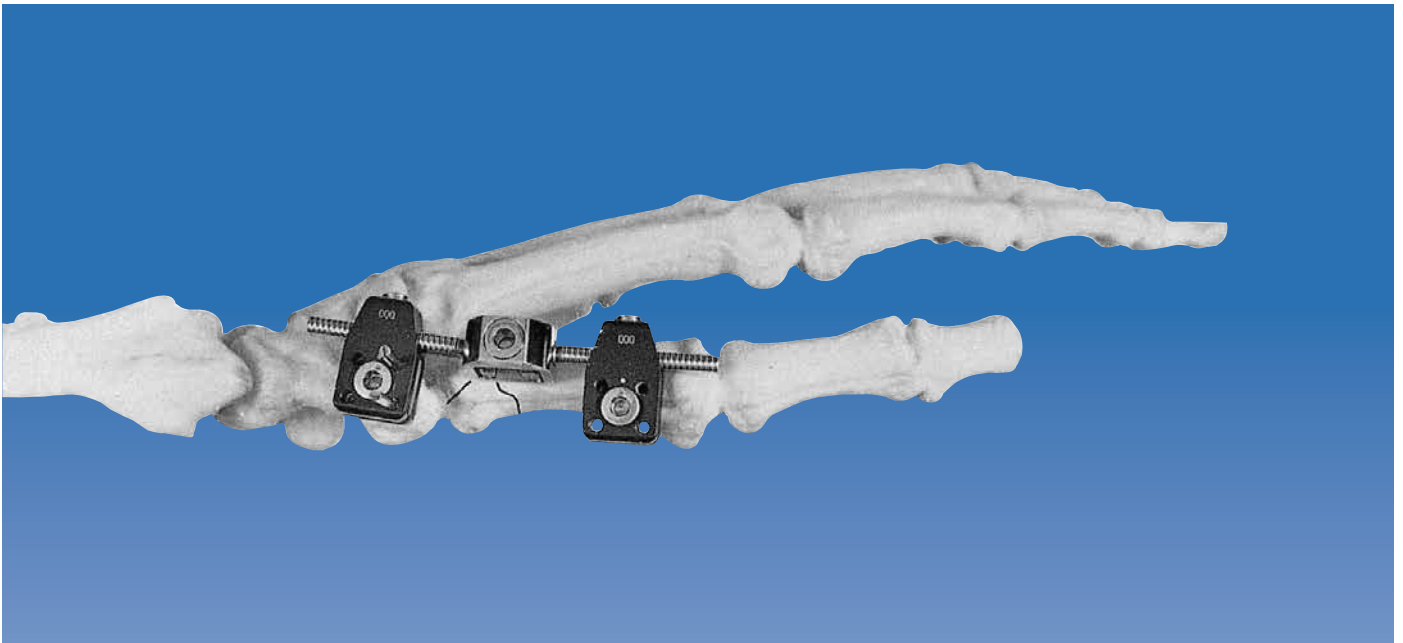
## Fractures at the Base of the First Metacarpal



A possible indication for use of the Minifixator is a comminuted fracture of the base of the first metacarpal. In this instance, the fixator is mounted between the trapezium and the shaft of the first metacarpal.

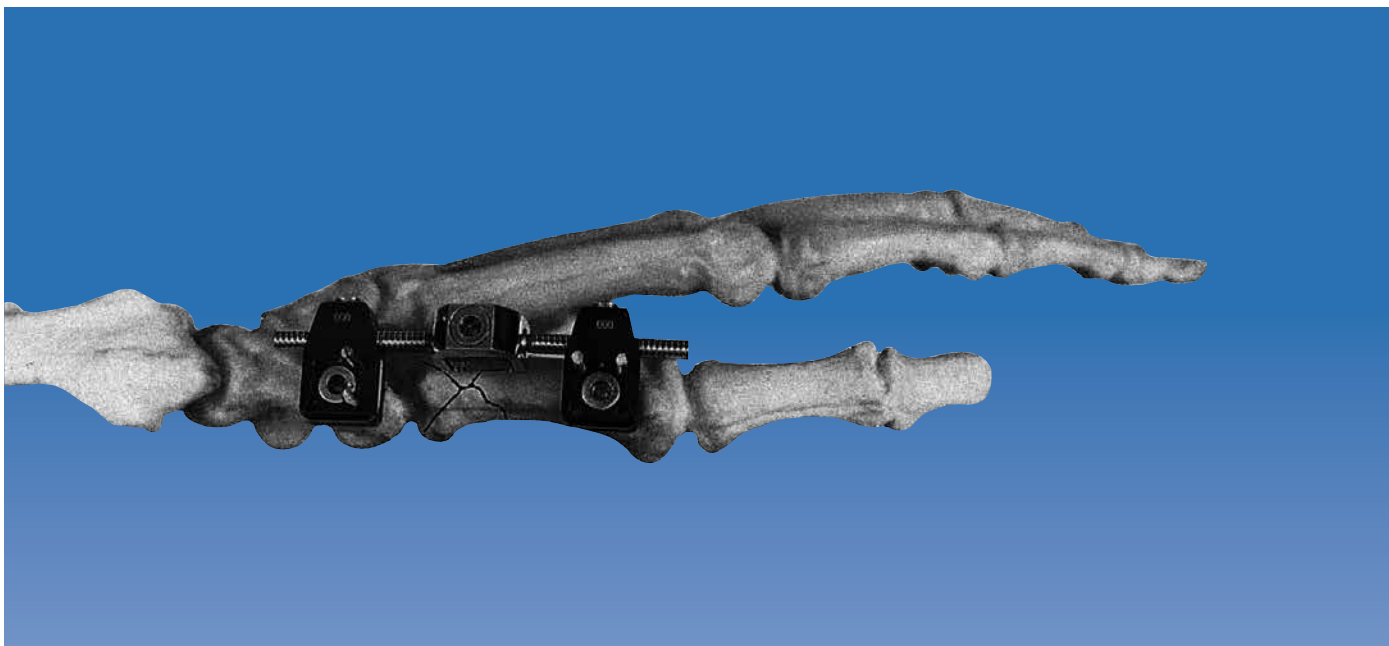
### The Threaded Wires of the First Clamp

The first wires to be inserted are those in the trapezium. They are introduced in the transverse plane (i.e. convergent wire placement) using a semi-open approach in order to avoid injury to the tendons crossing the anatomical snuff-box. Note that in this indication both clamps are applied upside down.



### Fixator Application

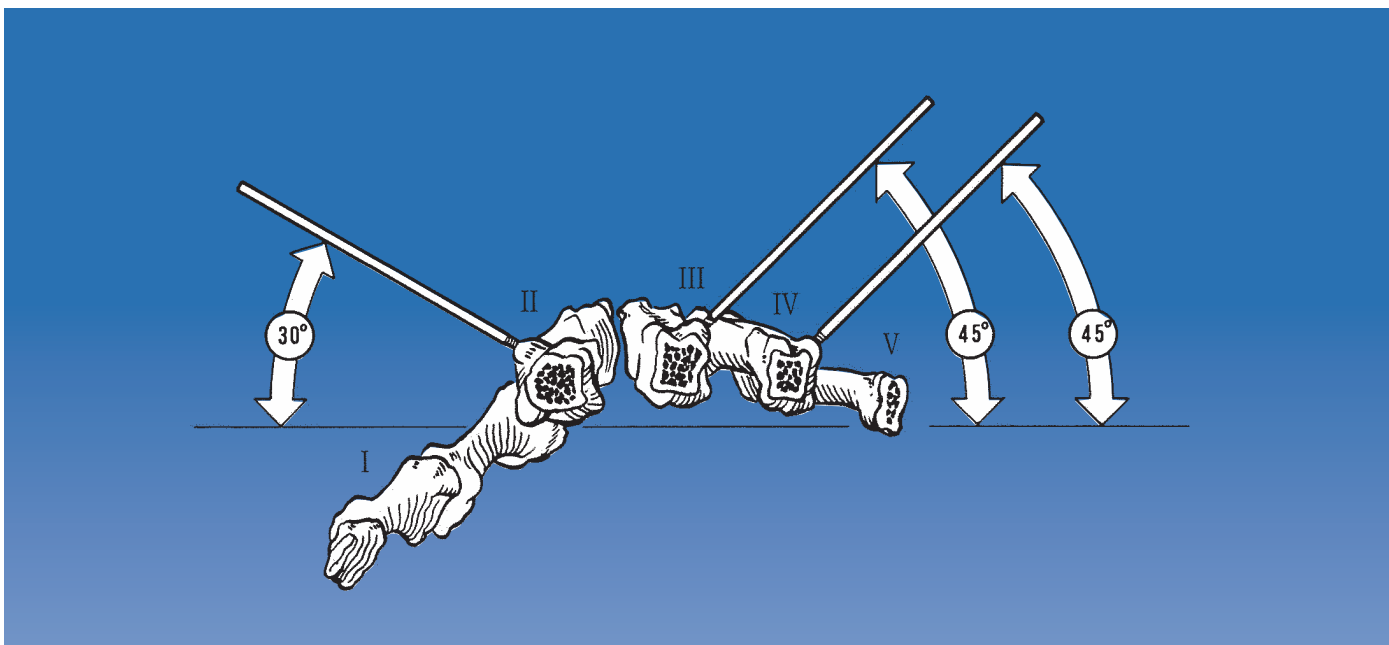
The Minifixator body and the clamp for the shaft of the first metacarpal are now attached.



### The Threaded Wires of the Second Clamp

The wires for the diaphysis are now inserted in the longitudinal plane (i.e. parallel wire placement), and the deformity corrected by ligamentotaxis. If joint congruity cannot be achieved, open reduction should be carried out, and additional internal fixation with screw and/or wires may be necessary.

### Special Considerations in other Metacarpal Applications

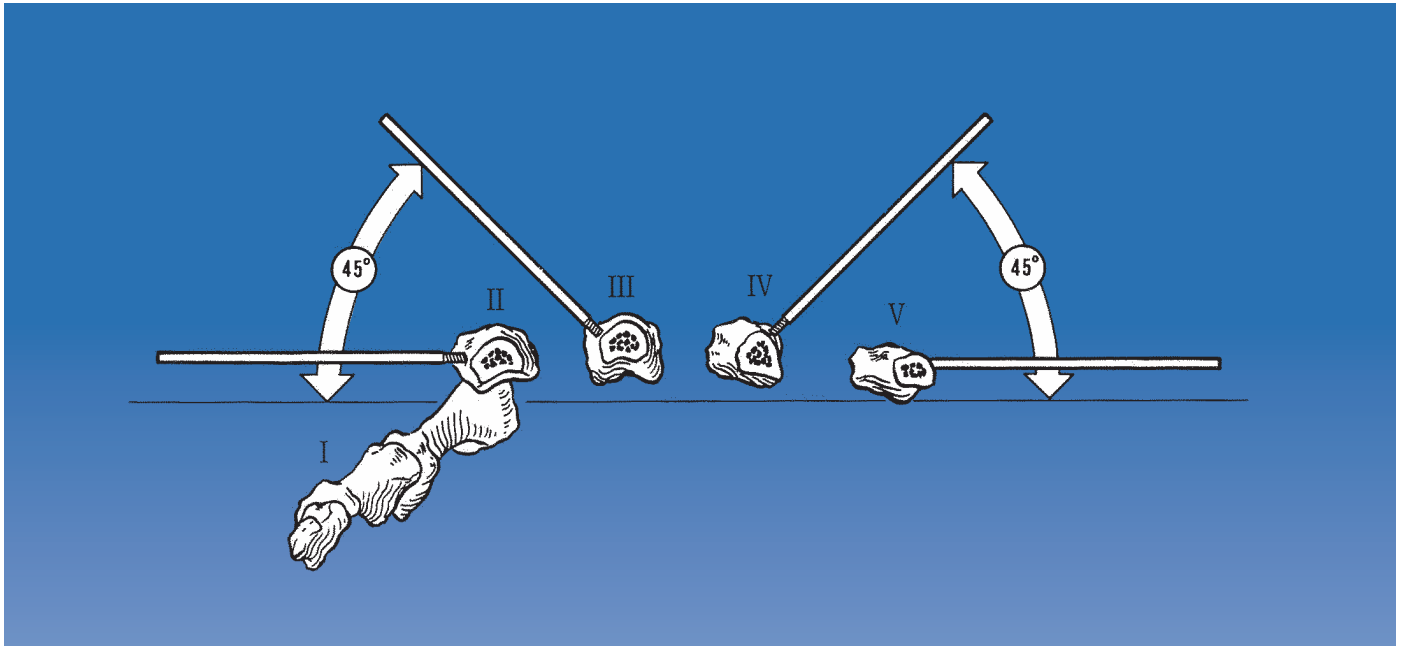


In the second metacarpal the wires are inclined dorsally at an angle of 30 degrees to the frontal plane.

In the third and fourth metacarpals the fixator is applied from the ulnar side. The wires are inclined dorsally at an angle of 45 degrees to the frontal plane. Care should be taken to avoid injury to the tendons and neurovascular structures on the volar side of the metacarpal bones during wire insertion.

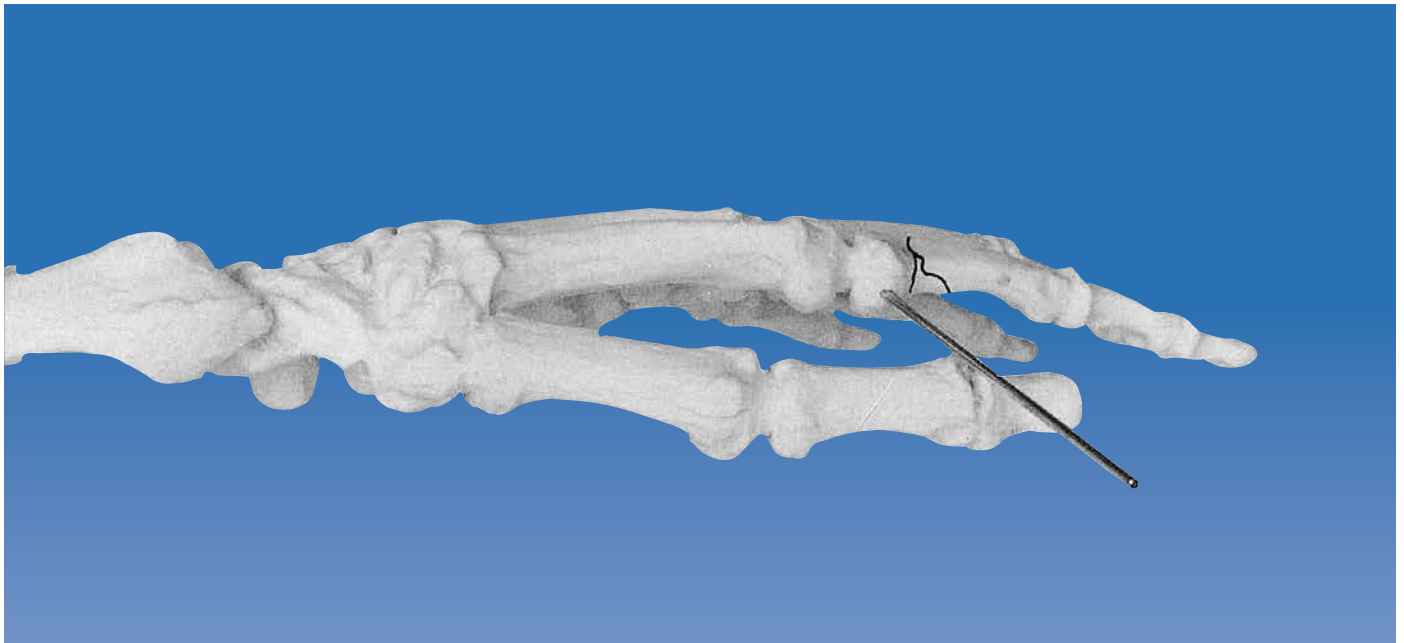


PHALANGEAL FRACTURES



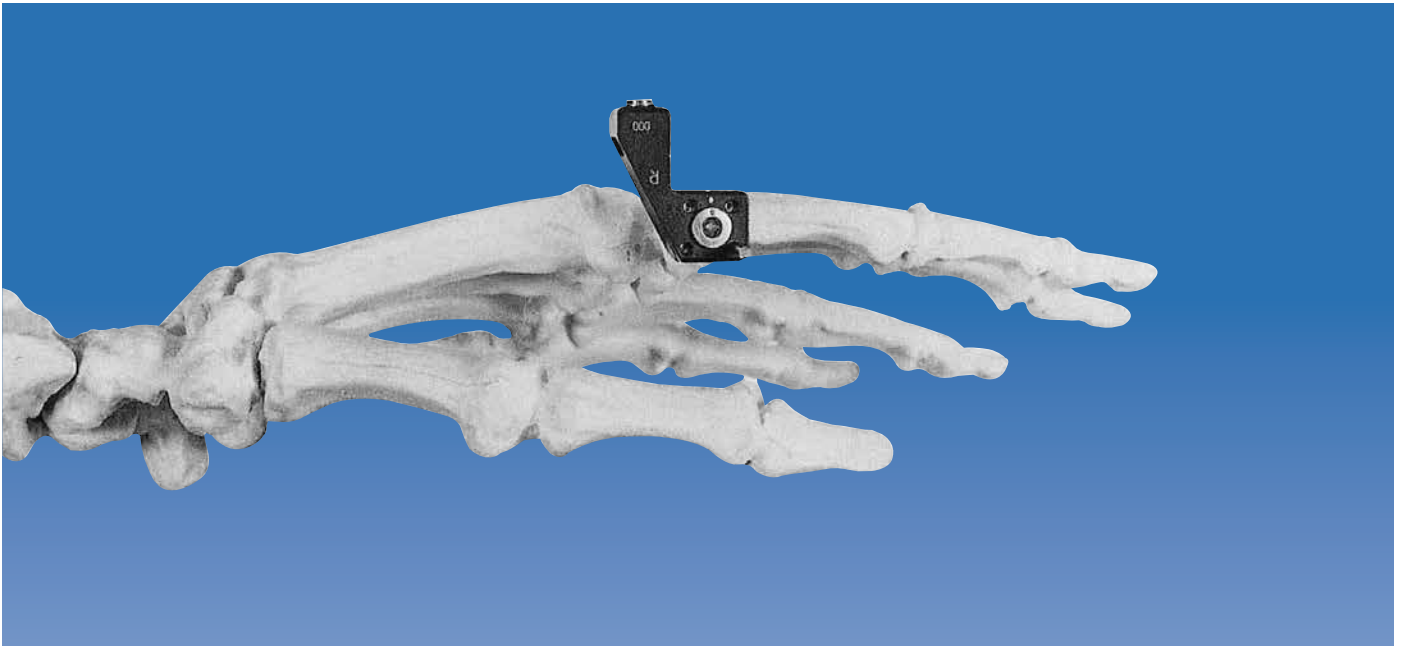
The use of the Pennig Minifixator in the phalanges is somewhat more challenging, since the dimensions are so small. At the base of the proximal phalanx 2.0mm threaded wires can be used, but at more distal sites, 1.6mm threaded wires should be employed. Wherever possible, bridging of the joint should be avoided. If this is inevitable, care should be taken to ensure that over-distraction does not occur, and the joint should be fixed in a functional position. The L-clamp was developed to allow fixation in these small bones, and it enables the wires to be placed very close to the fracture line in both fragments. The principles outlined for applications to the metacarpal bones are applicable to the phalanges. Wires are placed first in the smaller fragment, and a transverse configuration of converging wires is usually necessary. In the proximal phalanx of the index and the little finger, the fixator can be applied in the frontal plane. In the middle and ring fingers, an angle of 45 degrees dorsal to the frontal plane is used. In the distal phalanx, the fracture may be held satisfactorily with only one wire in each fragment. In the other phalanges, two wires should be used.

Fractures of the Proximal Phalanx of the Index Finger



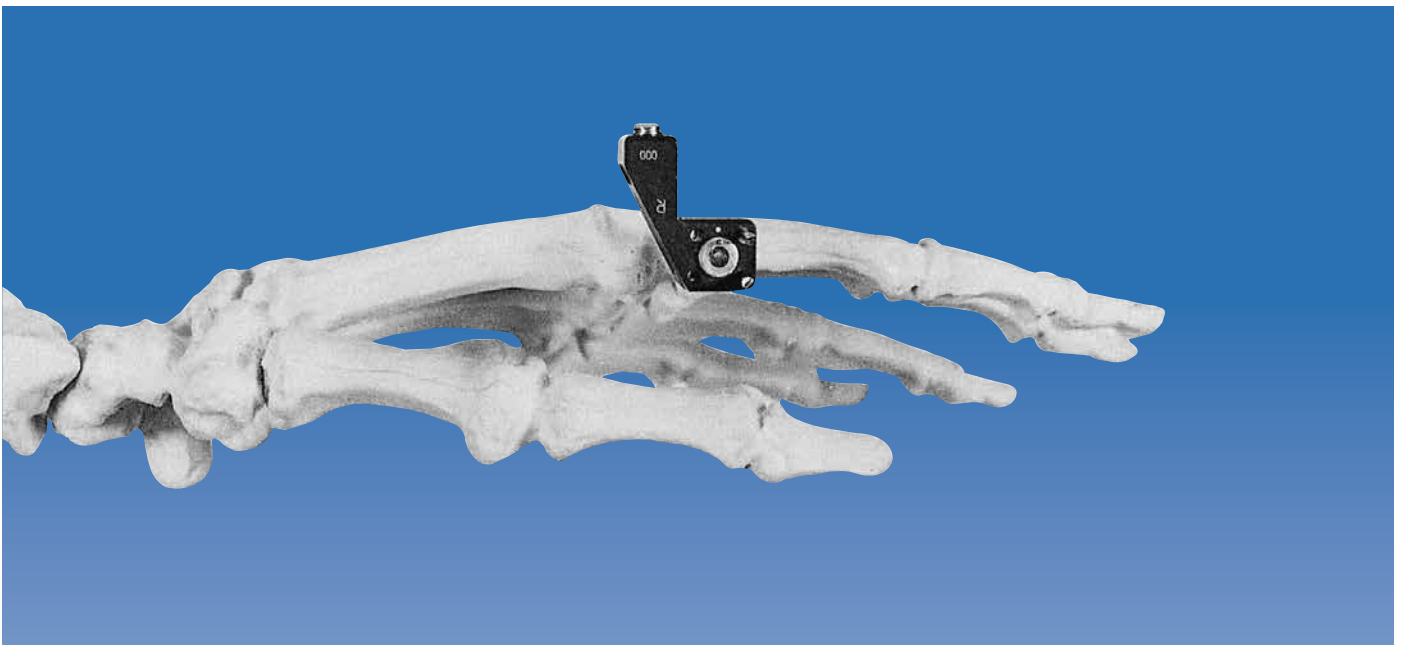
**The First Threaded Wire**

For a fracture close to the base of the proximal phalanx of the index finger, the first threaded wire (2.0mm) is inserted in the frontal plane, on the radial aspect of the base of the phalanx.



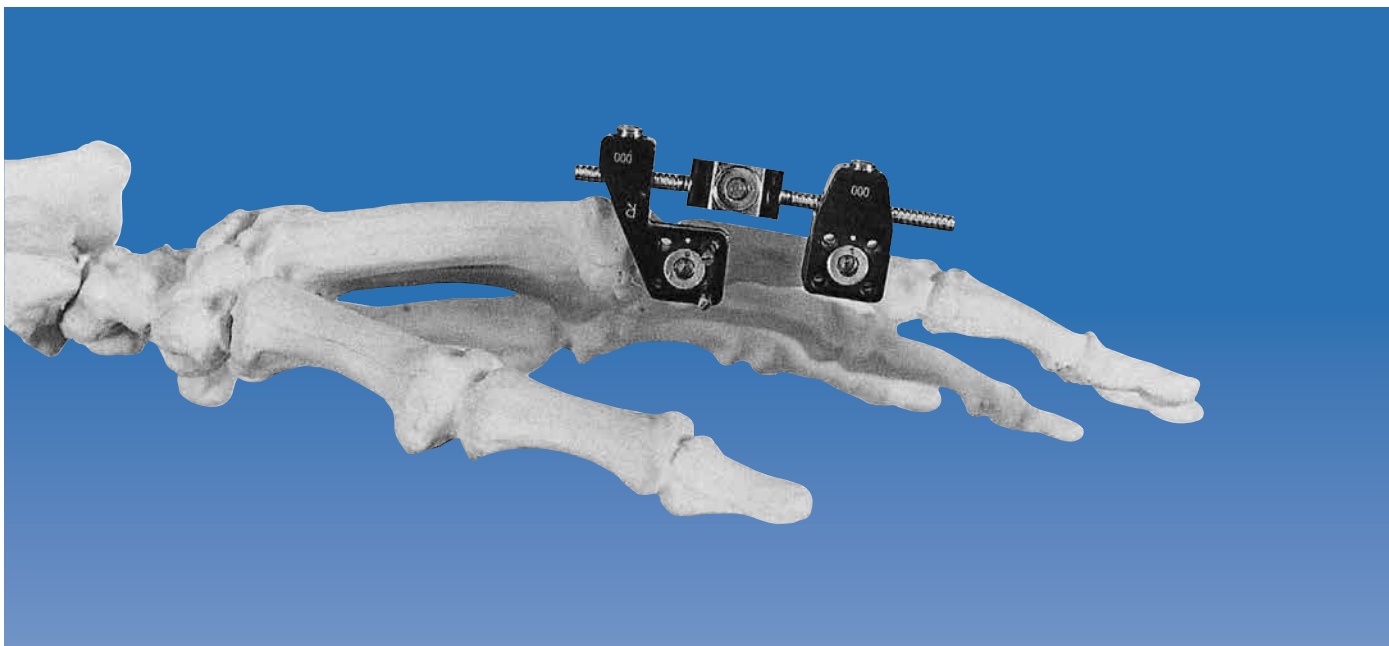
**The First Clamp**

A standard or L-clamp is applied over the wire, upside down, and the wire is trimmed to length.



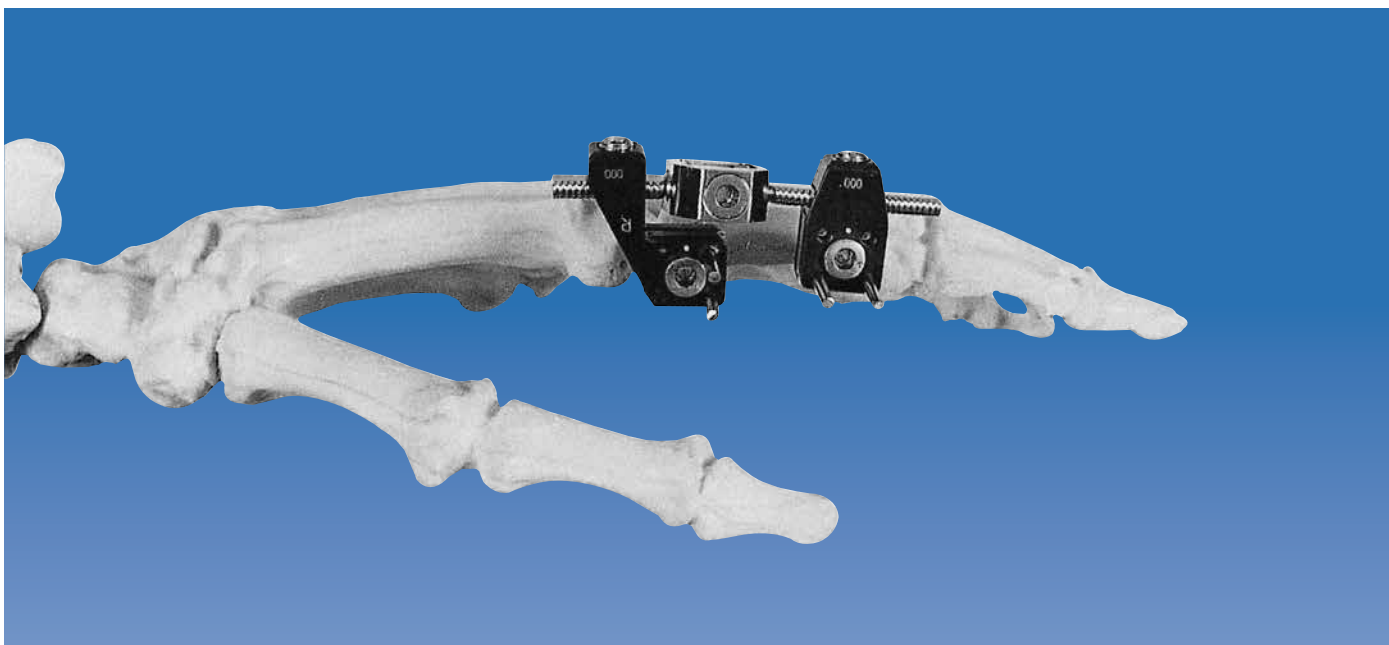
**The Second Threaded Wire**

The second wire is inserted, dorsal to the first.



**Fixator Application**


A short Minifixator body is now mounted, and a second L-clamp, or, if possible, a standard clamp, is attached.



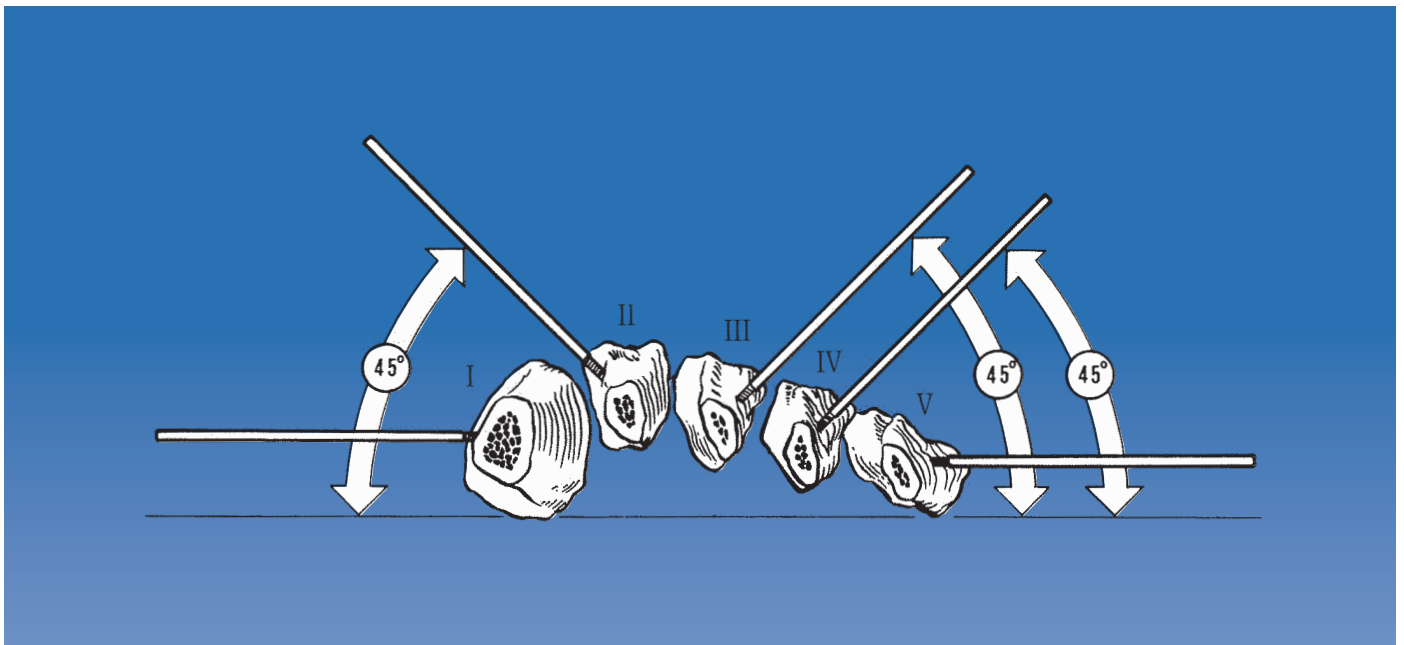
**Completion of the Application**

The second pair of wires is inserted as described for metacarpal fractures.

## METATARSAL FRACTURES



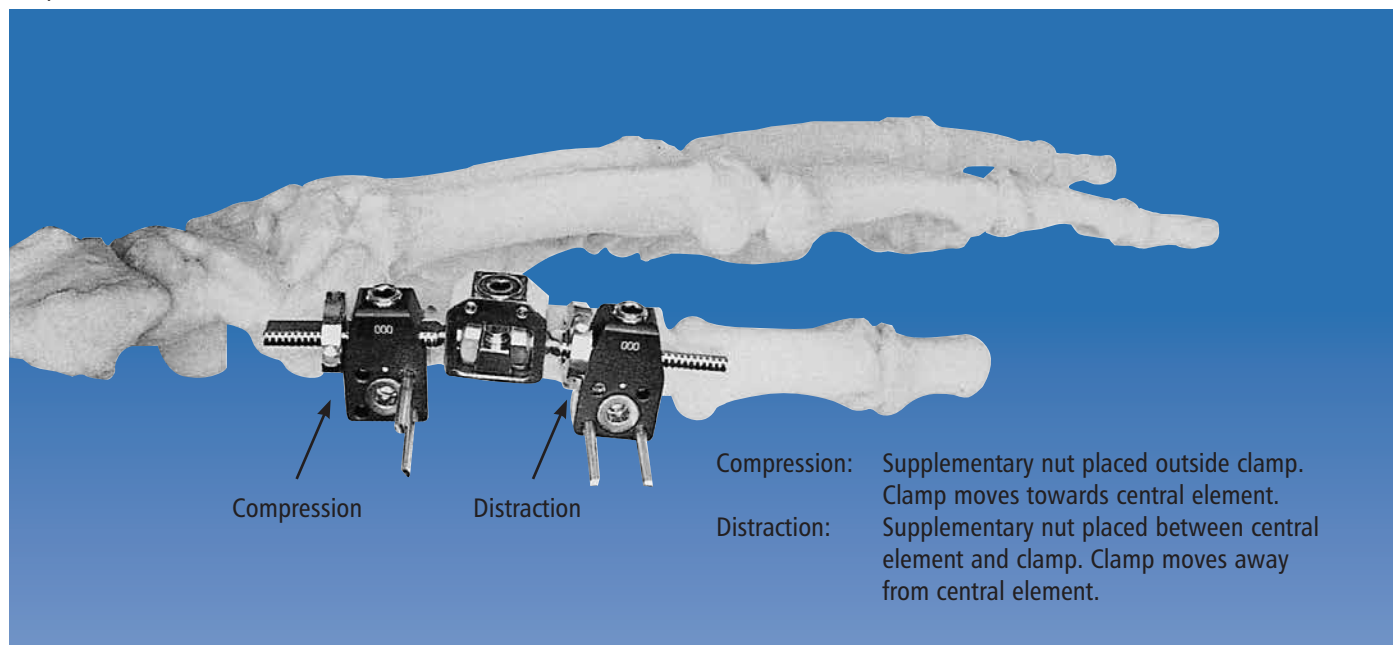
Most commonly, the fixator will be applied to fractures of the fifth metatarsal. The principles outlined for fractures of the metacarpals should be followed, and the fixator mounted in the frontal plane. Occasionally, a third wire can be introduced through a second standard clamp, depending upon the nature of the fracture and the degree of stability required. In the fifth metatarsal, the fixator should be applied upside down to permit the sole of the foot to touch the ground. Post-operatively, a special shoe may be worn.



In the first metatarsal, the fixator is also applied in the frontal plane, whereas in the second, third and fourth metatarsals, the wires are placed 45 degrees dorsal to that plane. Again, careful attention should be paid to avoid injury to the extensor tendons and neurovascular structures on the plantar aspect of the metatarsal bones. In fractures of the toes, the principles are the same as those described for the fingers.

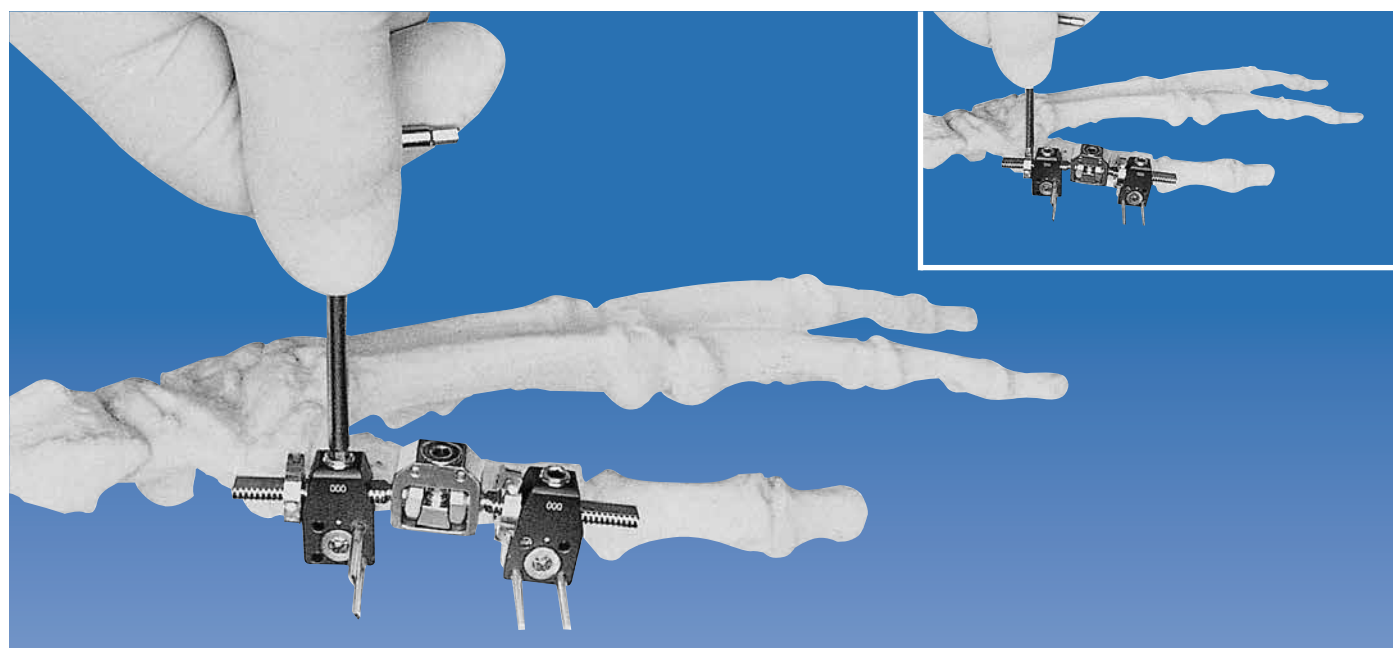
**SPECIAL INDICATIONS**

Aseptic or Infected Non-Unions

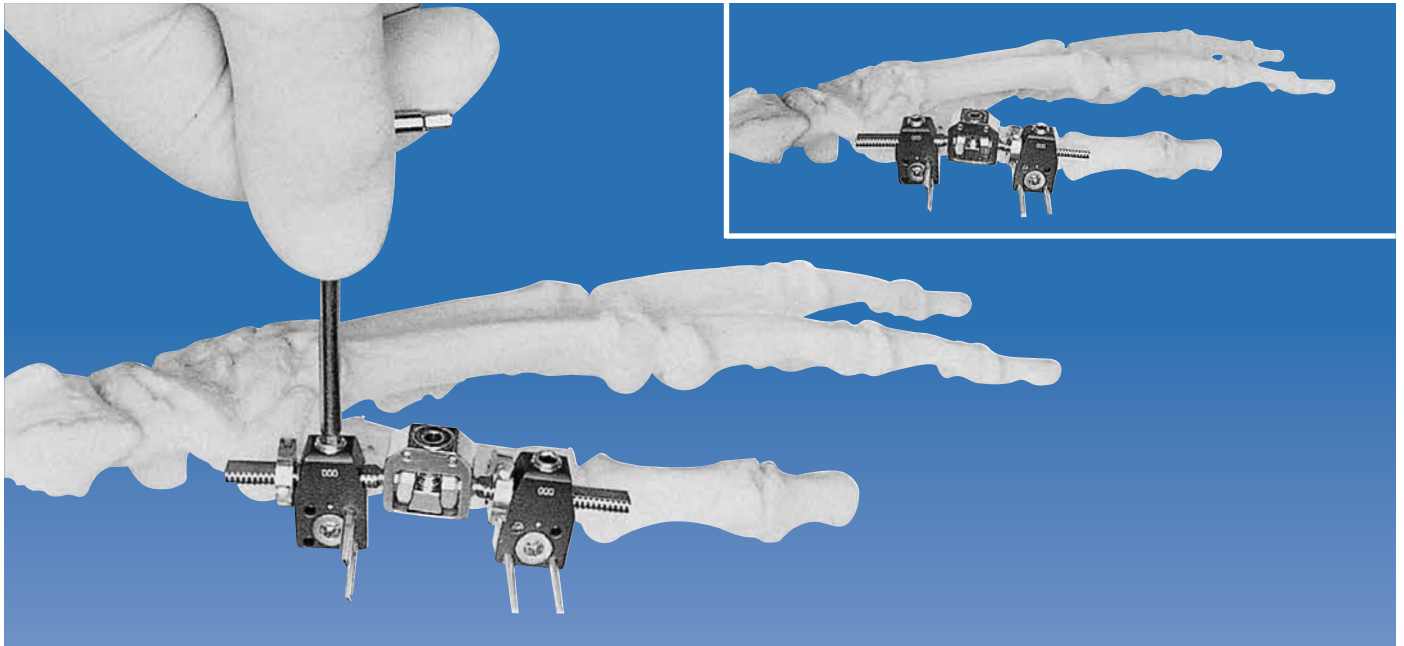


In non-unions, the application technique is similar to that described for fractures. Most non-unions benefit from compression, and in some cases the surgeon may wish to distract before compression, to stimulate callus formation.

Compression-distraction nuts are screwed on to one or both of the threaded bars; inside a clamp where distraction is required, and outside for compression.



The appropriate clamp locking screw is loosened, and either compression or distraction applied by turning the adjacent nut.



Once this procedure has been completed, the clamp locking screw is re-tightened, and where possible, the compression-distraction nut may be removed.

In aseptic or infected non-unions, the general principles of management must be followed, and the fixator represents only a part of the overall treatment protocol, which may include bone grafting.

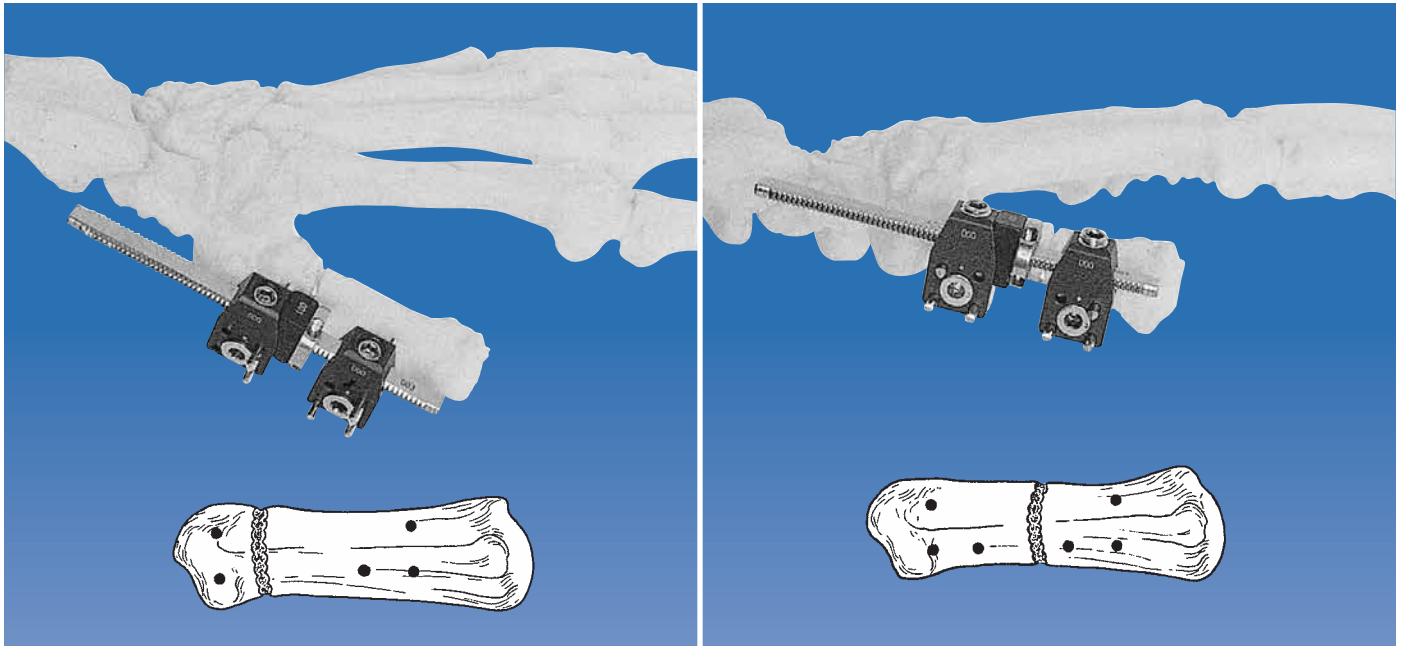
**Corrective Osteotomy**

In post-traumatic malunion and congenital deformity, the fixator can be used to correct metacarpal, metatarsal or phalangeal malalignment. This is particularly valuable in rotational deformities of the phalanges. As a general rule, correction should be carried out at the site of the original injury in post-traumatic cases. Bone healing usually proceeds faster at the metaphyseal-diaphyseal junction, and this site should be preferentially selected whenever possible. The application technique for corrective osteotomies is similar to that for metacarpal and phalangeal fractures, but one set of wires is applied at such an angle to the second pair that will result in correction of the deformity when they are reduced to the same plane following osteotomy.

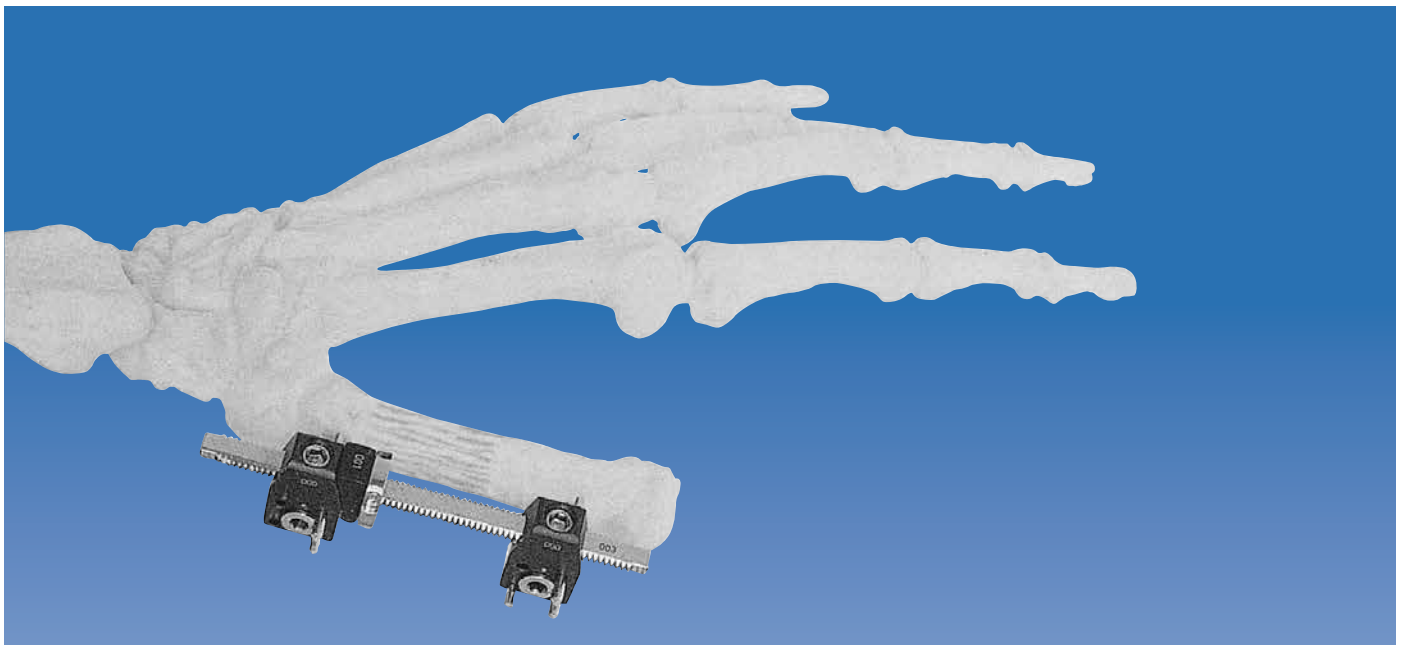
The first pair of wires is applied in the transverse plane (i.e. convergent wire placement) close to the joint. The required amount of correction is estimated when deciding on the plane of insertion of the second pair of wires. The osteotomy is then carried out, preserving the periosteum, and correction performed. Provided that pre-operative planning was correct, the two pairs of wires should be in the same plane following correction.

The clamps are locked to the wires. The orientation of the bone is checked, and one clamp locking screw and the double ball-joint are tightened. Before the second clamp is locked to the bar, a compression-distraction nut is used to enhance the mechanical stability of the osteotomy site. The principles of compression described for non-union are followed. Time to union is usually longer in corrective osteotomies than in fractures, and healing times of 9-12 weeks may be expected. During this period, physiotherapy plays an important role.

Lengthening and Bone Transport




In principle, it is possible to lengthen phalanges, metacarpal and metatarsal bones. The most common indication, however, is likely to be lengthening of the first metacarpal following amputation of the thumb. A lengthening bar with standard clamps or L-clamps is applied in the frontal plane using 2mm wires. A third wire may be added in each clamp to improve stability especially in osteoporotic bone and in the metatarsals. A metaphyseal or mid-shaft osteotomy may be performed. A compression-distraction nut should be placed on the lengthening bar before the second clamp is applied. The lengthening bars are available complete with spacers, which should be placed with the angled side in contact with the standard clamp and the flat side in contact with the compression-distraction nut (see page 5). In this way, complete surface contact between the nut and the standard clamp is ensured during distraction. When distraction is performed using an L-clamp, there is no need for the spacer.



A delay of 7-10 days before commencing distraction is advisable. Distraction is then performed at a rate of 0.5mm per day (one quarter turn of the nut twice a day). The rate of distraction should be temporarily increased where rapid ossification is observed, or reduced if ossification is slow. Callus formation should be carefully monitored with standard radiographs weekly.





When bone transport is employed for the treatment of bone loss, a lengthening bar is used in conjunction with three clamps. Two clamps are applied to the larger segment and the osteotomy performed between them, preferably at a metaphyseal site. Note that the segments must be aligned prior to insertion of the wires and application of the lengthening bar.

The numbers of the clamps in the above picture, indicate the order in which they should be applied.

If some shortening is present at the end of transport, the clamp locking nut of clamp 2 is loosened and lengthening continued between clamp 1 and 3.

### Replantation Surgery

Due to the speed of application, the fixator is particularly useful in replantation surgery. The general principles outlined for fractures are followed, and the fixator mounted in such a way that the necessary, and more important soft tissue management is not hindered. In replantation surgery, the fixator may be expected to remain in place longer than for standard fractures. Whenever the fixator is used for replantation surgery, bridging of a joint should be avoided if at all possible. This may expedite functional recovery of the replanted extremity.

### Soft Tissue Correction and Arthrodiastasis (Articulated Distraction)

The distraction capacity of the fixator can be used to widen the web space, for example, between the first and second metacarpal bones, following burns or scarring from other causes. This technique can be used to augment other hand surgery techniques and again, accepted surgical procedures should be followed. In contrast to bone lengthening procedures, soft tissue correction by distraction can be carried out from day one onwards.

The Minifixator may be mounted between the first and the second metacarpals. The rate of distraction is between 0.5mm and 1mm per day (a half to one full turn per day). Substantial scar formation may need to be removed beforehand.

Arthrodiastasis, especially in the proximal interphalangeal joints, is still under investigation, and no firm recommendations can yet be made regarding use of the Pennig Minifixator in this indication.

## CONTRAINDICATIONS

Contraindications to the use of the Pennig Minifixator in the hand and foot are similar to those for external fixation in general. These include severe osteoporosis, patients who are HIV positive and patients with severe, poorly controlled diabetes mellitus. In addition, in uncooperative or predictably difficult patients, external fixation is not advisable. Careful patient selection will therefore avoid problems at a later stage.



Post-operatively, the arm should be elevated, and the patient should be encouraged to keep the arm elevated while walking. A sling, however, should not be used. Routine review of the wire entry sites twice weekly, is advisable. Dressings, in general, are not necessary after two weeks, but the Minifixator must be protected by a bandage. The patient should not be allowed to use soap on the wires, but tap water is permitted. Physiotherapy is advisable for any patient following hand surgery, and this applies to the operations described in this manual. The Minifixator is removed when, in the opinion of the attending surgeon, bony union has occurred.

The Pennig Minifixator is designed to allow full function of the hand immediately after surgery, and this should be encouraged in a cooperative patient. The shifting and lifting of heavy weights, however, is not allowed, to avoid over-straining the wires. Wire site care is an integral part of the post-operative management programme, and should be carried out according to the protocol outlined in the Orthofix Pin Site Care Video and booklet.

In the foot, a plantar plaster may be used for three weeks and the foot should be elevated frequently. Depending upon the fracture pattern and associated injuries, weightbearing may need to be delayed for more than a week. In most cases, partial weightbearing can be commenced once the swelling has gone down. The wearing of normal shoes is not possible with the fixator in place and a special shoe with a section cut away, may be used.

### **Removal of the Fixator and Threaded Wires**

Removal of the fixator is carried out by unlocking all the fixator screws and sliding the fixator clamps off the threaded wires. The wires are then removed using the threaded wire extractor (M442) since, because of their threaded ends, they cannot be simply pulled out. The protruding end of the wire is inserted into the threaded wire extractor with the locking screw open. After tightening the locking screw with the 3mm Allen wrench, the wire is removed from the bone by turning the threaded wire extractor in a counter-clockwise direction. It is important not to bend or twist wires as this may cause them to jam in the clamp. Removal of the wires can normally be done in the outpatient clinic without analgesics.

Where the fixator cannot be removed as described above, due to deformation of the wire ends, or in cases where the wires converge in the bone, the wire or wires in question should be removed prior to fixator removal.

If the wires have been trimmed too close to the clamp for secure attachment of the threaded wire extractor, the clamp should be pushed towards the skin to obtain better purchase. Should this not be successful, the wires should be cut between the skin surface and the clamp. After removal of the wires, the wire sites are washed with disinfectant and a simple dressing applied. Healing of the wire sites normally occurs within 3-4 days.



Orthofix Srl wishes to thank:

Prof. Dr. D. Pennig

St. Vinzenz-Hospital  
Köln - Germany


for his invaluable help in the preparation of this manual.



Manufactured by:  
ORTHOFIX Srl  
Via Delle Nazioni 9, 37012 Bussolengo (Verona), Italy  
Telephone +39 045 6719000, Fax +39 045 6719380



**Distributed by:**



Instructions for Use: See actual package insert for Instructions for Use.

Caution: Federal law (USA) restricts this device to sale by or on the order of a physician. Proper surgical procedure is the responsibility of the medical professional. Operative techniques are furnished as an informative guideline. Each surgeon must evaluate the appropriateness of a technique based on his or her personal medical credentials and experience. Please refer to the "Instructions for Use" supplied with the product for specific information on indications for use, contraindications, warnings, precautions, adverse reactions and sterilization.

[www.orthofix.com](http://www.orthofix.com)

PM-090-E0 H 03/18

