

Limb Reconstruction System

1 INTRODUCTION

2 FEATURES AND BENEFITS

Components for Standard Application

Components for Gradual Correction

Components for Acute Correction

7 EQUIPMENT REQUIRED

9 LENGTHENING AND BONE LOSS

General Principles

Lengthening

Bone Loss

25 CORRECTION OF DEFORMITIES

General Principles

Advanced Micrometric Swivelling Clamp and Advanced Translation-Angulation Clamp

Use of the Advanced Multiplanar Clamp

Use of The Advanced T-Garches Clamp

Use of the Advanced Ring Hinge

Use of the Advanced Acute Correction Templates

47 REFERENCES

49 APPENDIX

Orthofix wishes to thank
the following surgeons for their contribution
to the development of the technique:

S. NAYAGAM, MD
M. OLEKSAK, MD

INTRODUCTION

The Orthofix Limb Reconstruction System (LRS) is a series of modular monolateral external fixators to be used in reconstructive procedures for treatment of limb shortening, bone loss, open fractures, non-union and angular deformities.

Many years of clinical experience have confirmed the efficacy of the device, providing good outcomes for the indications above as well as facilitating improvements over the original surgical technique (see pages 10 - 11 with references).

The innovation in the Advanced LRS has produced improved efficiency; increasing its ease of application in deformity correction, joint contracture and bone transport with short segments.

This has expanded the available choices for the surgeon as there is now a system of external fixation for the effective treatment of deformity and bone defects that is better tolerated by the patient.

The system is designed to manipulate 2 or more bone segments in relation to each other: by separating them slowly to create new bone; by altering their relative position to correct a deformity; or by doing both procedures together. This is achieved by means of 2 or 3 bone screws in each bone segment. The screws are fixed firmly in screw seats in clamps on the Advanced Rail; these clamps can then be moved along the axis of the rail. Angulation and translation of one bone segment in relation to another is possible; acute correction is performed using acute angular correction templates whereas gradual correction is done using progressive correction clamps. In conjunction with a T-Garches clamp, accurate correction of varus or valgus deformities at the knee, (either acutely or gradually through a hemicallotaxis technique) is enabled. The ability to position bone screws at different levels along the axis of the bone serves to provide excellent stability and reduce the working length; these features allow the Limb Reconstruction system to overcome the problems of secure fixation in comminuted fractures with bone loss, non-unions, malunions and in osteoporotic bone.

The Advanced LRS provides the following benefits for the surgeon:


- Flexibility and versatility
- Less surgery time
- Availability of radiolucent components
- Safety during angular correction
- High stability
- Short learning curve

FEATURES AND BENEFITS

Components for Standard Application

Advanced Rail

- Clamps can be positioned on both sides of the rail because of the double groove
- Available in different lengths: 120, 200, 250, 300, 350 and 400 mm
- Can be used on right and left sides
- Available in aluminium and in radiolucent material



Advanced Straight Clamp (53530)

- Has increased distraction capability because of the shorter clamp length (50 mm)
- It has 4 holes for the compression-distraction unit; this provides greater efficiency in driving the correction as the unit can be positioned closer to bone when sited in the inner holes of the clamp cover
- It acts as its own template clamp for screw guides, enabling screws to be inserted in the correct position



Advanced Metaphyseal Clamp (53520)

- Multiple screw configurations
- Screws can be inserted in short or narrow bone segments because of converging screw seats in the T-component
- Stable fixation of short bone segments (3 screws in two planes)
- Straight part radio opaque, T-component radiolucent



Advanced Inclination Clamp (53580)

- Screws can be positioned with different inclinations to enable capture of bone segments that have a curvature in their profile
- Left and right use by removing the locking screw (a) and repositioning it on the opposite side
- Allows insertion of the screws in up to 14° degrees of inclination.

**Advanced Dyna-Ring (53536)**

- To be locked to the rail with its silicone cushion just in contact with the clamp which has been unlocked to enable dynamisation
- Permits controlled dynamisation of the segment concerned and thus acts as a safeguard against collapse
- Allows earlier conversion from a rigid to a dynamic mode and reduces the neutralisation period

**Advanced Ring Hinge (53570)**

- Compatible with Sheffield and Truelok systems
- Facilitates connection of a ring to the end of a rail and so enables cross-joint stabilisation
- If used in conjunction with a ring for angular correction, a minimum of 3 bone screws should be used for bone fixation
- Radiolucent



Components for Gradual Correction


Advanced Micrometric Swivelling Clamp (53115)

- Gradual angular correction up to $\pm 24^\circ$
- Graduated scale indicating the amount of deformity corrected
- Clamp can be rotated without loss of stability as bone screws are fixed in the clamp and rotate together on a separate platform
- The CD-unit LRS connection facilitates correction by distributing the load across the 4 holes of the clamp cover



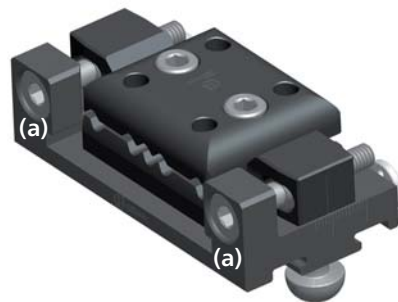
Advanced Translation Clamp (53111)

- Single threaded screw (a) provides 1mm of translation with each turn and enables gradual correction along the axis of the screws
- Up to 10mm of translation is possible



Advanced Micrometric Translation-Angulation Clamp (53585)

- Enables gradual translation and angulation through:
 - turning both screws (a) in the same direction (clockwise or anti-clockwise) produces translation
 - turning screws in opposite direction produces angulation
- New locking solution provides increased stability
- Translation up to 16 mm
- Gradual angular correction up to $\pm 13^\circ$



Advanced T-Garches Clamp (53031)

- Angulates in one plane and permits:
 - tibial lengthening in the proximal metaphysis, with good control of valgus or varus deviation
 - angular correction in the proximal tibia by hemicallotasis
- Two lateral swivelling screw seats allow convergent siting of the outer screws
- Use with 3 bone screws is advised for optimum stability
- Ergonomic profile
- Radiolucent



Advanced Multiplanar Clamp (53581)

- Attached to either end of the rail
- For gradual correction of angular deformity in any plane up to $\pm 35^\circ$ (including translation up to a maximum of 12 mm)




LRS ADVanced Sandwich Clamp

53548 LRS ADVanced Sandwich Clamp, height: 8 mm*

53547 LRS ADVanced Sandwich Clamp, height: 15 mm*

- The Sandwich Clamp allows the surgeon to raise the plane of the screws above the rail, or to place them in two planes, as described on pag 22.



Compression-Distraction Unit Attachment

*This component is not included within the Steribox A: 53590C

Components for Acute Correction

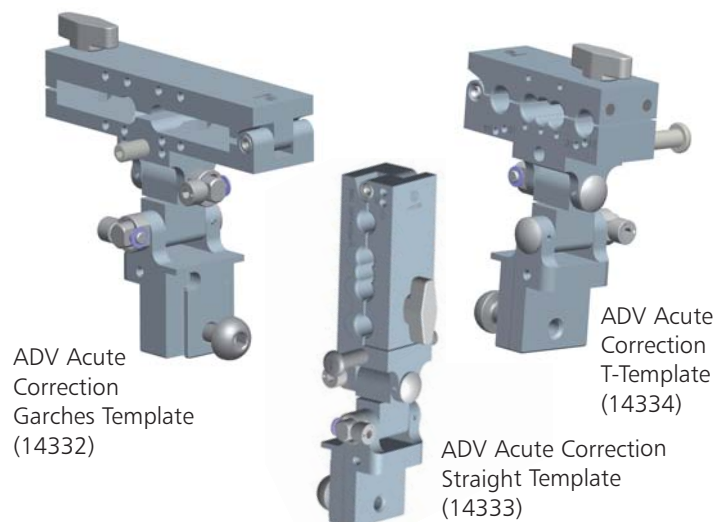
Advanced Ball-Joint Coupling (53541)

- To be used with: Torbay-Garches Clamp (10052), ProCallus Straight Clamp (90006) or ProCallus T-Clamp (90007)
- To be attached to either end of the rail
- Enables precise, immediate corrections to be made
- Allows unrestricted rotation and up to 36° of angulation of the clamp in all planes




Advanced Acute Correction Templates

- Attaches to the end of the rail and allows screw insertion to reflect the deformity
- There are two orthogonal hinges, allowing correction of coronal and sagittal plane deformities
- Enables screws to be inserted at right angles to the axis of the bone segment on either side of a deformity. Is able to correct angulation in any plane



Advanced Acute Derotation Template

- The Advanced Acute Derotation Template consists of two components:
 1. An arc with 130 mm radius free to slide along the rail
 2. A template clamp, which can be slid round the arc to a predetermined size of correction. The maximum amount of correction possible is 50°
- A 100 mm radius arc is available to accommodate less bulky soft tissues, providing up to 47° of correction
- Can be used alone or in combination with an acute angular correction template for the correction of both angular and rotational deformity






EQUIPMENT REQUIRED

53995 - ADV LRS Instruments Steri-Box Empty

Can accomodate:

Part No.	Component Description
Lower Tray	
2x10012	Allen Wrench 3 mm
2x10017	Allen Wrench 6 mm
1x10025	Torque Wrench 6 mm
2x91150	Universal T-Wrench
1x11004	Tapered Trocar
1x30025	Torque Wrench 5 mm (31000 Series)
2x1101101	Cannulated Drill Bit Ø 3.2 mm, length 200 mm
2x1101201	Cannulated Drill Bit Ø 4.8 mm, length 280 mm
2x11144	Ruland Pilot Wire Guide Ø 2 mm, length 75 mm
2x11145	Ruland Pilot Wire Guide Ø 2 mm, length 115 mm
2x30017	Allen Wrench 5 mm
2x36017	Allen Wrench 4 mm
1x11111	Hammer
Central Tray	
2x11104	Drill Guide, Ø 4.8 mm, length 40 mm
2x11105	Drill Guide, Ø 4.8 mm, length 80 mm
2x11106	Drill Guide, Ø 3.2 mm, length 40 mm
2x11116	Drill Guide, Ø 3.2 mm, length 80 mm
2x11125	Drill Guide, Ø 4.8 mm, length 140 mm
5x80122	X-Wire without olive Ø 2 mm, length 400 mm
2x1100201	Drill Bit, Ø 4.8 mm, length 240 mm
2x1100301	Drill Bit, Ø 3.2 mm, length 200 mm
2x1100701	Drill Bit, Ø 4.8 mm, length 280 mm
1x10200	Sterilizable Screw Covers (pack of 20)
2x11005	Drill Bit Stop Unit, Ø 4.8 mm
2x11006	Drill Bit Stop Unit, Ø 3.2 mm
Upper Tray	
10x11102	Screw Guide, length 60 mm
10x11103	Screw Guide, length 100 mm
10x11124	Screw Guide, length 160 mm

53995UEC - ADV LRS INSTRUMENTS STERI-BOX COMPLETE



53990 - ADV LRS Components Steri-Box Empty A

Can accommodate:

Part No.	Component Description
Upper Tray	
6x53530	ADV Straight Clamp
1x53560R or 53560	ADV Radiolucent LRS rail 400mm or ADV LRS rail 400mm
1x53555R or 53555	ADV Radiolucent LRS rail 350mm or ADV LRS rail 350mm
1x53550R or 53550	ADV Radiolucent LRS rail 300mm or ADV LRS rail 300mm
1x53549R or 53549	ADV Radiolucent LRS rail 250mm or ADV LRS rail 250mm
1x53545R or 53545	ADV Radiolucent LRS rail 200mm or ADV LRS rail 200mm
1x53544R or 53544	ADV Radiolucent LRS rail 120mm or ADV LRS rail 120mm
2x50008	Compression Distraction Clicker-extends to 4cm
2x50009	Compression Distraction Clicker-extends to 8cm
1x53580	ADV Inclination Clamp



Lower Tray

1x53115	ADV Micrometric Swivelling Clamp
1x53111	ADV Translation Clamp
1x53585	ADV Micrometric Translation-Angulation Clamp
1x53520	ADV Metaphyseal Clamp
1x53031	ADV T Garches Clamp
1x53004	ADV Garches CD Unit Standard extends 5,5cm
1x53005	ADV Garches CD Unit Long extends 10cm
1x53034	ADV TrueLok™ kit for Ring Connection
1x53581	ADV Multiplanar Clamp
1x53570	ADV Ring Hinge
2x53536	ADV Dyna-Ring
1x53590	ADV Knee Hinge*

53990C - ADV LRS COMPONENTS STERI-BOX COMPLETE A (Aluminium Rails)

53990RC - ADV LRS COMPONENTS STERI-BOX RADIOLUCENT COMPLETE A (Radiolucent Rails)

*Please refer to the specific LRS ADV Knee Hinge Operative Technique (LR-1001-OPT).


**53991 - ADV LRS Components Steri-Box Empty B**

Can accommodate:

Part No.	Component Description
1x10052	Torbay-Garches Clamp
1x90006	ProCallus Straight Clamp
1x90007	ProCallus T-Clamp
1x53541	ADV Ball-Joint Coupling
1x14148	ADV Acute Derotation Template**
1x14332	ADV Acute Correction Garches Template**
1x14333	ADV Acute Correction Straight Template**
1x14334	ADV Acute Correction T-Template**
1x14237	ADV Acute Derotation Arc 100mm**

** For adult and paediatric applications.

53991C - ADV LRS COMPONENTS STERI-BOX COMPLETE B

**ADV LRS KITS****Consisting of:**

53510	1 ADV LRS Rail 400mm (53560), 2 ADV Straight Clamps (53530), 1 ADV Inclination Clamp (53580), 1 Compression Distraction Clicker (50008), 1 Compression Distraction Clicker (50009), 1 Allen Wrench 5 mm (30017), 1 Allen Wrench 6 mm (10017)
53510R	Same as above with Radiolucent Rail instead of Aluminium Rail
53500	1 ADV LRS Rail 300mm (53550), 3 ADV Straight Clamps (53530), 1 Compression Distraction Clicker (50008), 1 Compression Distraction Clicker (50009), 1 Allen Wrench 5 mm (30017), 1 Allen Wrench 6 mm (10017)
53500R	Same as above with Radiolucent Rail instead of Aluminium Rail
53515	1 ADV LRS Rail 200mm (53545), 2 ADV Straight Clamps (53530), 1 Compression Distraction Clicker (50009), 1 Allen Wrench 5 mm (30017), 1 Allen Wrench 6 mm (10017)
53515R	Same as above with Radiolucent Rail instead of Aluminium Rail

53548 LRS ADVanced Sandwich Clamp, height: 8 mm (This component is not included within the Steribox A: 53590C)

53547 LRS ADVanced Sandwich Clamp, height: 15 mm (This component is not included within the Steribox A: 53590C)

For Cleaning, Disinfection, Sterilisation and Maintenance of Instrumentation please refer to PQ ISP.

LENGTHENING AND BONE LOSS

General Principles

Multilevel Surgery

The Limb Reconstruction System was designed primarily for segmental (multilevel) surgery. The three main indications are bone loss, deformity and shortening which may occur singly or in combination. The system provides for correction in these situations through the techniques of lengthening, bone transport, and compression-distraction, whether performed at one level or as multifocal surgery. This is exemplified in the summary chart below (Fig. 1)

Callotasis

Most of these protocols use the technique of distraction histogenesis to form new bone. This was originally developed by Ilizarov and his colleagues using circular external fixation. De Bastiani and colleagues modified this for use with monolateral external fixation and introduced the term 'callotasis' to describe the controlled distraction of early callus to form new bone. The principle can be used to fill bone defects (bone transport) or to lengthen bone to correct limb length discrepancy or severe short stature. A particular application of this technique, called hemicallotasis, can be used to create an opening wedge gradually in order to correct a deformity.

The early experiences of lengthening with monolateral telescopic lengtheners were described in the classic papers from the Verona school in the late 1980's.^{1,2,3,9,10} Although much more stable than a fixator with ball joints, this had the disadvantage of becoming less stable as the fixator was distracted. The Limb Reconstruction Rail solved this problem by allowing clamps to be positioned close together, with three or even four clamps attached to the same bone segment.

The principles of callotasis are as follows:

1. Stable external fixation with an equal working length in each segment of the bone.
2. Osteotomy carried out with a precise, minimally invasive technique. Soft tissue releases are carried out if required.
3. The periosteum must be preserved and repaired whenever possible. The vascular supply to the periosteum is very important for good regenerate formation. (Kojimoto et al^{15,16})
4. The osteotomy should, where possible, be carried out in the metaphysis.
5. The technique of corticotomy described by Ilizarov was found to be unnecessary: a simpler but also

minimally invasive osteotomy produced similar results.

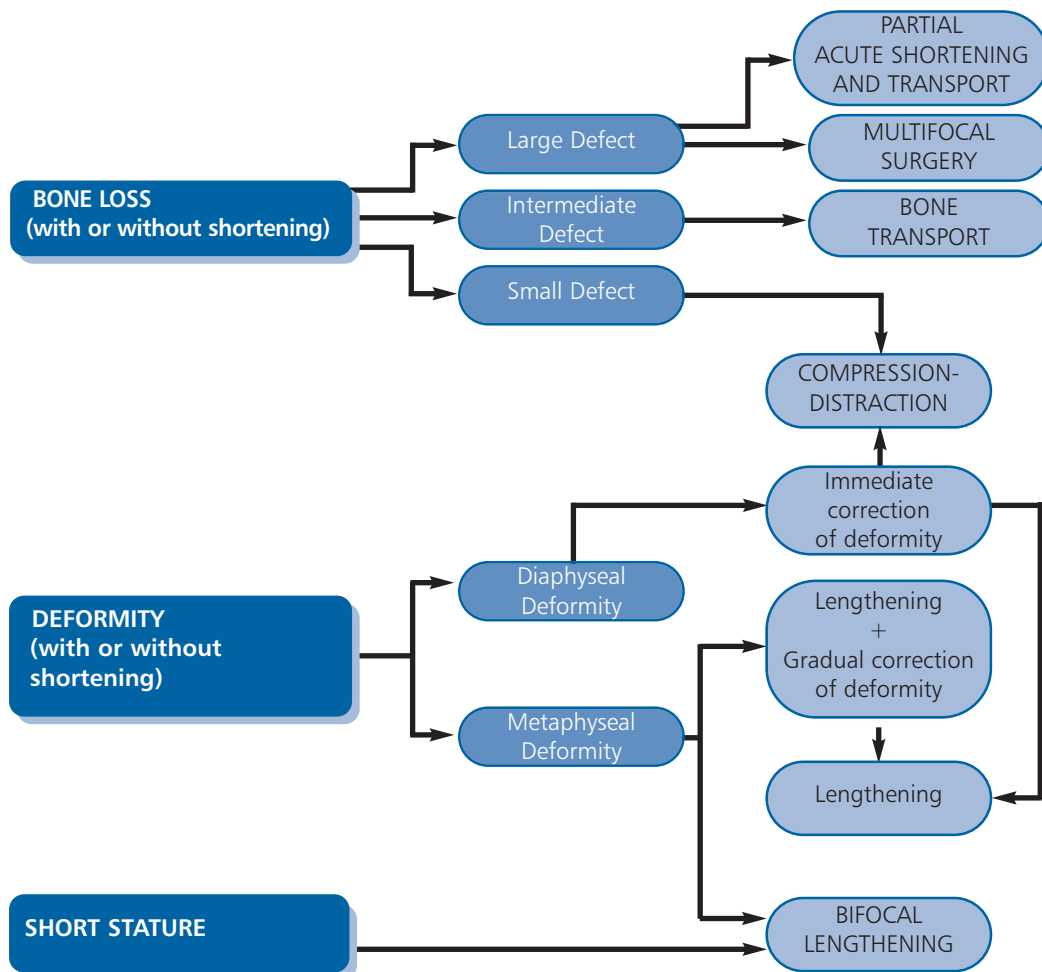
6. A waiting period of 7-14 days before distraction was begun, with the osteotomy closed and the fixator locked.
7. Distraction of 0.75-1mm a day, depending on the bone (1mm in the femur, tibia and humerus but slower in the forearm or metatarsal/metacarpals) or level of bone (slower in diaphyseal osteotomies) divided, through a quarter turn of the compression-distraction hexagon several times a day. Each quarter turn advanced the lengthening by 0.25mm.
8. Careful monitoring of the quality of the callus formation throughout lengthening, and altering the rate of distraction as required
9. Careful attention to maintaining the mobility of the joints each side of the lengthening segment.
10. At the end of the distraction phase, the fixator is locked firmly and weightbearing is increased. This is the neutralisation phase.
11. The new bone, called the regenerate column, gradually develops under the influence of stability and the stimulus of weight-bearing. X-ray appearances document the progression from longitudinal streaks of bone (microcolumns) to subsequent differentiation into cortices and a recanalisation of a medulla.
12. When the new bone is strong enough, the locking nut is loosened to allow complete axial loading, while the fixator maintains the alignment of the bone fragments. This process was called dynamisation.
13. The external fixator is gradually removed, often one screw at a time to increase the degree of load bearing through the new bone, as the regenerate consolidates.
14. Final removal of the fixator is considered when three out of four cortices are visible in two orthogonal X-ray views.
15. The process of lengthening is thus recognised by four different phases: Waiting Period; Distraction; Neutralisation, and finally Dynamisation.^{4-8,11-14,18-24}

The techniques of lengthening and bone transport were refined by surgeons from Europe, Japan and North America over the subsequent decade. The first papers on the use of the LRS rail were published in the early 1990's, and described the use of bifocal techniques for larger amounts of lengthening, or for angular correction and lengthening at different sites. Donnan et al reviewed children who had lengthening

and deformity correction and concluded that lengthening should not be carried out at a site where more than 30 degrees of acute correction had been produced.³⁰ Pouliquen and colleagues demonstrated the value of early micromovement applied to the regenerate with the DynaRing cushion.¹⁷ Two papers from Sheffield, UK reviewed the use of monolateral fixation in the treatment of nonunions and defined new management principles.^{42,44} There were also many reports describing the use of bone transport to close long bone defects.²⁵⁻⁵⁷

In these cases, the LRS rail was used with bifocal techniques to restore bony continuity in bone defects caused by trauma or infection. More rapid union at the docking site is obtained if it is formally treated as a non union when the original defect was more than 3 cm in the tibia or 5 cm in the femur.

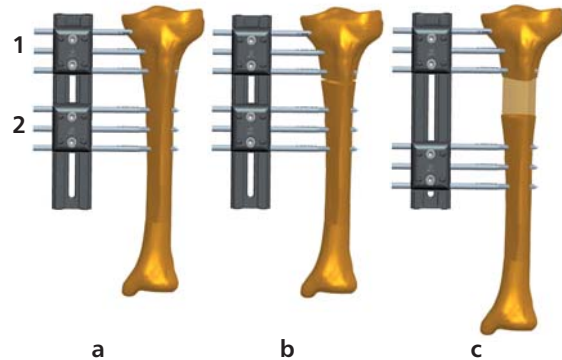
Fig.1 Multilevel Surgery: the options for treatment with the LRS System



Lengthening

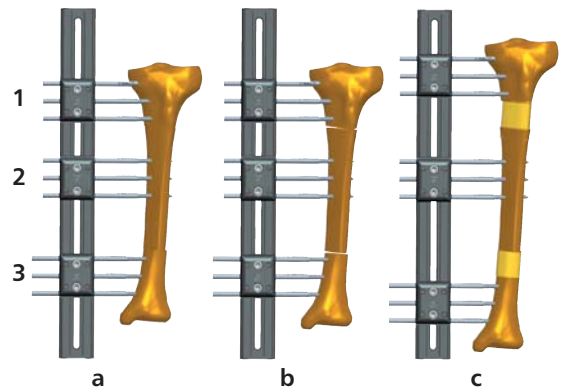
Monofocal Lengthening

- a) Limb Reconstruction System in place.
- b) Proximal metaphyseal osteotomy.
- c) Distraction (lengthening) with clamp 1 locked to rail and clamp 2 unlocked enabling distal movement along rail.



Bifocal Lengthening

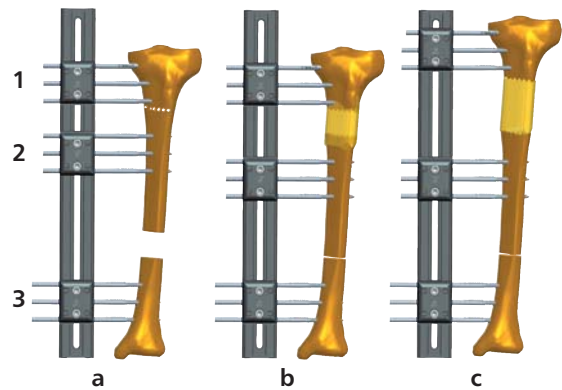
- a) For marked length discrepancy in bone or for short stature. Limb Reconstruction System in place.
- b) Proximal metaphyseal osteotomy between clamps 1 and 2 and distal metaphyseal osteotomy between clamps 2 and 3.
- c) Simultaneous lengthening at each osteotomy site. Clamp 2 is locked to the rail leaving clamps 1 and 3 free to move along the rail in opposite directions.



Bone loss

Intermediate Size Defect: Bone Transport

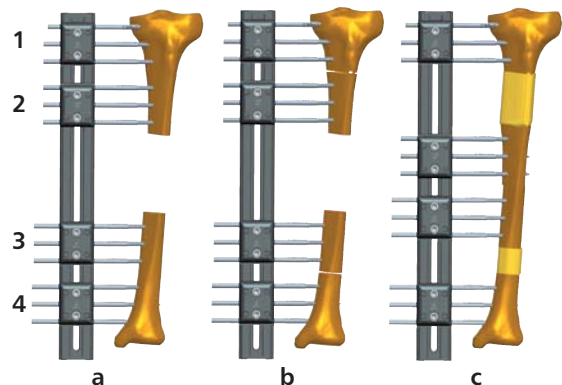
- a) Intermediate Size Distal Defect with Shortening. LRS with 3 clamps applied.
- b) Proximal metaphyseal osteotomy between clamp 1 and 2, followed by transport with clamp 1 and 3 locked to the rail and clamp 2 moving distally.
- c) Lengthening to restore original limb length. Clamp 2 and 3 locked to rail and clamp 1 moving proximally.



Large Defect: Multifocal Surgery and transport

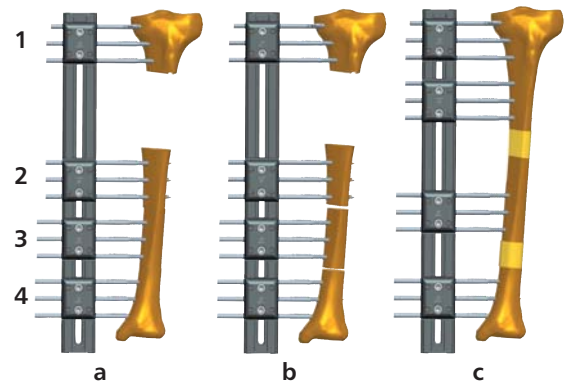
Central Defect

- a) Large central bony defect and Limb Reconstruction System in place.
- b) Proximal and distal metaphyseal osteotomies.
- c) Simultaneous proximal and distal transport with clamps 1 and 4 locked to rail and clamp 2 moving distally and clamp 3 proximally until segments meet at the docking site.



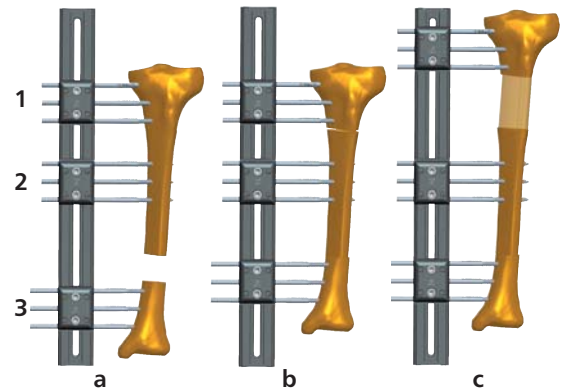
Peripheral Defect

- a) Large peripheral bony defect and Limb Reconstruction System in place.
- b) Two osteotomies performed in longer bone fragment.
- c) Simultaneous proximal transport with clamps 1 and 4 locked to rail and clamps 2 and 3 moving proximally until leading segment arrives at the docking site.



Small Defect: Compression-Distraktion

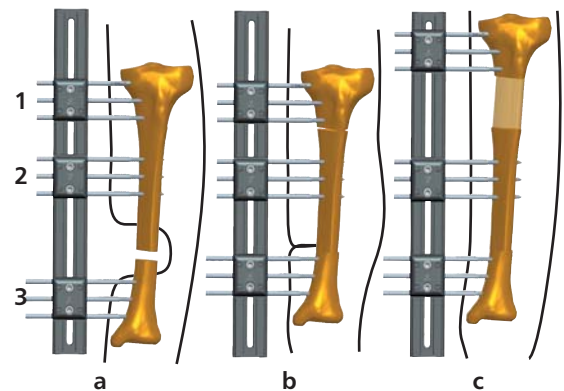
- a) Small distal bone defect and Limb Reconstruction System in place.
- b) Acute compression between clamps 2 and 3 to close defect. Proximal osteotomy performed between clamps 1 and 2.
- c) With clamps 2 and 3 locked to rail to maintain compression, clamp 1 is moved proximally to restore original limb length by Callotasis.



Fracture associated with major soft tissue defects

Compression-Distraktion

- a) Fracture with major soft tissue defect and exposed bone.
- b) Debridement and resection of sufficient bone to allow soft tissue closure with distal stabilisation after acute compression. Simultaneous or delayed proximal osteotomy.
- c) Progressive proximal distraction (lengthening) to restore original bone length.




Lengthening

Femur

Two straight clamps are used, each with three cortical screws. The rail is applied to the lateral aspect of the femur.

Place the most proximal screw first in the intertrochanteric area of the proximal femur or distal to the trochanteric apophysis if still open. Insert the screw across the centre of the antero-posterior width of the bone and at right angles to the femoral axis. Place this screw in the most proximal seat of the proximal clamp. This should bring the rail to be parallel to the axis of the femur.

With each screw insertion, locate the optimum position first by using the trocar through the screw guide, then replace the trocar with a drill guide and drill the bone with a 4.8 mm drill bit. Use a drill-stop to avoid overdrilling the opposite cortex thereby preventing any soft tissue damage.




The second screw is placed in the most distal seat of the distal clamp. Before committing to this position by drilling, it is advisable to confirm that all other remaining screws will engage adequately through both cortices of the femur.

This can be achieved with a K-wire, by manually probing percutaneously checking that bone purchase through all the planned screw holes in the clamps is sufficient.

Insert remaining screws using screw guides.

Remove the screw guides and tighten the clamp covers with 5 mm Allen key.


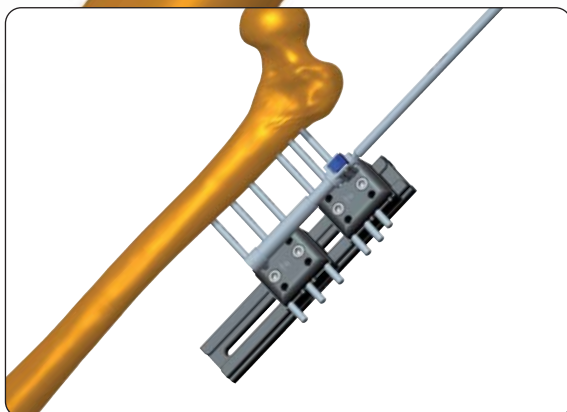


Incision for osteotomy

Expose the bone via an anterior incision, dividing the deep fascia and proceeding between the rectus femoris medially and the vastus lateralis laterally, separating the fibres of vastus intermedius to expose the periosteum. The periosteum must be incised longitudinally and carefully detached from the cortex.

Perform the osteotomy just below the lesser trochanter (not more distally) at 1,5 cm from the distal screw of the proximal clamp. This can be achieved percutaneously with pre drilling of the cortex using a 3.2 mm drill bit and a drill guide. The osteotomy is then completed by connecting the drill holes with an osteotome.

Mount the CD-unit, unlock one of the clamps on the rail and distract by turning anticlockwise clamps.



Tibia


Six cortical screws are used, three proximal and three distal. The rail is applied in any plane between the medial and anterior aspects of the tibia.

Fix the fibula to the tibia with a screw to prevent displacement of the malleolus during lengthening. Perform a fibular osteotomy.

Place the most proximal screw first about 2 cm below the joint using the first (or second) most proximal seat of the clamp.

Again, check that bone purchase is possible in all screwholes, using a K-wire manually.

Place the second screw in the central screw seat of the distal clamp. This will ensure correct positioning of the remaining screws. Ensure that these screws are inserted perpendicular to the tibial axis.


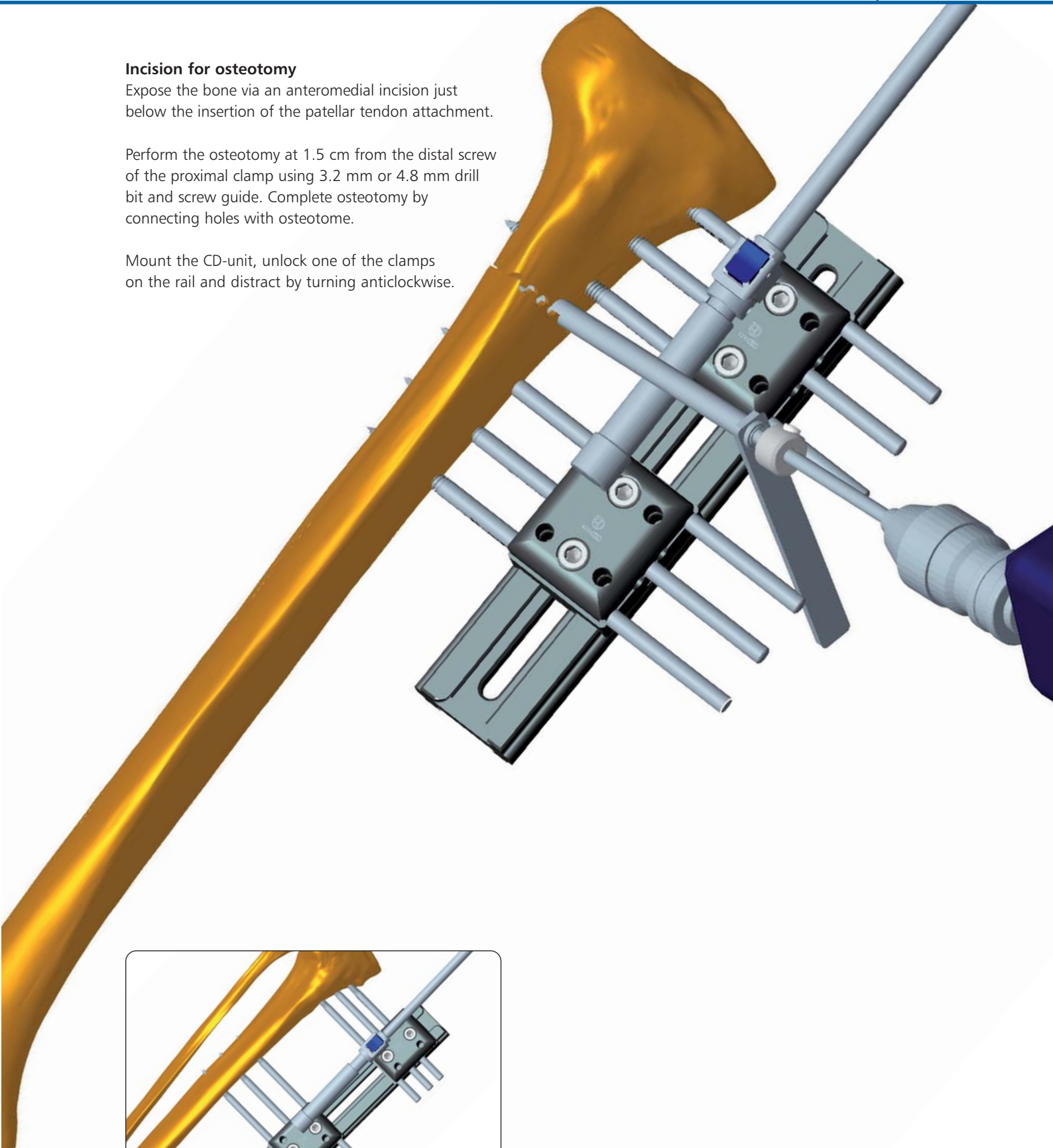


Incision for osteotomy

Expose the bone via an anteromedial incision just below the insertion of the patellar tendon attachment.

Perform the osteotomy at 1.5 cm from the distal screw of the proximal clamp using 3.2 mm or 4.8 mm drill bit and screw guide. Complete osteotomy by connecting holes with osteotome.

Mount the CD-unit, unlock one of the clamps on the rail and distract by turning anticlockwise.




Post-Operative Management

The patient should commence weightbearing as tolerated with crutches as soon as is feasible after the operation. The waiting period before starting distraction is normally ten days in adults and about seven days in children and in patients with anticipated rapid ossification (i.e. achondroplastic patients). The rate of distraction should be 1 mm daily, achieved by four counter-clockwise quarter turns daily of the compression- distraction unit. The rate of distraction can be temporarily increased where rapid ossification is observed or reduced if ossification is slow or the patient complains of excessive pain or muscle spasm. After the first week of distraction, an X-ray or an ultrasound is performed to ensure that distraction is taking place correctly. X-rays are then taken regularly to monitor progress and the callotasis segment. If the density of the lengthened portion is poor but uniform, lengthening is stopped for one or two weeks. If the callus appears irregular and scanty, the segment is then compressed at the same rate for 5-10mm, whereafter cautious lengthening is resumed at a slower rate.

At the end of lengthening, the X-ray should ideally demonstrate a uniform callus. The clamp locking nut is now tightened to maintain the new bone length and in stable neutralisation. The compression-distraction unit is no longer required and is removed at this stage to make the assembly lighter. The duration of the neutralization period will vary depending

upon the amount of lengthening achieved, the aetiology of the condition, and the age of the patient. With radiographic evidence of a uniformly dense and opaque callotasis segment, dynamisation is commenced by loosening the clamp locking nut.

Alternatively, a Dyna-Ring can be inserted to prevent unwanted collapse of the segment and to promote micro movement. During dynamisation, weightbearing on the lengthened limb is allowed as tolerated. The lengthener is removed once radiographic and clinical assessment indicate good bony consolidation. The screws, however can be left in place for several days, allowing for temporary removal of the fixator during mobilisation and weight bearing, with re-application of the fixator at night. The screws are removed when further x-rays confirm the absence of regenerate deformity or fracture. Radiological and clinical review should be carried out at regular intervals after fixator removal and protected weightbearing for a few weeks is advisable.



Bone Loss

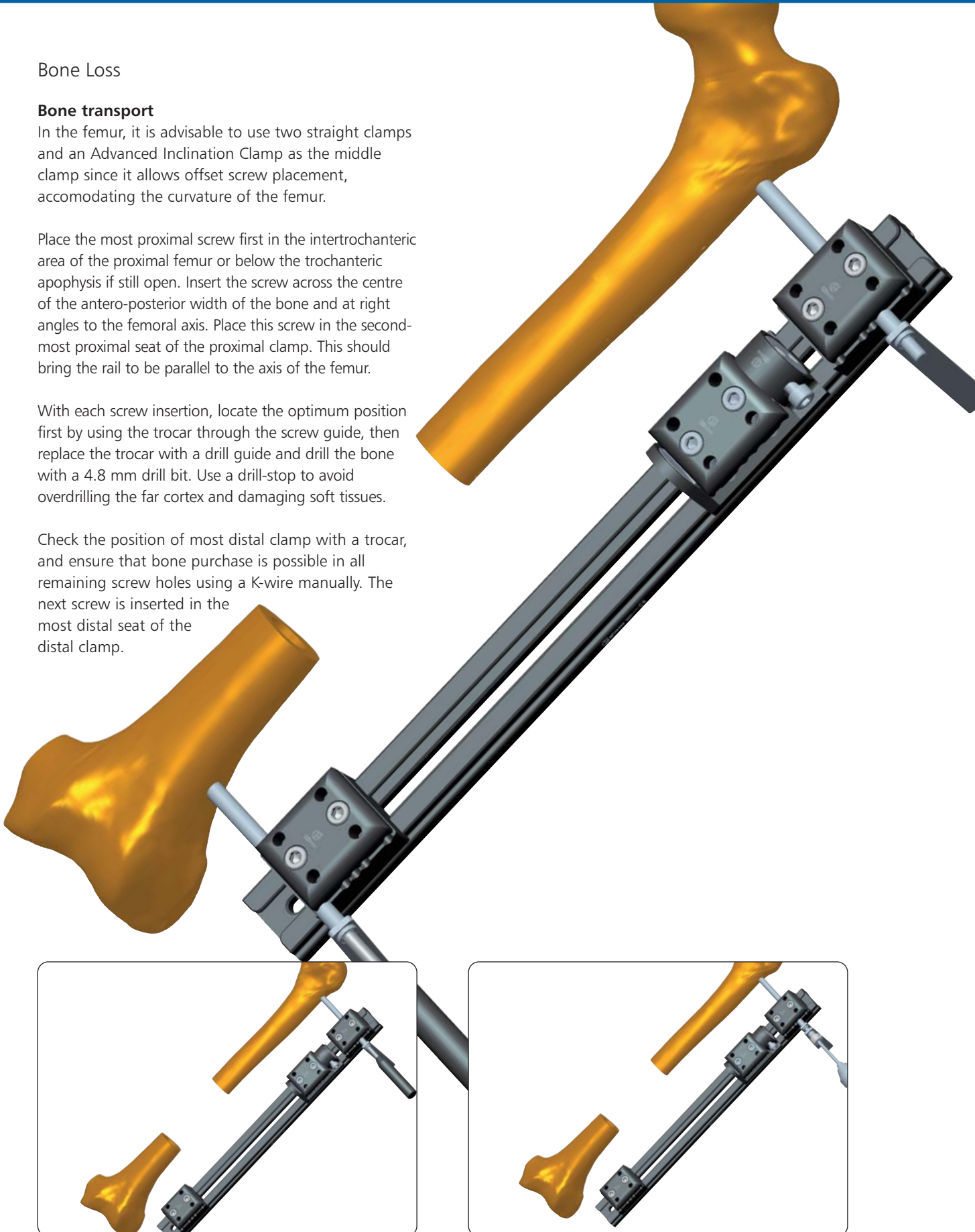
Bone transport

In the femur, it is advisable to use two straight clamps and an Advanced Inclination Clamp as the middle clamp since it allows offset screw placement, accommodating the curvature of the femur.

Place the most proximal screw first in the intertrochanteric area of the proximal femur or below the trochanteric apophysis if still open. Insert the screw across the centre of the antero-posterior width of the bone and at right angles to the femoral axis. Place this screw in the second-most proximal seat of the proximal clamp. This should bring the rail to be parallel to the axis of the femur.

With each screw insertion, locate the optimum position first by using the trocar through the screw guide, then replace the trocar with a drill guide and drill the bone with a 4.8 mm drill bit. Use a drill-stop to avoid overdrilling the far cortex and damaging soft tissues.

Check the position of most distal clamp with a trocar, and ensure that bone purchase is possible in all remaining screw holes using a K-wire manually. The next screw is inserted in the most distal seat of the distal clamp.



After locking the external clamps to the rail, check the position of central screws in the Advanced Inclusion Clamp. Loosen the appropriate locking nut to find the correct position in the centre of the bone.

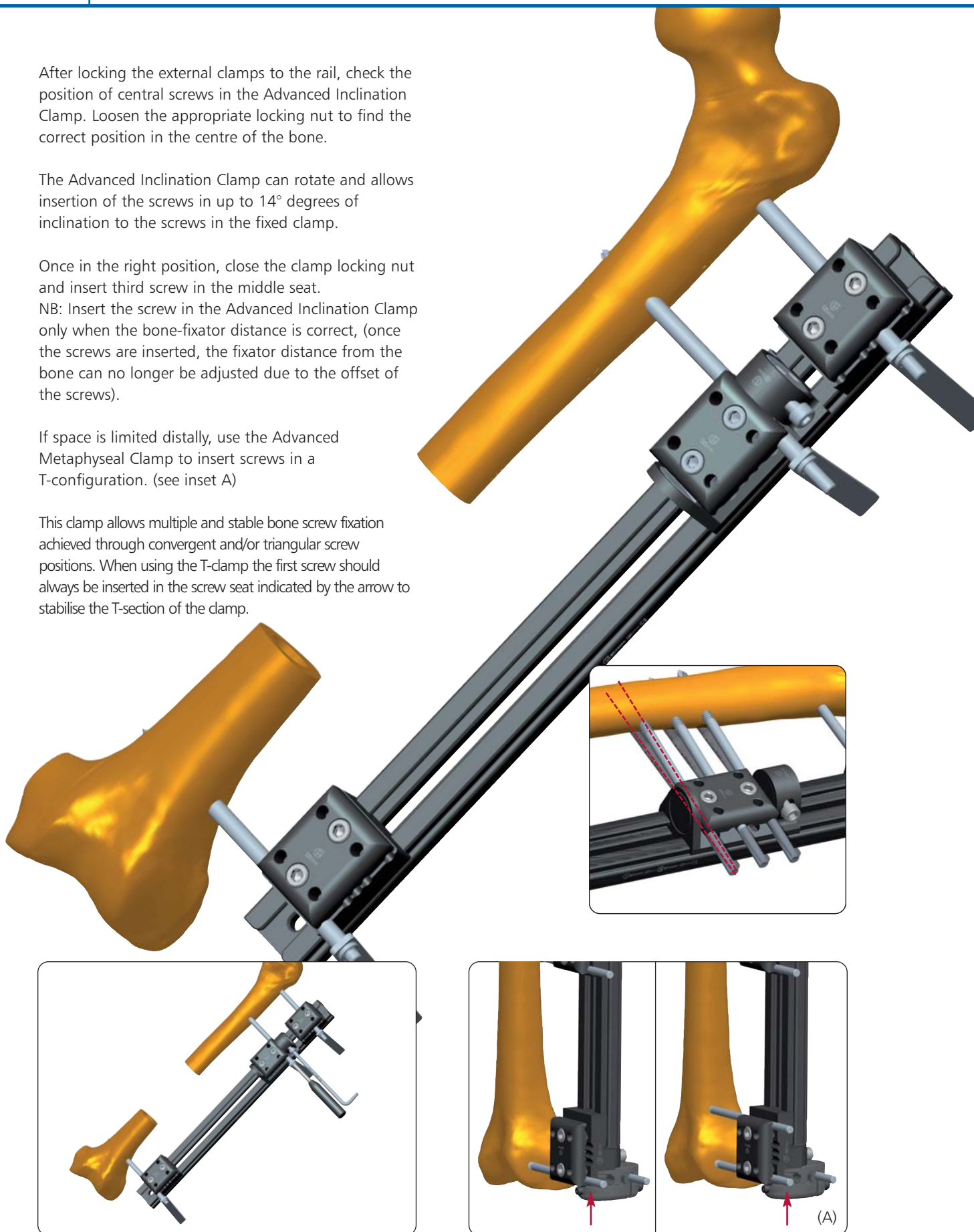
The Advanced Inclusion Clamp can rotate and allows insertion of the screws in up to 14° degrees of inclination to the screws in the fixed clamp.

Once in the right position, close the clamp locking nut and insert third screw in the middle seat.

NB: Insert the screw in the Advanced Inclusion Clamp only when the bone-fixator distance is correct, (once the screws are inserted, the fixator distance from the bone can no longer be adjusted due to the offset of the screws).

If space is limited distally, use the Advanced Metaphyseal Clamp to insert screws in a T-configuration. (see inset A)

This clamp allows multiple and stable bone screw fixation achieved through convergent and/or triangular screw positions. When using the T-clamp the first screw should always be inserted in the screw seat indicated by the arrow to stabilise the T-section of the clamp.



Insert the remaining screws, remove the screw guides and tighten clamps. With the central clamp loosened on the rail, position a CD-unit between proximal and central clamps and distract by turning anticlockwise. This creates tension between the 2 clamps and facilitates the osteotomy, which is performed just below the lesser trochanter, using a 3.2mm drill bit and screw guide and joining the drill holes with an osteotome. The osteotomy is best performed at this level, and not more distally, for ideal regenerate formation.



LRS ADVANCED SANDWICH CLAMP


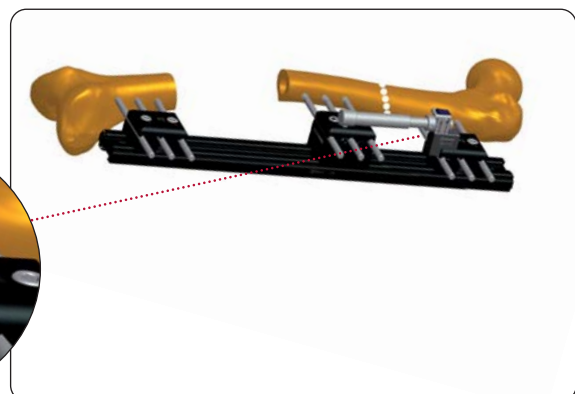


NOTE: The bone transport procedure could be performed either with the inclination clamp or with the sandwich clamp. Both of them ensure an appropriate screw insertion following the femur curvature.

The Sandwich Clamp is inserted between the base and the cover of a LRS ADV Straight Clamp to raise the position of screw insertion above the rail. Two models of Sandwich Clamp are available, depending on the displacement caused by the curvature of the femur: 8 mm (53548) and 15 mm (53547). This clamp is useful when the femur is curved, to allow placement of screws in the middle clamp in the center of the bone. It is used with longer clamp locking screws to allow fixation to the rail. Extension pieces (compression-distraction unit attachments) for the seating of the compression-distraction modules are provided.

With the assistant holding the distal clamp firmly in place, the surgeon checks that satisfactory screw insertions can be achieved at chosen sites in the proximal, distal and central clamps.

Once this has been achieved, the rail, is held in position while the screws are inserted using the standard technique.


The Compression-Distraction Unit Attachments are applied on the straight clamp cover and the Compression-Distraction Units inserted.



Post-Operative Management

Mobilisation should follow a course similar to that advocated for limb lengthening procedures. Active and passive mobilisation of adjacent joints should be encouraged early after surgery.

In bifocal lengthening, the main problem is tension generated in the soft tissues. Typically, in the femur, the range of movement at the knee is limited by transfixation of the tensor fascia lata and vastus lateralis by the bone screws. As a general rule, when screws are inserted through muscles close to joints, the muscles should be stretched fully before insertion. This is achieved in distal femoral screw placement with the knee in a fully flexed position. This problem does not occur in the proximal tibia where the bone is subcutaneous. Partial weightbearing is advisable soon after the operation. Splints may be used to support the knee or ankle to prevent contractures. The Ring Hinge may be used to connect a ring to the rail and allow cross knee stabilisation if required.




SEGMENTAL TRANSPORT

Transport should commence after 7-10 days at a rate of 0.25 mm four times a day. Any slack in the system should first be taken up by turning the compression-distraction unit counter-clockwise, with the middle and proximal clamps locked to the rail.

The middle clamp locking screw and washer should then be removed and the CD-unit nut turned anticlockwise, 90° four times a day. In practice, after opening an initial gap, the rate of transport may be adjusted to 0.75 mm or 1.25 mm a day according to the quality of the new bone as judged by its appearance on X-ray or ultrasound.

As transport proceeds, it is not uncommon to encounter some skin tension at the leading edge of the screws in the middle and to a lesser extent, in the proximal clamp. Additional skin and soft tissue releases may therefore be indicated.


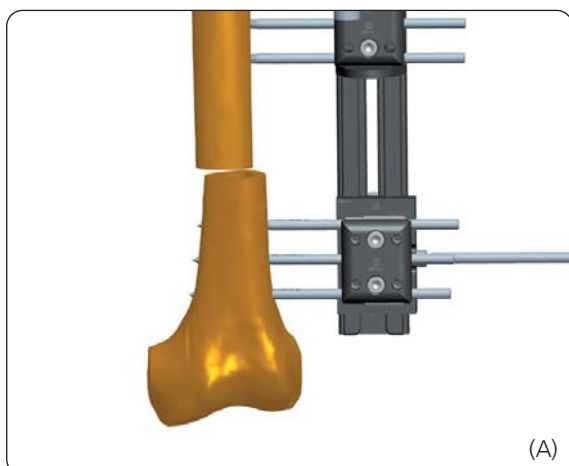


Towards the end of transport, X-ray evaluation may demonstrate suboptimal alignment between the advancing segment and the docking site. In the case of medial or lateral translation, correction may be achieved by loosening the middle clamp cover screws and adjusting the screw shanks in the clamp.

Alternatively, the Advanced Translation Clamp can be used as a substitute distally to gradually correct translation (see inset A).

THE DOCKING PROCEDURE

At the conclusion of transport, the defect will close with varying degrees of contact between the bone ends. The middle clamp should now be locked to the rail. If the compression is required, a compression-distraction unit is attached between the middle and distal clamps, the locking screw of the distal clamp is loosened or removed. Gentle compression is now applied by turning the compression-distraction unit screw clockwise. Depending upon the quality of the bone and the extent of contact achieved, various measures may be required to stimulate union. These will vary from the limited compression described above, to surgical debridement of fibrous tissue and localised decortication at the bone ends and compression, bone grafting for small defects, or extensive decortication of the entire docking area coupled with bone grafting for more serious defects. Consolidation of the docking site is monitored by means of serial radiographs. If transport has been carried out over a distance of 3 cm or more, the docking site should be viewed and managed like a delayed union once docking has occurred.



CORRECTION OF DEFORMITIES

General Principles

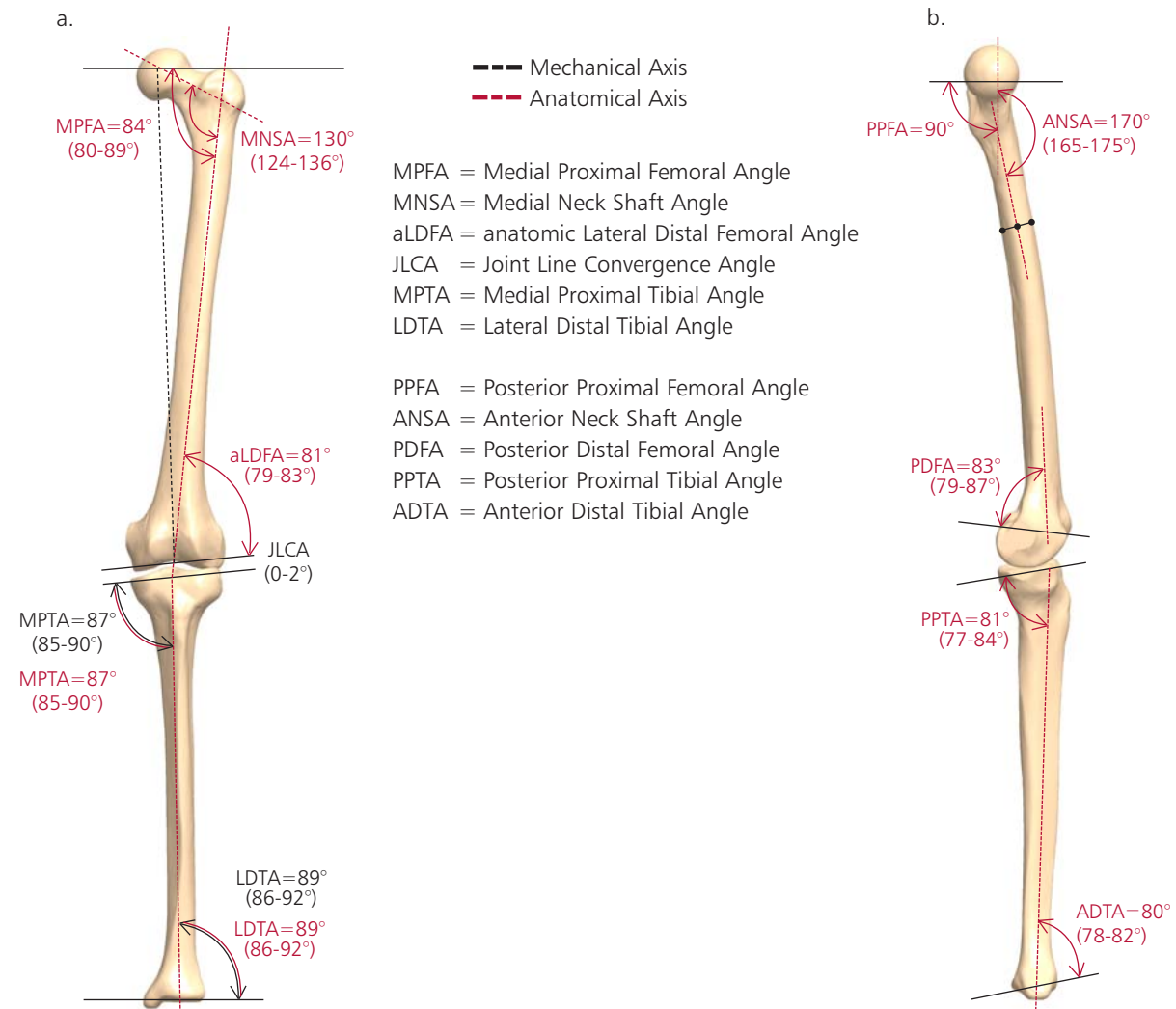
Deformity is a three dimensional problem. The correction of a deformity using the LRS, which is a monolateral, monoplanar fixator requires an understanding of the effects of adjustments or alterations in one plane on a three dimensional problem.

Mechanical Axis

This is the line of force of the axial mechanical load in static weightbearing. In the tibia, it coincides with the anatomical axis. In the femur, it extends from the center of rotation of the femoral head to the center of the knee joint. For the lower limb, it extends from the center of the femoral head to the centre of the tibio-talar joint, and should normally pass through near the center of the knee joint.

Anatomical Axis

The mid diaphyseal line of a long bone is the anatomical axis. In a deformed bone, each segment of the bone will have a separate anatomical axis and they will intersect.

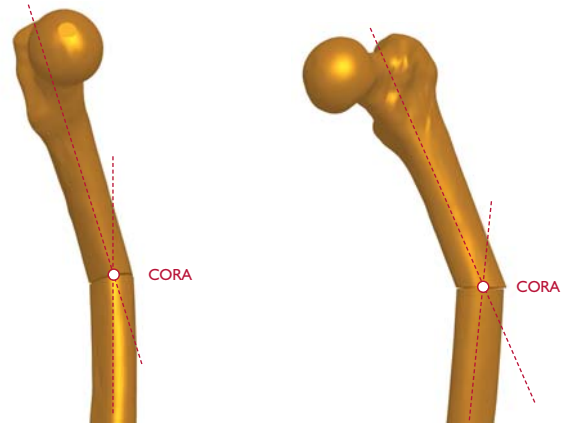


Paley and Tetsworth ^{58, 59}

A line drawn from the centre of the femoral head to the centre of the tibial plafond should pass through near the centre of the knee joint on a long leg view. If it does not, there is a Mechanical Axis Deviation (MAD).

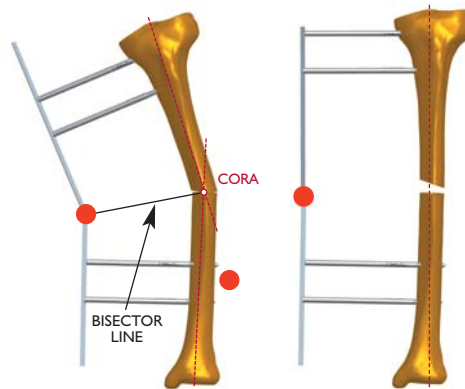
CORA (Center Of Rotation of Angulation)

This is the intersection of the axes of the two segments of a deformed bone. The position of the CORA is simple to determine when using the anatomical axes. Using the mechanical axis makes it slightly more complex, as the anatomical and mechanical axes of the femur are not parallel. In a deformed tibia, the anatomical axis on either side of the apex of the deformity is drawn along the center of the diaphysis. In a deformed femur, the mechanical axis of the proximal femoral segment is normally estimated to be a line passing through the center of the femoral head, at right angles to a line from the center of the head to the tip of the greater trochanter, whereas the axis of the distal segment can be obtained by extrapolating the axis of the tibia in a retrograde direction, unless there is a knee joint level deformity. Using the anatomical axis method of determining the CORA is the preferred and simpler option.



Bisector Line

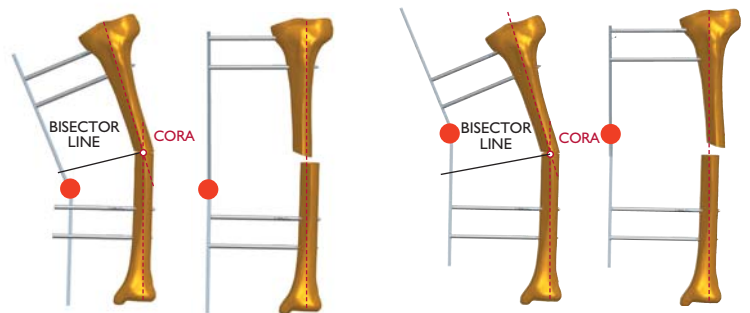
This is a line which divides equally the angle of intersection of the axes of the two segments of a deformed bone. The centre of rotation of the hinge of a monolateral gradual correction device should lie along this line to minimise translation during correction.



Hinge on CORA bisector line.
After correction there is no translation.

Translation

It is important to recognise when translation is a component of a deformity. When the position of the CORA does not coincide with the level of the apex of the deformed bone, the difference is due to translation being a component of the deformity. If the hinge of the monolateral correcting device is placed at the level of the apex of the deformity, correction will not remove the translation. However, if the hinge is placed on the bisector line of the CORA, correction of angulation and translation proceeds simultaneously.

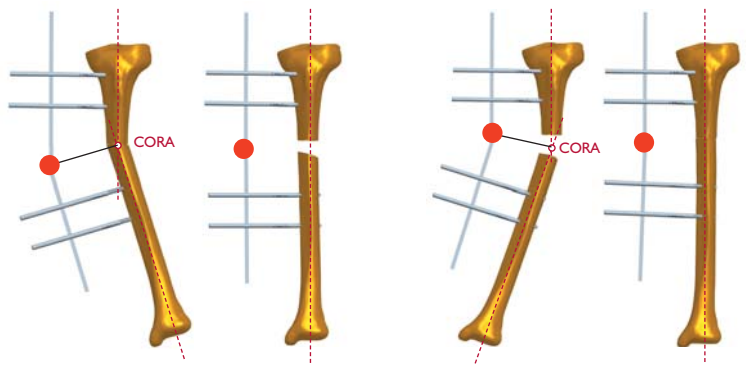


Hinge below CORA bisector line.

Hinge above CORA bisector line.

When monolateral fixation is used, the following points should be born in mind:

- I. In a deformity in which the fixator is placed on the convex side of the deformity, angular correction through the micrometric clamp will distract the osteotomy.
- II. Conversely, if the fixator is placed on the concave side of the deformity, compression will occur at the osteotomy. If a sufficient osteotomy gap is not present, the bone ends will jam and prevent further correction.



Pre-Operative Planning

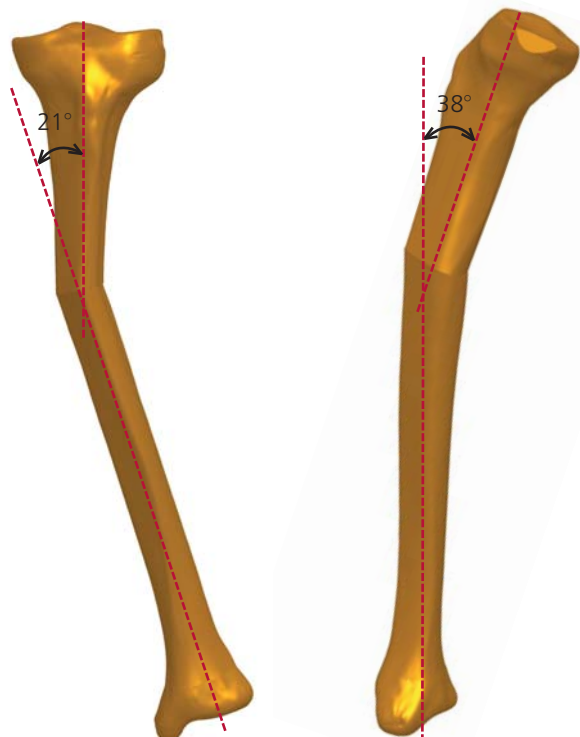
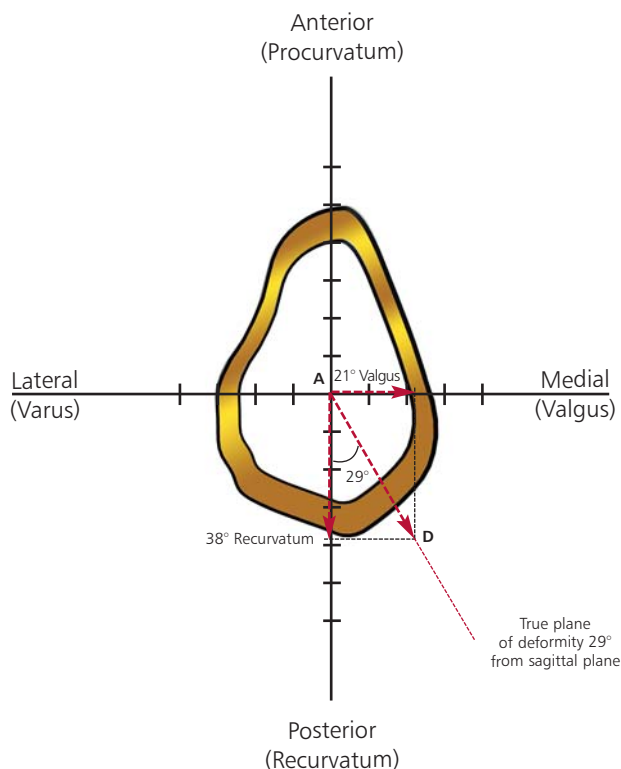
For the surgeon to define the goals of surgery precisely, it is essential that careful assessment of the deformity is carried out preoperatively with:

1. Accurately aligned AP and lateral X-rays, to define the angular deformities in both the sagittal and coronal planes.
2. Calculation, by the method described below of the true plane of the deformity
3. Careful assessment of any rotational deformity.
4. Assessment of any translation, as part of the deformity which requires correction.

Determining the true plane of the deformity: initial assessment of any lower limb deformity should include full length weightbearing AP x-ray of both legs to allow evaluation of the axis of the entire lower limb. The method by which the true plane of deformity (and hence the plane of correction) is derived is as follows. Accurately aligned AP and lateral X-ray views are taken. The angulation of the deformity in each view is measured with a goniometer.

Using graph paper, X and Y axes are marked with the center of the bone at the intersection (abscissa); anterior, posterior, medial and lateral positions are then indicated. The amount of the deformity, in degrees, is plotted on each axis; e.g. a deformity which measures 21° valgus on the AP x-

ray is marked along the x-axis in a medial direction - a simple way to remember this is to think of a valgus deformity as one with the apex pointing medially, and to mark the size on the graph paper in the medial direction. Similarly, a recurvatum deformity which measures 38° on the lateral x-ray is plotted in a posterior direction (recurvatum = apex posterior). Orthogonal lines are drawn from these points so that they intersect, and a line drawn from this intersection to the zero position (see figure below). This is the plane of the deformity. The deviation of this plane from the sagittal or coronal planes can be measured directly off the graph paper: if millimeter-square graph paper is used, and the scale adopted for plotting is one millimetre to one degree, then the length of the line (AD), in millimetres, connecting the abscissa to the intersection of the two orthogonal lines, is the size of the deformity in degrees, and the angle it subtends with either the coronal or sagittal planes locates the plane of deformity. In this example, it is 29° from the sagittal plane, or 61° from the coronal plane, lying in a posteromedial to anterolateral direction. Measurement of the length of the line AD will provide the amount of correction required, in this case 43°. If a radiograph is now taken with the x-ray plate lying parallel to this true plane of the deformity, it would demonstrate a maximum deformity measuring 43° as calculated by this vector method.



The Plane Of Deformity

Angular deformity can exist in any plane. If present in the coronal plane, it will be seen in profile on an AP X-ray, whereas the lateral view will show a 'straight' bone. Similarly an angular deformity in the sagittal plane is seen only in the lateral view. If the angulation lies in a plane neither coronal nor sagittal, i.e. an oblique plane, then some deformity is visible on both AP and lateral X-rays. It is a common misconception to think of two deformities, when in reality there is only one, lying oblique to the standard coronal and sagittal planes.

This understanding of angular deformities is central to the use of the LRS with the micrometric clamps, because correction through the clamps must occur in the plane of the deformity. In the simplest example, a valgus or varus deformity is corrected with the adjustments made in the coronal plane.

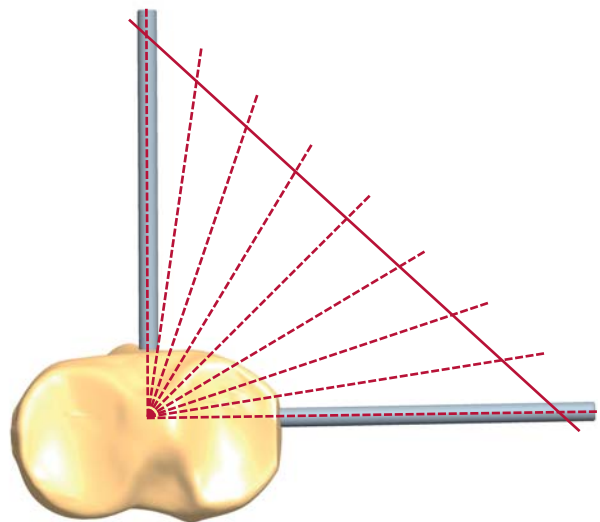
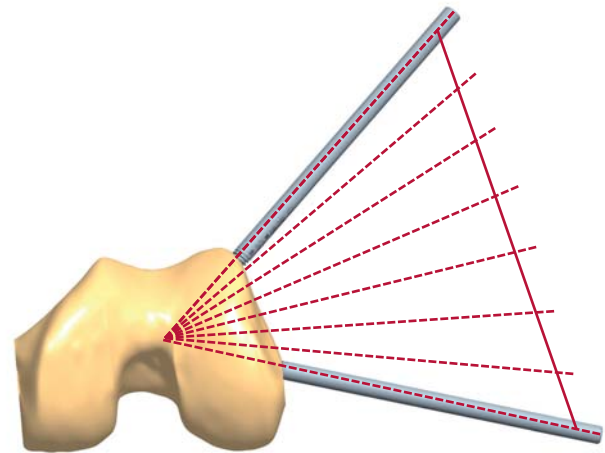
The Advanced Micrometric Swivelling and Advanced Multiplanar Clamps act by adjustments being made around a center of rotation (hinge). A compression-distraction unit (or "distractor") is used to drive the correction.

With the Micrometric Swivelling Clamp, the center of rotation functions in the same plane as that of the bone screws. For the clamp to work correctly, the screws (and hence the plane of rotation) must lie in the plane of the deformity, and therefore the LRS rail must be applied in the plane of the deformity. So, in the case of a varus or valgus deformity the LRS is applied in the coronal plane, and for a procurvatum or recurvatum deformity in the sagittal plane.

Note that sagittal plane application is possible in the tibia but not in the femur; therefore angular correction with the Micrometric Swivelling Clamp is only possible when the plane of deformity corresponds to a safe corridor for screw insertion. The following figure gives an indication of the possible planes of screw insertion in the femur and the tibia.

The Advanced Multiplanar Clamp overcomes this restriction, enabling the surgeon to deal with angular deformities in planes which do not correspond to a safe corridor for the bone screws. This, like the swivelling clamp, also has a center of rotation, but its plane of action can be altered independently of the plane of the bone screws. The central part of the body containing the hinge is called the angulator and can rotate. Any angular deformity can therefore be corrected.

It is possible with the multiplanar clamp that the angle of required correction will be at 90° to that of the bone screws. This situation would arise when the bone screws are in the coronal plane, but the deformity is solely in the sagittal plane. In this case correction will not produce compression or distraction.



Advanced Micrometric Swivelling Clamp and Advanced Translation-Angulation Clamp

With these clamps the plane of correction will be in the plane of the bone screws. They should only be used, therefore, when the plane of required correction is a suitable one for screw insertion. These clamps can be used either to correct a deformity intra-operatively, or to make a correction post-operatively by callus manipulation. Screws are inserted in the plane of the desired correction. The hinge on the clamp should be placed as close as possible to the level of the planned osteotomy. In view of the fact that the hinge will not coincide with the CORA or its bisector, a translational effect may be anticipated during the correction. This potential problem can be addressed as described below.

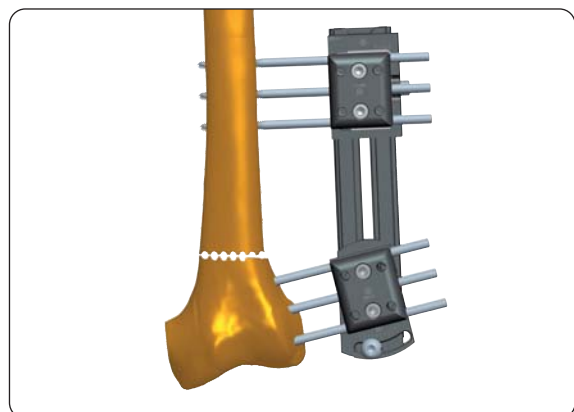
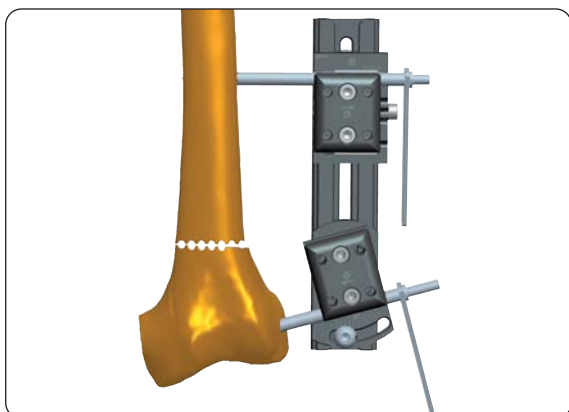
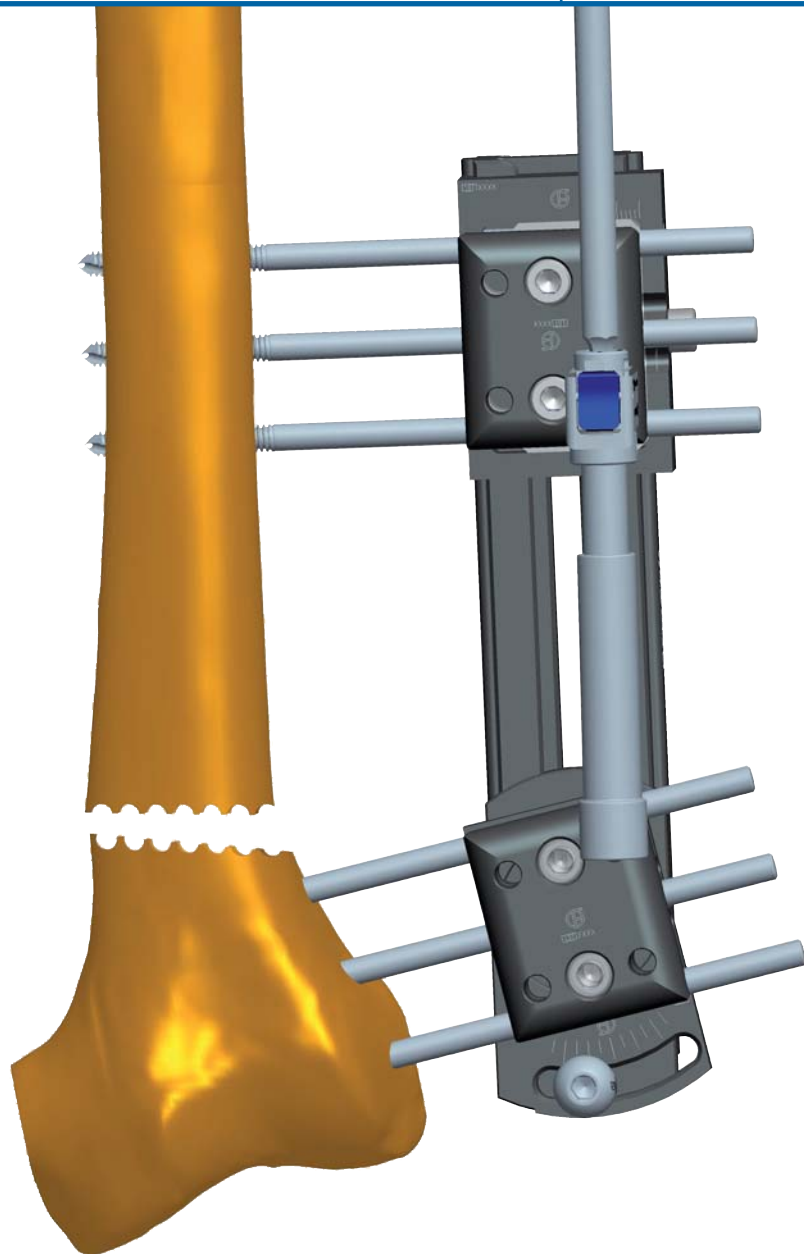
Use of the ADV Micrometric Swivelling Clamp and ADV Translation Clamp

Use the Advanced Micrometric Swivelling Clamp together with the translation clamp. When applying the latter, the translation screw should be set so that the maximum extent of translation in the desired direction (as indicated through pre-operative planning) may be achieved.

The first bone screw is inserted in the normal way through a screw guide mounted in the micrometric swivelling clamp which has been previously set to the desired angle. The second screw is inserted in the translation clamp.

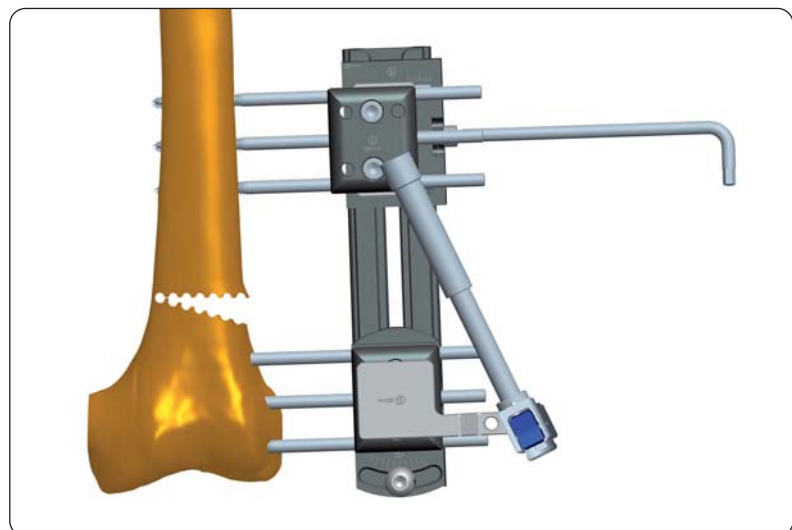
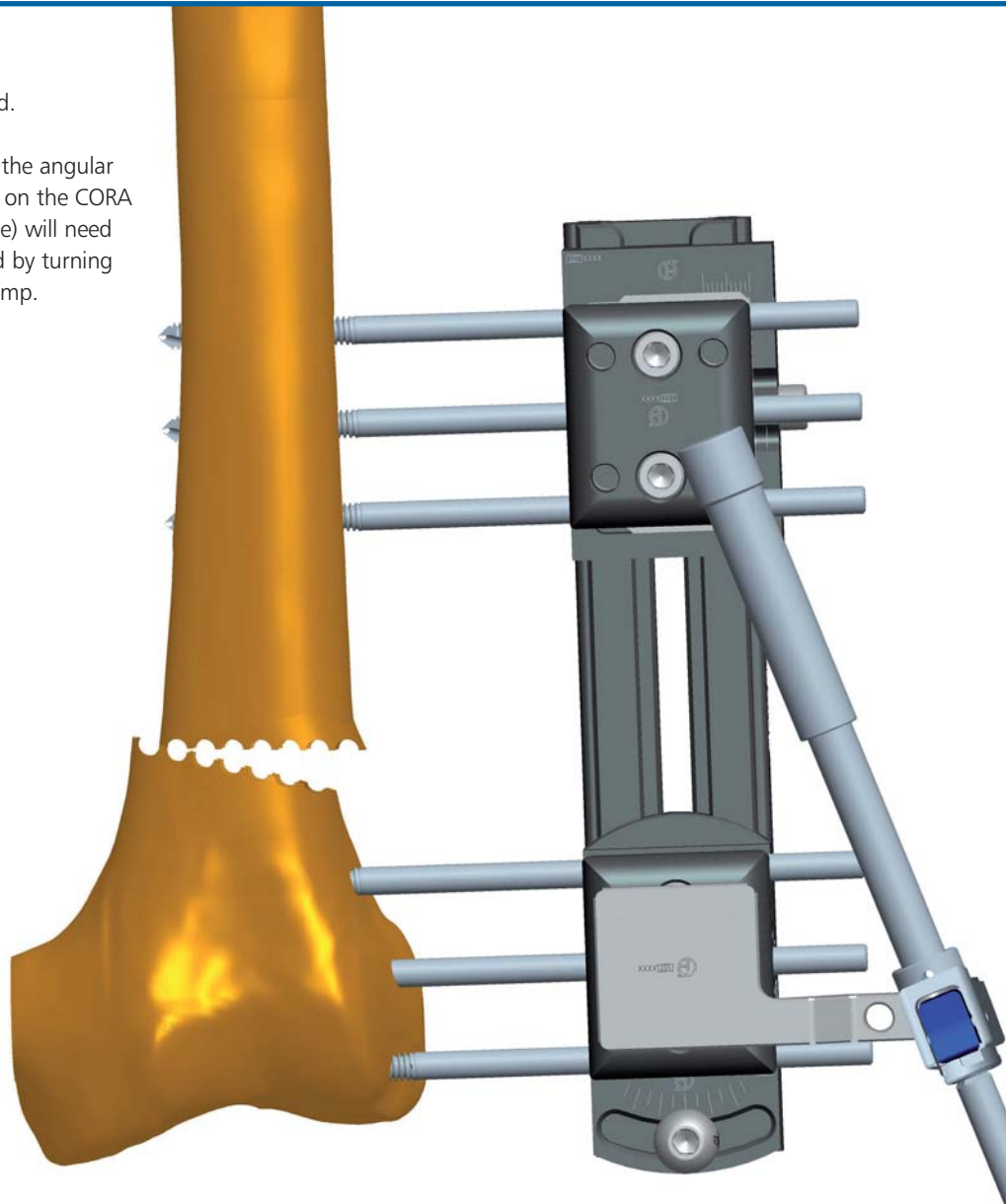
When the remaining bone screws have been inserted, an osteotomy is performed, at least 15 mm from the nearest bone screw, but as close to the hinge of the clamp as possible.

If the fixator is on the concave side of the deformity, as the correction occurs there will be shortening of the bone segment. In this case, a CD-unit can initially be used to distract the osteotomy.



The angular deformity is then corrected.

Translation which occurs as a result of the angular correction through a hinge not placed on the CORA or its bisector (as may occur in this case) will need to be addressed. Correction is achieved by turning the locking screw in the translation clamp.



Use of the ADV Micrometric Translation-Angulation Clamp

Use the translation-angulation clamp together with a straight clamp. When applying the former, the translation screw should be set so that the maximum extent of translation in the desired direction (as indicated through pre-operative planning) may be achieved.

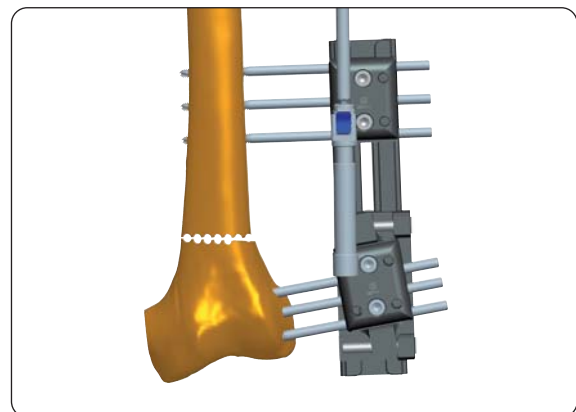
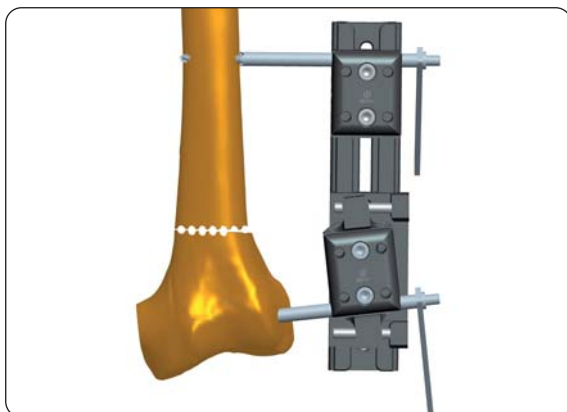
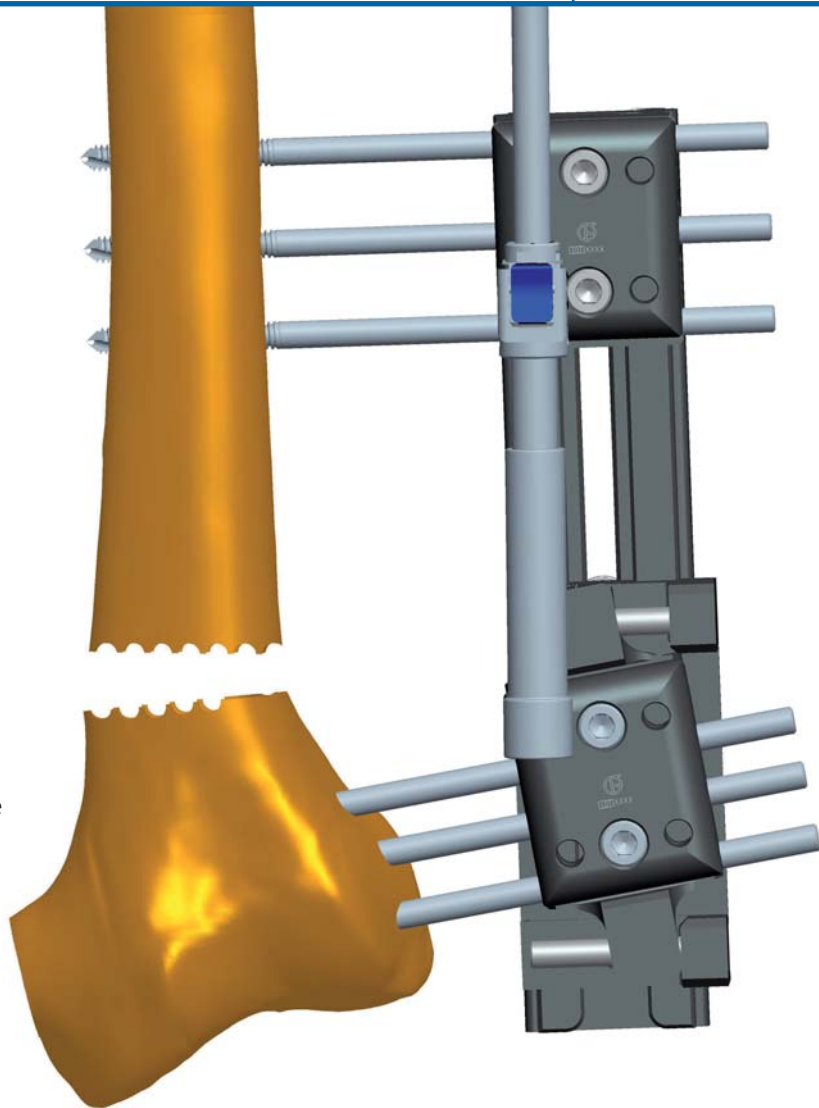
N.B. When inserting bone screws in the translation-angulation clamp attention should be paid that they do not interfere with its rotational movement. It is therefore advisable to insert them in positions 1, 2 and 4 in the clamp.

The first bone screw is inserted through a screw guide mounted in the translation-angulation clamp which has been previously set to the desired angle. The second screw is inserted in the straight clamp.

When the remaining bone screws have been inserted, an osteotomy is performed, at least 15 mm from the nearest bone screw, but as close to the level of the hinge of the clamp as possible.

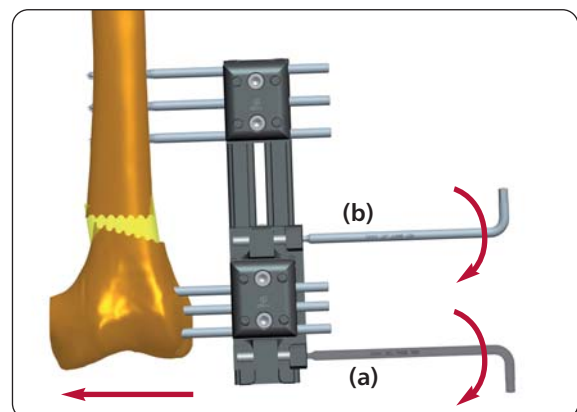
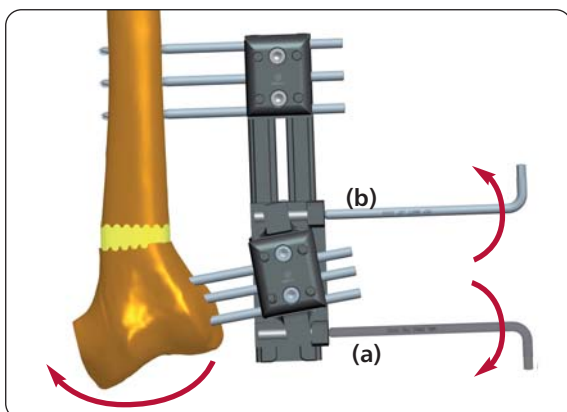
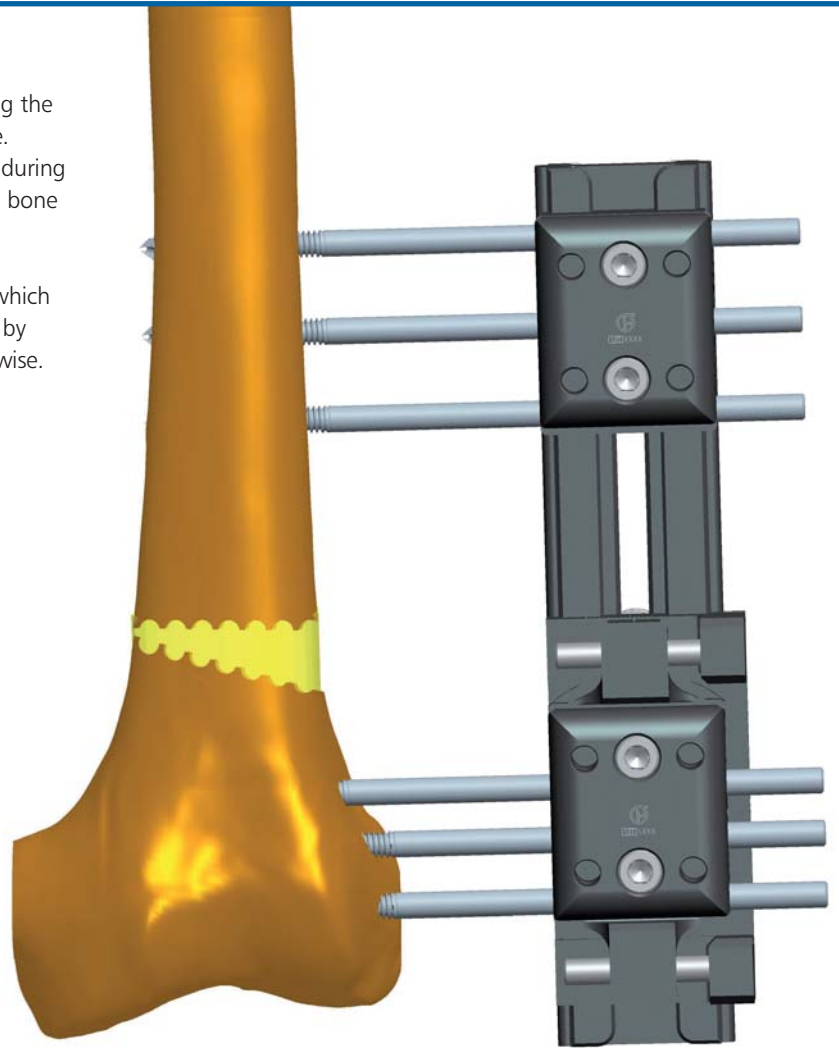
If the fixator is on the concave side of the deformity, there will be shortening as angular correction proceeds. To prevent potential jamming of the bone segments and cessation of any further angular correction, a CD unit should be used to initially distract the osteotomy site. It is important to first unlock the screw beneath the rail on the distal clamp.

Before making an angular correction, the distal clamp must be locked to the rail and the CD-unit removed.



The angular deformity is then corrected by turning the locking screws (a) clockwise and (b) anticlockwise. NB. The weight of the limb should be supported during this manoeuvre to prevent excessive strain on the bone screws.

The angular correction may produce translation which will need to be addressed. Correction is achieved by turning both the locking screws (a) and (b) clockwise.



Use of the Advanced Multiplanar Clamp

This will be used at either end of an LRS rail to correct an angular or translational deformity. The plane and size of deformity will have been determined through preoperative planning. If only angulation is present, then preoperative anatomical axis planning will reveal an apex (CORA) which coincides with the apex of the deformed bone. When the CORA lies either above or below the apex of the deformed bone, translational deformity co-exists. Translational deformity, if present, will need careful assessment; the size of this deformity and its plane will determine if a monolateral fixator system is appropriate.

If the CORA is sited at the same level in the bone on both AP and lateral X-rays, the translational and angular deformities are in the same plane. In this case, correction with the multiplanar clamp is straightforward. It is achieved by placing the center of rotation (axis of hinge) of the multiplanar clamp at the level of the bisector of the CORA, and aligning the hinge of the multiplanar clamp so that it acts in the plane of the deformity.

The multiplanar clamp with the LRS is also indicated in deformities where the plane of translational deformity, although different from the plane of angular deformity, coincides with a safe corridor for the insertion of bone screws. The bone screws are inserted through this safe corridor, in line with the plane of translational deformity, and the translation is then corrected through the gradual correction facility on the clamp. Angular correction is dealt with separately by aligning the hinge on the clamp to act within the plane of angular deformity.

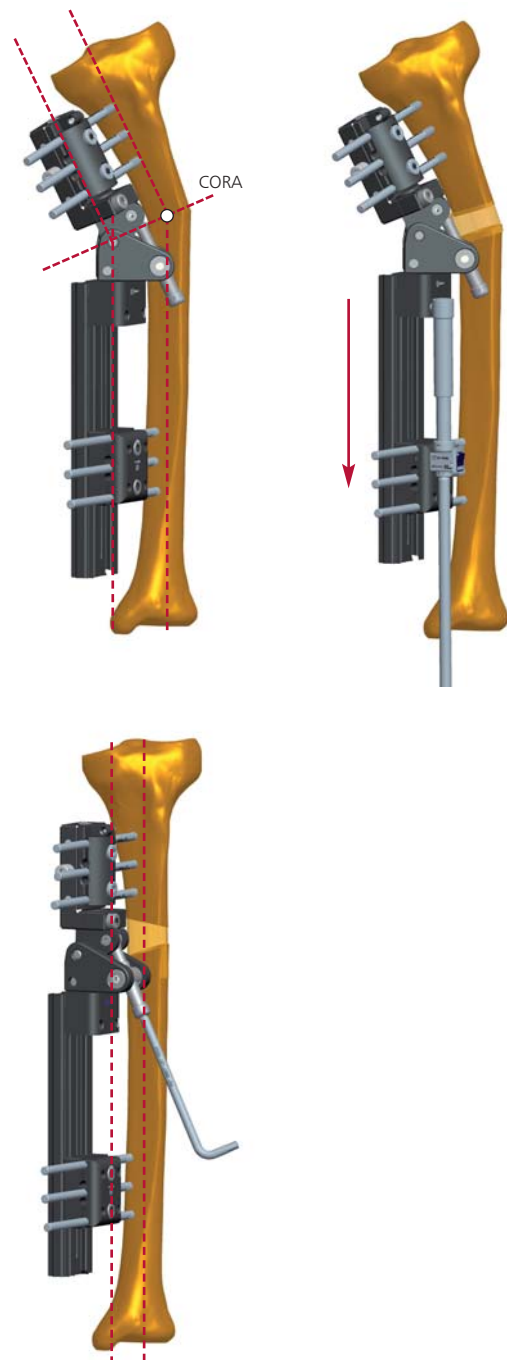
If the translational and angular deformities are not in the same plane, and the translational deformity is not in a plane suitable for screw insertion, correction with the multiplanar clamp is not recommended, and a circular frame should be used.

For the multiplanar clamp to function correctly, the following objectives have to be accomplished during surgery:

- a) Depending on preoperative planning, the centre of rotation (hinge) of the multiplanar clamp must be placed on the bisector line of either:
 - I) The apex of the deformed bone (when translational deformity is absent, or if present, correction is envisaged through the micrometric facility on the clamp), or
 - II) The CORA, when located above or below the apex of deformity, so that both angulation and translation can be corrected simultaneously.
- b) Screws are inserted on both sides of the apex of the deformed bone, perpendicular to the anatomical axis of each segment of bone.

c) The osteotomy is performed at the apex of the deformed bone.

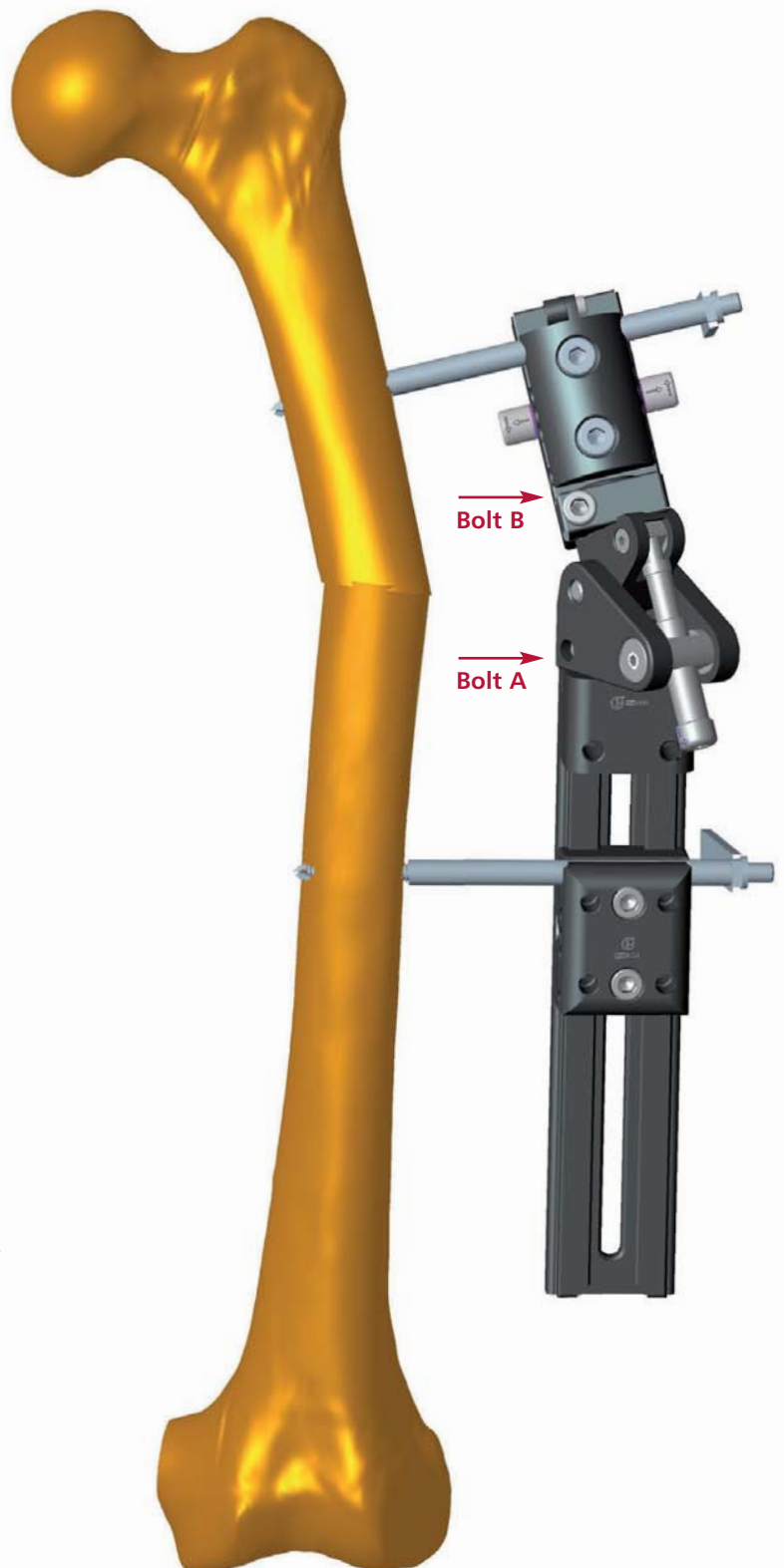
d) The steps in correction are as described in the protocol above, depending on whether the hinge of the multiplanar clamp lies on the convex or concave side of the deformity.



The angulator of the Advanced Multiplanar Clamp is set to the plane of the deformity determined by pre-operative planning, and locked in this position by tightening bolt A. This plane is measured relative to the plane of screw insertion, either the sagittal or coronal planes in the tibia, or the coronal plane in the femur. The hinge of the angulator is now set to the angle of the deformity determined from the pre-operative planning, by turning the distractor.

The assembly is held at the correct distance from the skin, and the position of the rail adjusted so that the center of rotation (hinge) of the multiplanar clamp lies at the same level as either the apex of the deformed bone or the bisector line of the CORA, as dictated by the results of pre-operative planning. The positions of the CORA and bone screws are marked on the patient with a skin pen, bearing in mind the plane of screw insertion. If the pre-operative assessment of the angle and plane of the deformity has been performed correctly, a trocar held in each clamp should be at 90° to the anatomical axis of each bone segment. If this is not the case, the situation should be re-assessed, and the angle or plane of the angulator adjusted accordingly. An appropriately sized bone screw is inserted into the longer bone segment through a screw guide in the straight clamp, on one side of the apex of the deformity, paying due attention to safe corridors and using X-ray guidance to ensure it lies in the centre of the bone, perpendicular to the axis of that segment. The distance between the rail and the skin is adjusted to 2-3 cm. A screw guide and trocar are inserted through the multiplanar clamp; if the prior frame assembly was correct, the trocar should point at right angles to the segment of bone. If not, minor adjustments through rotation of the clamp and adjustment of the angulator should be made. The clamp is then locked in this position by tightening bolt B. A second bone screw is inserted through the clamp in the usual manner, ensuring it points to the center of the bone.

Prior to insertion of the second screw, ensure that adequate bone purchase is possible through the remaining planned screws using a K-wire manually. The entire assembly should now be supported on the limb by one bone screw on each side of the deformity.



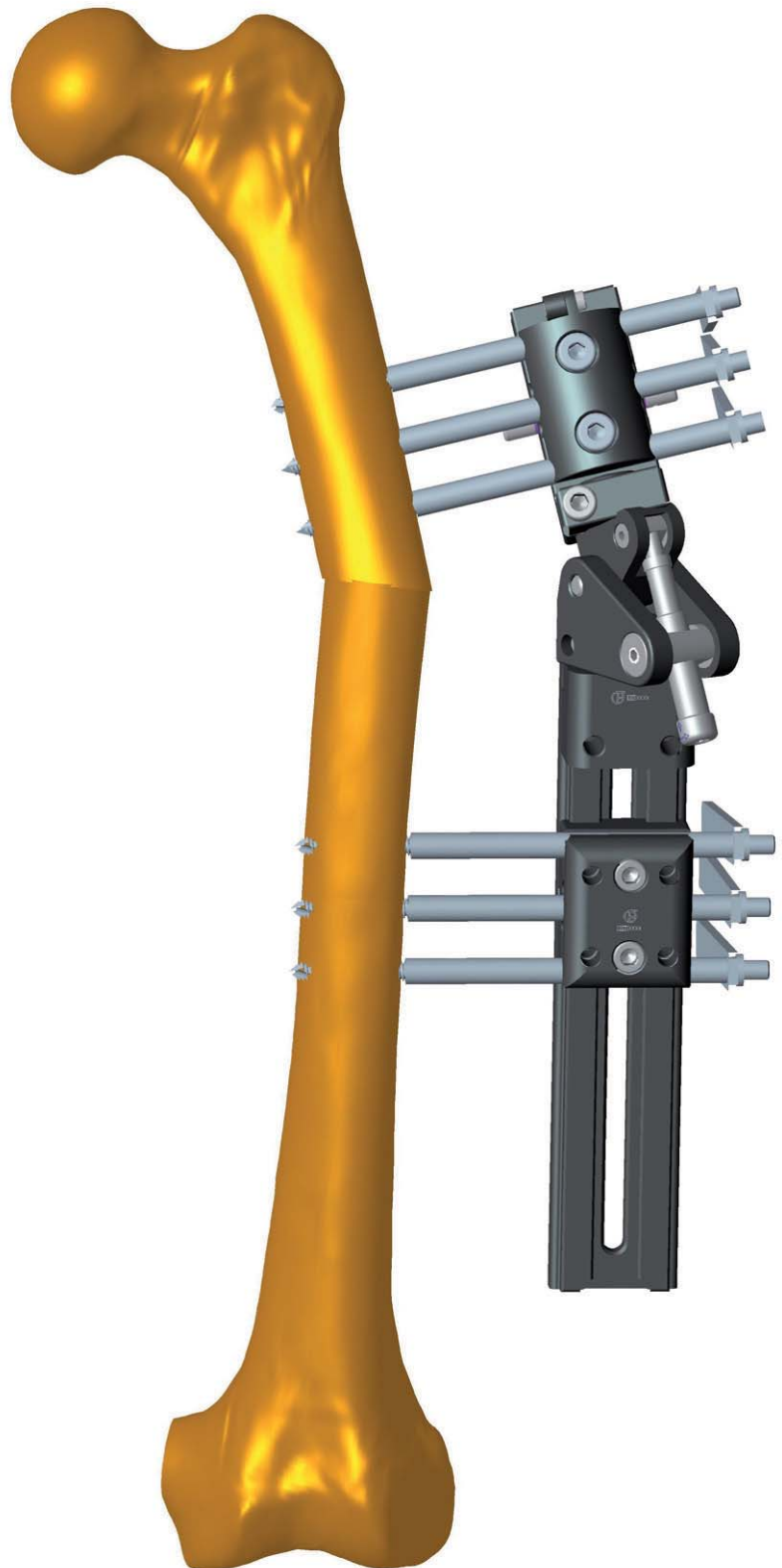

The remaining bone screws are now inserted through both clamps. In an adult, there should be three screws evenly spaced in each clamp.

The osteotomy is performed through the apex of the deformity in the usual manner for intended callotasis. Because the multiplanar clamp permits angular correction in a plane different from the plane of insertion of screws (unlike the micrometric swivelling clamp), it is the hinge position in relation to the convexity or concavity of the deformity which is relevant, not just the position of the fixator.

As with the swivelling clamp, if the hinge is on the concave side of the deformity, length must be obtained first to avoid impaction of the bone ends. It is better also to gain length first even when the hinge is on the convex side, to avoid excessive soft tissue tension when making the correction.

When correction is complete, the Multiplanar Clamp should finish up in line with the LRS rail.

As the Multiplanar Clamp is fixed to the end of the rail, the new bone segment should be dynamised by releasing the clamp locking screw of the adjacent straight clamp, protected if necessary by a Dyna-Ring.



Use of The Advanced T-Garches Clamp

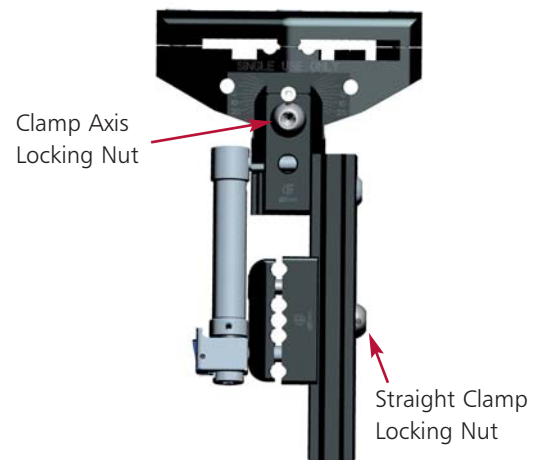
The T-Garches Clamp may be used for lengthening, angular correction or a combination of the two. This is governed by which locking screw is released, and the type and position of the compression-distraction unit.

In figure (a), the fixator is configured for lengthening. The Compression-Distraction Unit is used and located proximally in the base of the T-Garches Clamp and in the distal straight clamp. The clamp axis locking nut (located in the centre of the 'T') is **LOCKED**, and the straight clamp locking nut (located on the rail behind the clamp) is **LOOSENED**. Extension of the compression-distraction unit lengthens the bone without any angular correction.

In figure (b), the fixator is configured for angular correction. The Advanced Garches Compression Distraction Unit is used, located proximally on the anterior part of the T-Garches Clamp and distally on an Advanced Dyna-Ring (53536). The proximal locking bolt is secured with a plastic nut (see inset). The straight clamp locking screw is **LOCKED** and the clamp axis locking nut **LOOSENED**. Alteration of the length of the compression-distraction unit now changes the varus/valgus alignment of the T-Garches Clamp, without any risk of shortening a previously lengthened segment.

This clamp can therefore be used for angular correction during proximal tibial lengthening, or for the planned correction of a valgus or varus deformity of the proximal tibia. It is commonly used for the realignment of tibia vara in association with medial compartment osteoarthritis of the knee.


This clamp should not be used for correcting procurvatum/recurvatum femoral deformities.



Tibial Lengthening: Operative Technique


FIRST STAGE: Fixation and osteotomy of the fibula in its distal region

A screw fixing the distal fibula to the tibia is placed obliquely proximal to the level of the ankle syndesmosis in order to prevent any displacement of the malleolus during the lengthening procedure.

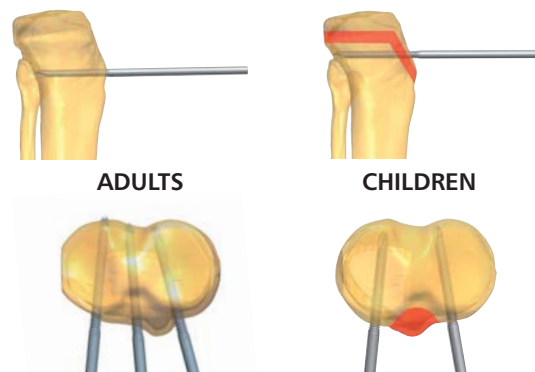


SECOND STAGE: Positioning of the clamp

The joint line of the knee and the anterior tuberosity of the tibia must be located by careful palpation and the use of image intensification. **The clamp is kept at 20 mm distance from the skin by means of a spacer.** The T-Garches Clamp must be placed parallel to the upper surface of the tibia and in the coronal plane otherwise, accurate correction in the desired plane will not be possible.

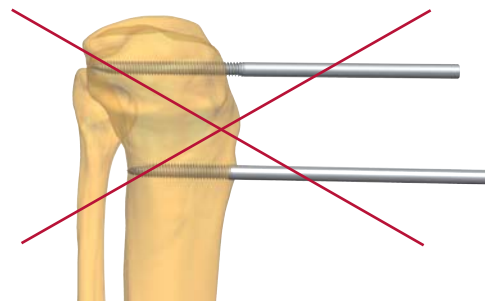


The upper limit of the T-Garches Clamp should be positioned in such a way that the clamp axis locking nut is at the same level as the osteotomy site, i.e. just below the tibial tuberosity. When planning the upper limit of the T-clamp in children, the surgeon should also bear in mind that the screws must be placed below the growth plate.



Particular care should be taken to avoid:

1. Placing the T-clamp too high, with the risk of screws entering the joint or damaging the growth plate in children.
2. Placing it too low, in which case the osteotomy will become diaphyseal rather than in the metaphysis.



Once the Advanced T-Garches Clamp has been correctly positioned, as described above, it should be anchored temporarily to the tibia by means of a Kirschner wire inserted through the hole above the clamp axis locking nut. Correct positioning should then be confirmed by X-ray.

This clamp must be positioned at a distance of 20 mm from the bone (never greater than 30 mm). Use of the spacer is necessary for correct placement of the clamp.

The rail is now arranged so that it is parallel to the tibial diaphysis. As the joint line of the tibia is not exactly perpendicular to the axis of its shaft, the clamp axis locking nut will need to be loosened to allow correct positioning of the rail on the diaphysis. Check to ensure the rail is at the same distance from bone as the T-Garches clamp. The screws through the distal clamp will need to enter the anteromedial surface of the tibia approximately 1cm medial to the crest of the tibia. A Kirschner wire can be used through the clamp to secure this position once it is obtained. The clamp axis locking nut is then tightened.

THIRD STAGE: Screw insertion

The proximal screws are inserted first. **Three screws should be always used for maximum stability**, taking care of the neurovascular bundle behind the proximal tibia. The two outer screws should be inserted with slight convergence, if possible. Screw placement should be performed under image intensification to ensure that adequate penetration of the bone. In children, a middle screw must not be included in the assembly, since it would damage the growth plate of the tibial tuberosity. The diaphyseal screws are then inserted perpendicular to the anatomical axis. The Kirschner wires and screw guides are removed, and the clamps and clamp axis locking nut are tightened.

FOURTH STAGE: Tibial osteotomy

An antero-medial or an antero-lateral percutaneous approach may be used. The periosteum is incised longitudinally below the level of the tibial tuberosity and elevated carefully on the anteromedial and lateral surfaces. Osteotomy is then performed at the level of the clamp axis locking nut, just below the insertion of the patellar tendon. The bone segments are distracted by two or three millimeters using the compression distraction unit (one turn anticlockwise = 1 mm distraction), in order to check whether the osteotomy is complete. The gap can be carefully probed with a flat blunt instrument, or alternatively the fixator is removed and the fragments are gently manipulated to ensure adequate mobility, before reapplication of the fixator. The bone segments are then brought back into contact (one turn clockwise = 1 mm compression). The straight clamp locking screw is then tightened. Closure is by suture of the periosteum and skin.

Note: During distraction, weightbearing should be limited to 30% partial weight bearing.



Correction of Varus or Valgus Deviation

Gradual Correction

An angular deviation (tibia valga, tibia vara) can be gradually corrected with this module.

The application technique is essentially the same as that used for a tibial lengthening.

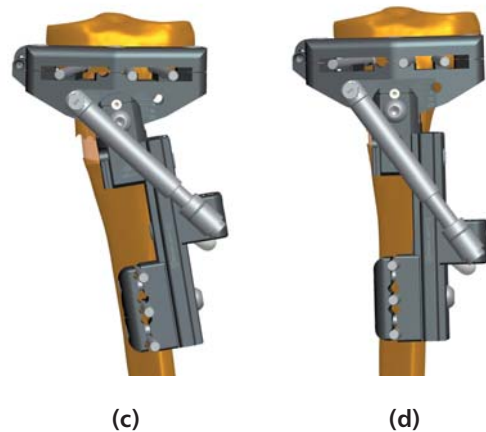
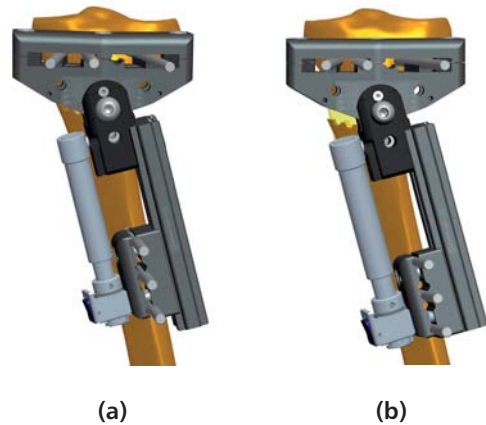
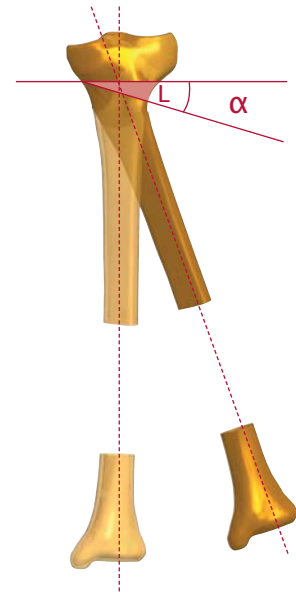
The surgeon should determine pre-operatively the distance L shown opposite by drawing the anatomical axis for both the deformed and the corrected tibia.

Fibular osteotomy should be performed, and a complete tibial osteotomy performed just below the insertion of the patellar tendon.

The compression-distraction clicker unit is placed as shown in figure (a).

The waiting period before starting distraction is normally ten days in adults, and less in children and patients with anticipated faster ossification times.

With the **clamp axis locking nut TIGHTENED** and the **straight clamp locking screw LOOSENED**, the osteotomy site is then gradually **distorted** (b) according to the principles of callotasis, to an amount equal to the distance L (see figure above).



Once this initial distraction has been carried out, the **straight clamp locking screw is TIGHTENED** and the Advanced Garches compression-distraction unit positioned as shown in figure (c). The **clamp axis locking nut is then LOOSENED** and compression carried out at a rate of 1/4 turn four times a day. Once the compression-distraction unit has again been closed by the distance L , the angular deformity should be corrected (d).

Once correction has been achieved, the **clamp axis locking nut is TIGHTENED**.

Protected partial weightbearing of 30% body weight is recommended during the lengthening and correction period.

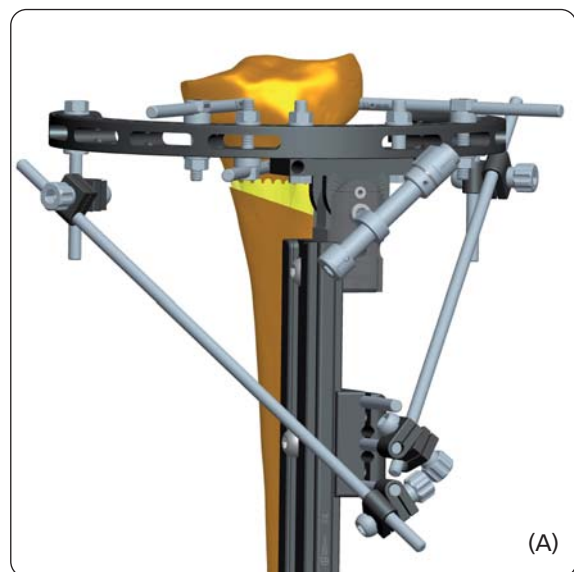
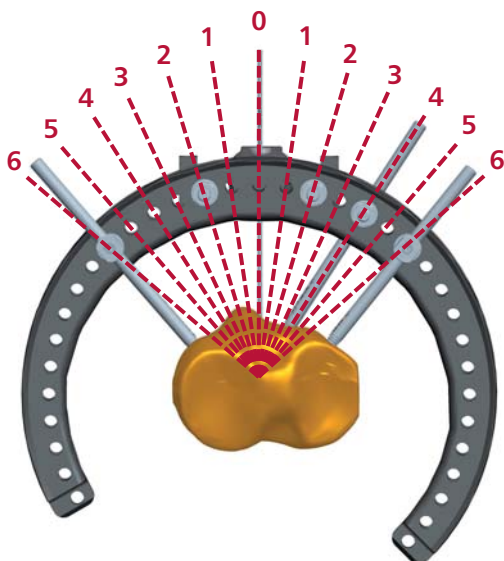
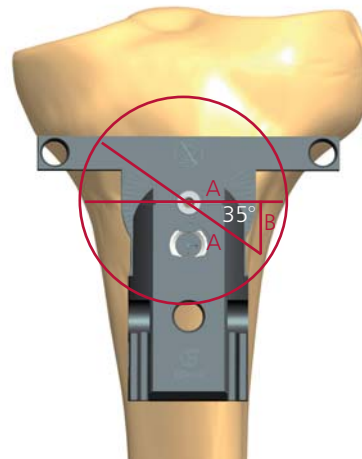

Use of the Advanced Ring Hinge

The Ring Clamp may be attached to a ring and to one end of the rail. **This clamp has not been designed for lengthening procedures and should never be subjected to the forces of lengthening.** It may be used in gradual or acute angular corrections in one plane only as long as a **minimum of 3 independent single screws are applied to the ring to guarantee rotational stability**, with two screws inserted above and 1 below the ring. The two outer screws should be inserted at an angle close to but no greater than 90°.

The assembly is normally placed anteriorly in the tibia to adjust varus/valgus alignment, but this can be altered to allow oblique plane correction if desired. When positioned with the center of rotation of the Ring Hinge over the centre of the CORA, translation does not occur during correction.

The osteotomy is performed at the level of the hinge. The maximum amount of angulation permitted at the hinge is 35°. The osteotomy site should be distracted, before performing any angular correction. Bars can be added at completion of gradual angular correction to allow early weightbearing (see inset A).

The Ring Hinge can be used with a minimum of 3 tensioned Kirschner wires with a crossing angle of at least 60 degrees, **as long as reinforcement bars are added to the frame after the correction.**



Use of the Advanced Acute Correction Templates

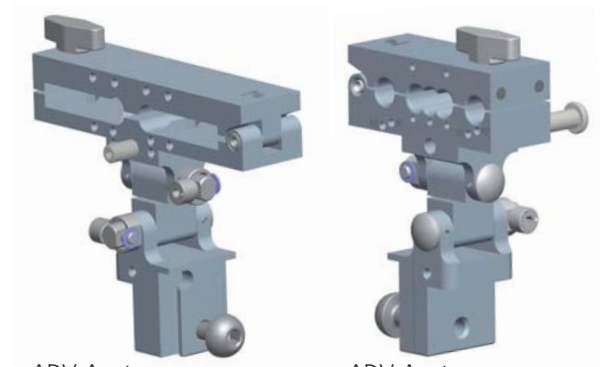
Acute Correction

The acute angular correction templates are designed to allow for accurate placement of two sets of bone screws, each at right angles to the anatomical axis of a bone segment, proximal and distal to the apex of a deformity. The templates are not to be used to manipulate an acute correction but simply to allow accurate screw placement in conjunction with the Advanced LRS rail. If the bone screws are inserted correctly using these templates, the manipulation to seat the screws into standard straight LRS clamps should complete the required correction.

These templates may be used to correct a deformity which consists of angulation, rotation or a combination of the two. They may be used for angular correction in the sagittal, coronal or oblique planes and for derotation. The extent to which a deformity may be safely corrected acutely depends on the site of osteotomy and the effect of acute correction on structures at risk (usually nerves) and the soft tissue tension.



General Principles

These templates are designed to permit accurate screw placement in each segment of a bone on either side of the apex of a deformity. The bone screws are inserted perpendicular to the anatomical axes of the relevant bone segments. An osteotomy is carried out at the apex of the deformity. The templates are then removed, and the limb manipulated so that the two sets of bone screws can be seated into standard LRS clamps. This produces the required correction. Preoperative planning will determine whether a deformity may be resolved by a correction at one site (monofocal) or two (bifocal). Additionally, each site may have only one parameter for correction, e.g. rotation (and is classified as simple), or it may require the correction of several parameters, e.g. angulation, rotation and length (and is therefore classified as complex). In a complex monofocal deformity, both angulation and rotation may be corrected acutely and simultaneously; length can then be restored gradually in accordance with the principles of lengthening through callotasis.



ADV Acute Correction
Garches Template
(14332)

ADV Acute Correction
T-Template
(14334)



ADV Acute Correction
Straight Template (14333)

Caution with Acute Correction

As a general rule, acute corrections are possible in the femur but caution is required with tibial deformities, especially at the proximal tibia. For larger femoral deformities and proximal tibial deformities, gradual correction is the preferred method. Soft tissue considerations are important, particularly with regard to the common peroneal nerve in the proximal tibia. Exploration and release of the common peroneal nerve may be required. Distal tibial corrections are less liable to cause problems, but care should be taken to ensure that the posterior tibial nerve is not stretched. Gradual correction with a circular or monolateral fixator may be safer in these situations. Although these constraints are less significant in the femur, any sudden change of shape in the distal femur (or derotation) may create an unwanted effect on patella tracking. To prevent this, it is safer to perform a rotational correction in the proximal femur. Conversely, if patellar maltracking is present due to a rotational malunion, correction distally may be preferable to realign the patella mechanism at the same time. Careful pre-operative planning is necessary to achieve optimum results.

Angulation Templates

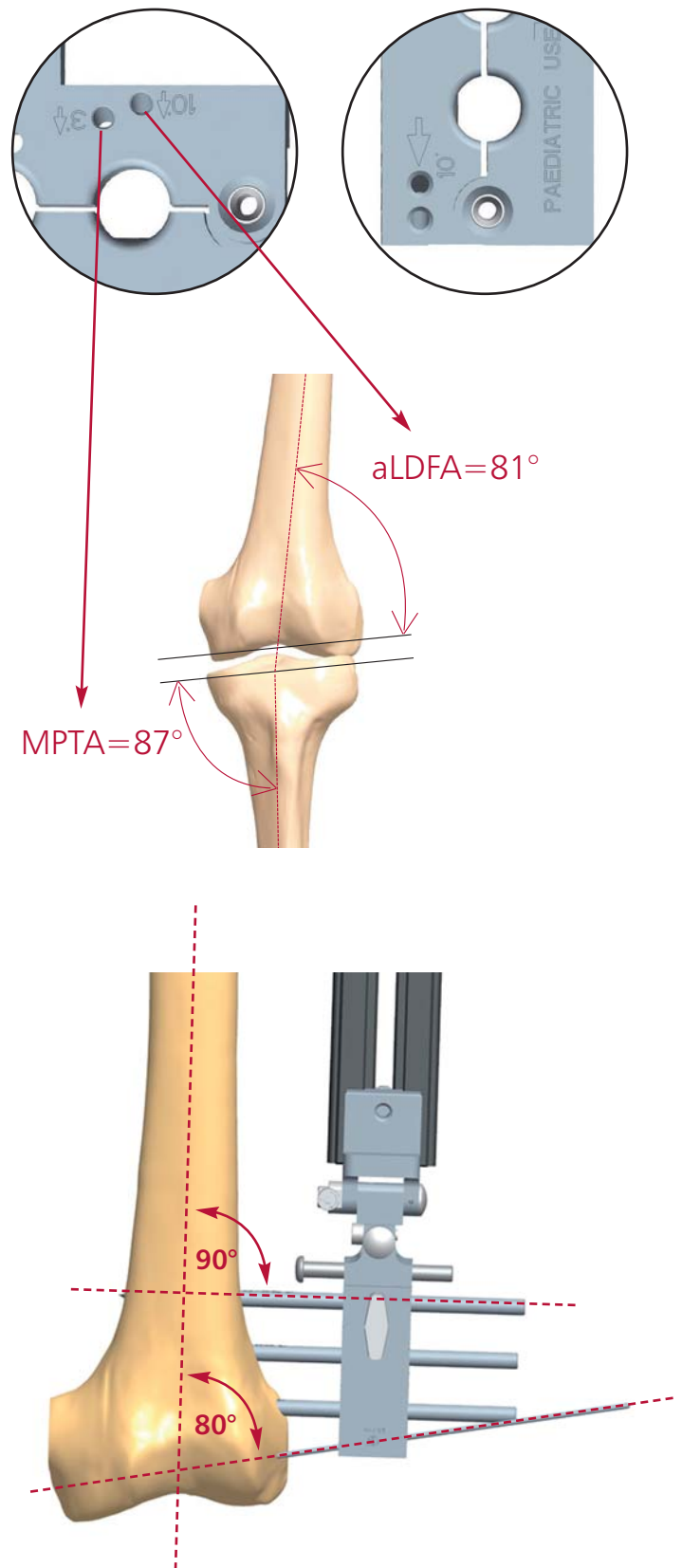
Frontal and sagittal plane deformities are measured from appropriate radiographs with a goniometer. An LRS rail is assembled with an angulation template attached at one end. The locking screws for the two hinges of the angulation template are loosened, and the template adjusted in each plane to match the deformities measured on the antero-posterior and lateral X-rays. The hinge locking screws are tightened. The assembly is now aligned to mimic the deformity in the bone. These templates may be used in combination with a straight clamp mounted on the rail, or with the derotation template, if a rotational deformity is also present.

On the Advanced Acute Correction T-Template there are two holes marked 3° and 10° respectively. Once a K-wire has been applied parallel to the articular surface and positioned in the appropriate hole (3° in the tibia and 10° in the femur), the bone screws will automatically be at right angles to the anatomical axis.

In the Advanced Acute Correction Straight Template only the 10° hole is present.

Note: The Clamps are designed for both left and right limb. When inserting the K-wire, make sure to use the hole indicated by the arrow on the Clamp facing the surgeon.

The 3° hole was designed to take into account that the axis of the tibia is approximately 3° off a perpendicular to the tibial shaft. The 10° hole was designed to take into account that the joint line of the distal femur is approximately 10° off a perpendicular to the axis to the femoral shaft.

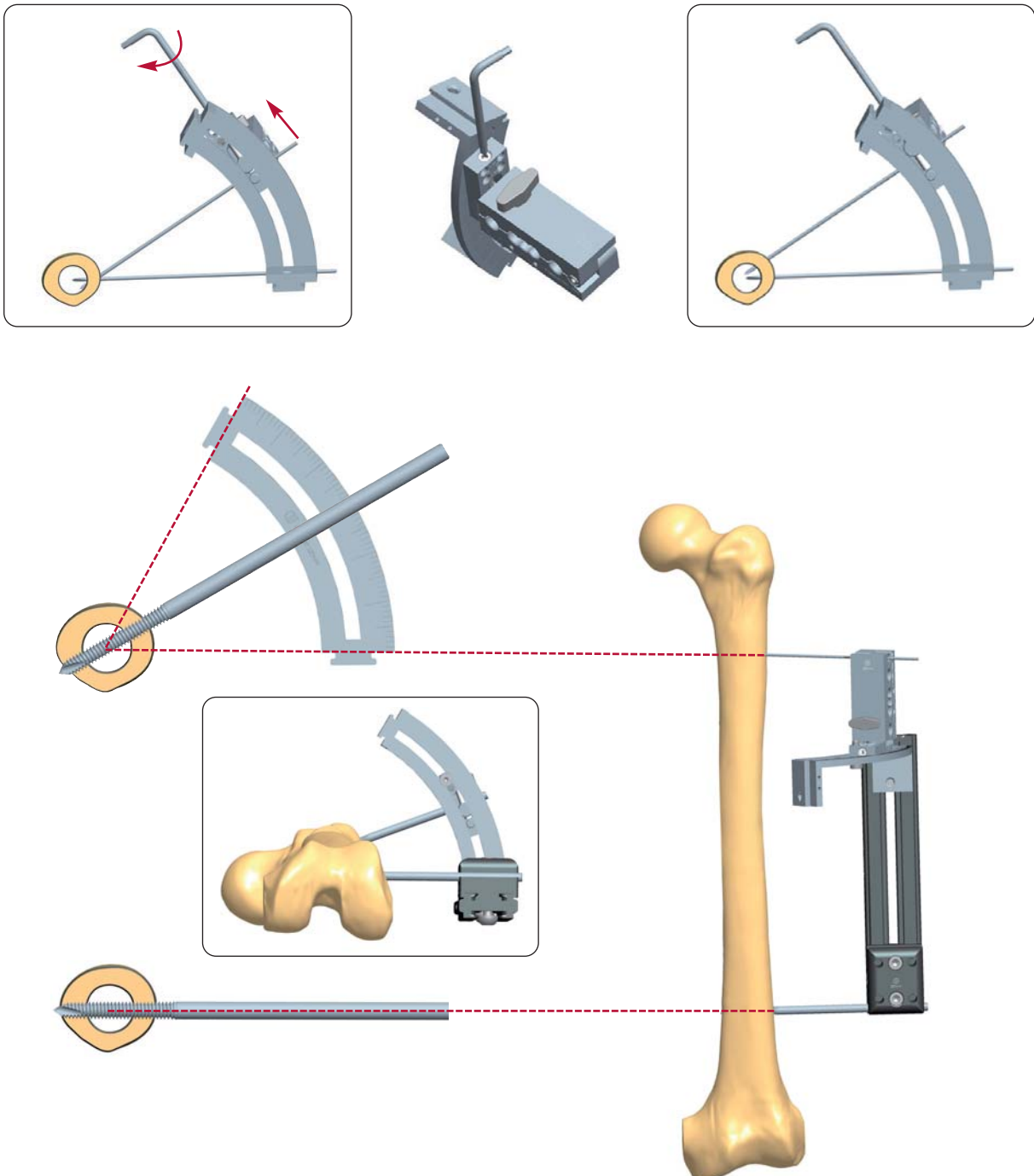


Derotation Templates

A rotational deformity can be corrected by inserting pairs of bone screws at a defined angle to each other in the transverse plane. After an osteotomy has been performed between the pairs of bone screws, they can be brought into the same plane and secured in straight clamps of the LRS rail until the bone heals. This can be done as an isolated procedure, or in combination with an angulation template for the correction of a combined angular and rotational deformity. It is also possible, if necessary, to combine this acute correction with later lengthening. The derotation templates allow the surgeon to place the pairs of bone screws at a precise angle to each other

to allow accurate correction of the deformity.

The deformity can be assessed clinically using the rotational profile method in the prone position or can be measured with CT scans. The screws must be inserted accurately, passing through the center of the bone at each level. To achieve this, the LRS rail must be at a distance from the center of the bone equal to the radius of chosen arc. If the distance between rail and bone is not equal to the radius of arc selected, there may be some translation between the two bone segments after correction. To avoid this, the clamp can be moved along the arc tangent by turning the threaded screw. This allows accurate positioning of the bone screws in the centre of the bone.

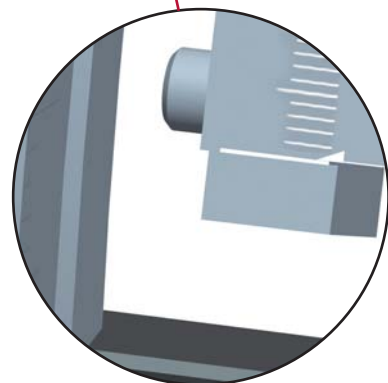
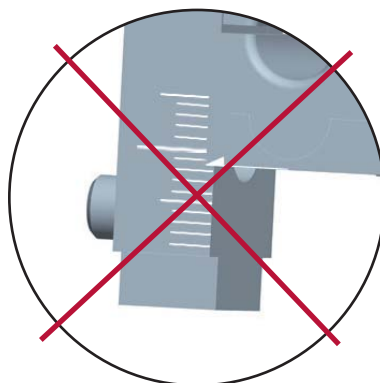
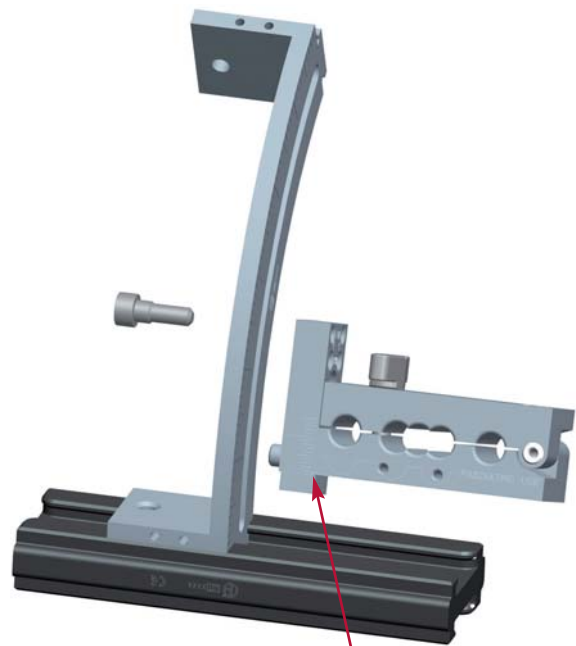
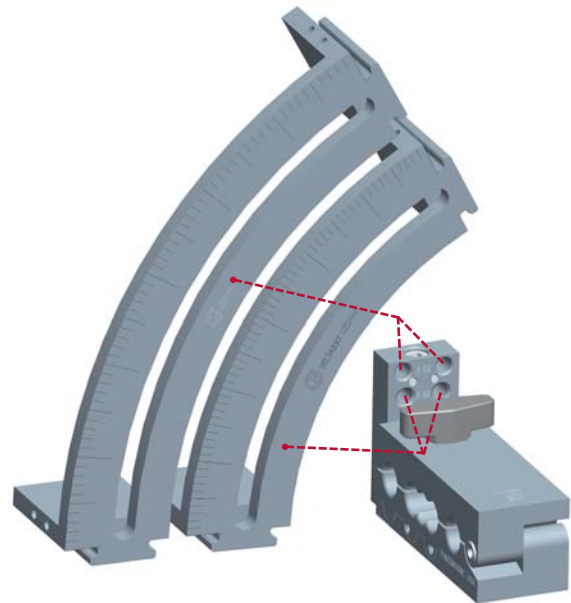


Derotation Template Assembly

The arc can be attached and slid into any position on the rail, but must be positioned with the arc curving towards the patient. It is important that the template clamp is attached to the arc in the correct manner. Note that the template clamp has four threaded holes on the larger end. These are in two groups of two to allow left or right attachment of the two available arc sizes. The template is assembled as follows:

1. The correct size of arc is chosen, by measuring the distance between the center of the bone and the position of the clamps outside the skin surface using a K-wire percutaneously. If using the K-wire against the cortex of the bone, remember to add a distance from the K wire to the centre of the bone – this is equivalent to the radius of the bone at that level – which can be estimated from intra-operative x-rays. The appropriate arc is attached and locked to the rail so that it curves towards the patient. The template clamp is placed flat on the rail on the side away from the flanges on the arc, with the peg engaging in the slot on the arc. Before inserting the clamp on the arc, make sure that the arrow is aligned with the mark on the base.
2. The locking screw is inserted into the corresponding screw hole labelled with the correct radius for the arc being used, and tightened. Ensure that the template clamp is lying flat on the rail when this screw is tightened.
3. The locking screw is now loosened enough to allow the template clamp to rotate round the arc to the correct position for screw insertion. The base of the main part of the clamp body should be opposite the chosen degree mark on the arc, in this example 25°.

Note: If it is fixed to the arc with the incorrect screw hole, the template clamp will be tilted relative to the rail when it is in the zero position, and correct screw insertion will not be possible without removing the clamp from the rail.



Example Application Showing Use of Angulation and Derotation Templates

In the example below a 20° varus and a 25° internal rotation deformity in the midshaft of the left femur will be corrected acutely, using both the angulation and derotation templates.

However, for an isolated angular or rotational deformity, either can be used alone with the technique described below, combined with a standard clamp on the rail.

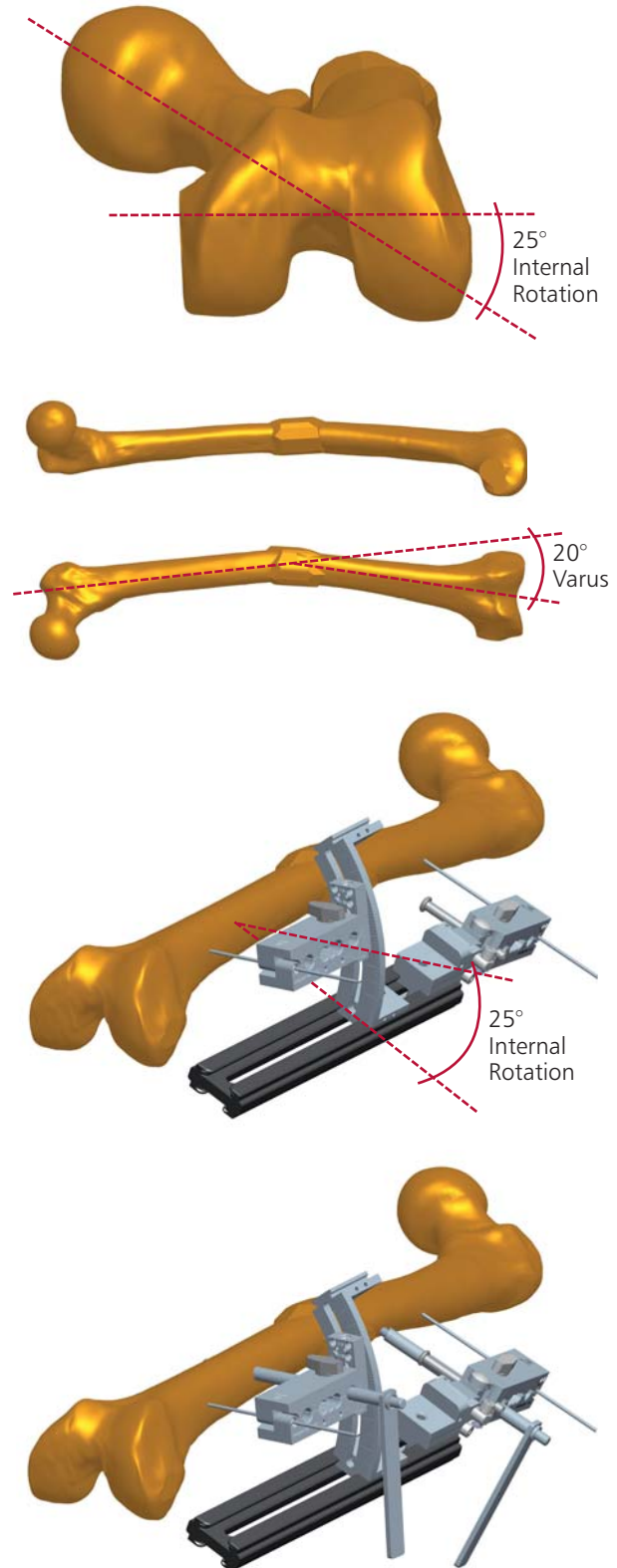
The frontal and sagittal plane deformities are measured from appropriate radiographs with a goniometer. Rotation is assessed clinically and, where required, by CAT scan.

In this case the proximal angulation template has been adjusted to reflect the varus deformity, and the hinge locking screws are tightened. The distal clamp is mounted on an appropriate arc to reflect the rotational deformity.

With a skin pen, the level of the apex of the deformity and the prospective sites for screw insertion are marked out. The hinge of the angulation template should be positioned opposite the deformity; the position of the arc on the rail is adjusted to ensure an appropriate distance between the apex of the deformity and the two clamps. A Kirschner wire can be used through each template to provisionally secure the assembly to the femur and allow checks to be made before screw insertion. A straight trocar is used, with a screw guide, to confirm that each set of bone screws is perpendicular to the anatomical axes of the corresponding bone segments.

The screws are placed in such a way so that, after osteotomy, manipulating the screws into two straight clamps on a LRS rail will produce the required deformity correction.

The rail with templates attached is placed so that the hinge in the angulation template is opposite the apex of the deformed bone. A screw is inserted at right angles to the anatomical axis of the proximal femoral segment, just proximal to this apex. The rail is held 3-4 cm from the skin, and the spacing screws in both clamp templates advanced until they touch the skin. The distance between the rail and the center of the bone is now checked, to ensure this radius corresponds to the radius of the arc.



A trocar is now inserted down to the distal segment through a screw guide in the clamp template mounted on the arc.

If the template has been set up correctly, the trocar will point towards the center of the bone, perpendicular to the axis of the distal femur. If it is not at 90° to the axis of the distal segment or does not point to the center of the bone, then the settings of the angulation template and the distance of the rail from the bone should be reviewed.

Note that if the distance between the rail and the bone has changed or is not correct, the second screw will not pass through the center of the bone.

An eccentrically placed screw will result in translation when the definitive fixator is applied, and may weaken the bone hence central placement of bone screws is essential. The spacing screws are adjusted so that the rounded ends are in contact with the skin and maintain the correct skin-fixator distance.

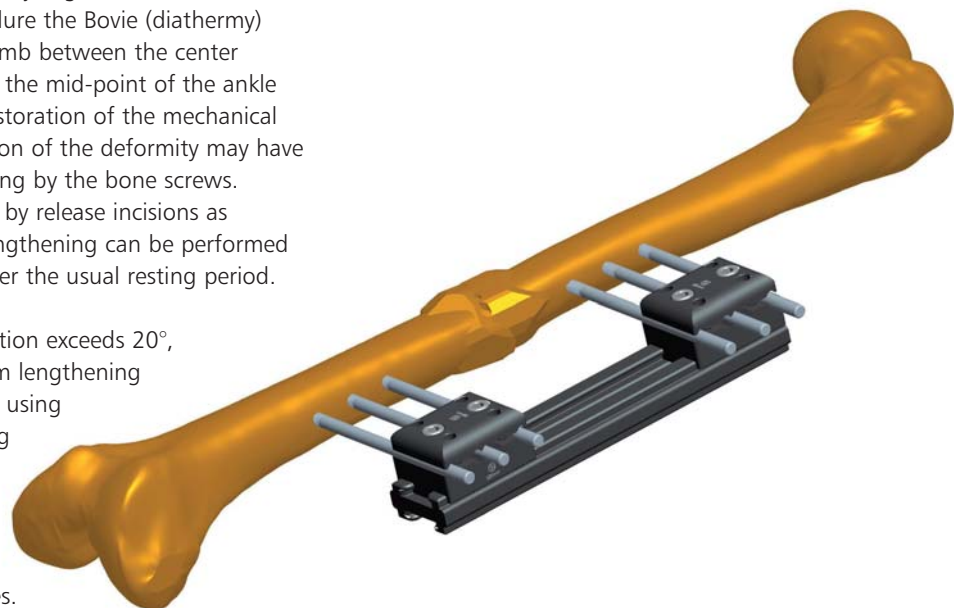
Once the trocar is in the correct position, and bone purchase is possible through all the clamp holes, the second screw is inserted.

With the rail and templates thus held in a fixed relation to the limb, screws are inserted in the remaining seats of each template clamp.

The osteotomy is now performed at the apex of the deformity. The template is removed, and the limb fragments manipulated to correct the deformity. The bone screws should now be parallel. The LRS rail is now reapplied with standard straight clamps, and the clamp locking screws tightened so that the rail is at the same distance from the skin. The Image Intensifier is used to check that there is no gap or translation at the osteotomy, and the clamps are locked into position when a satisfactory alignment is confirmed.

At the end of the procedure the Bovie (diathermy) cord is placed over the limb between the center of the femoral head and the mid-point of the ankle joint to confirm good restoration of the mechanical axis of the limb. Correction of the deformity may have caused some skin tethering by the bone screws. This should be corrected by release incisions as necessary. If required, lengthening can be performed at the osteotomy site after the usual resting period.

NB. If the angular correction exceeds 20°, it is preferable to perform lengthening at a separate osteotomy, using a longer rail and applying a third clamp. This is because regenerate quality in lengthening decreases as the size of acute correction increases.



REFERENCES

Callotasis

- Aldegheri R., De Bastiani G., Renzi Brivio L. Allungamento diafisario dell'arte inferiore (studio di 78 casi). *Chir Organi Mov* 1985; 70: 111-19
- Aldegheri R, Trivella G, Renzi Brivio L, Tessari G, Agostini S, Lavini F. Lengthening of the Lower Limbs in Achondroplastic Patients: a comparative study of four techniques. *J Bone Joint Surg [Br]* 1988; 70-B (1): 69-73.
- Aldegheri R., Renzi Brivio L., Agostini S. The Callotasis method of Limb Lengthening. *Clin Orthop.* 1989; 241: 137-145.
- Aldegheri, R.: Allongement chirurgical dans l'achondroplasie. *Rev. Chir. Orthop.*, 1991; 77 (Supp 1): 70-71,
- Aldegheri, R., and Agostini, S.: A chart of anthropometric values. *J. Bone and Joint Surg [Br]*. 1993; 75-B (1): 86-88.
- Aldegheri, R.: Femoral callotasis. *J. Pediat. Orthop.*, 1997; 6-B: 42-47
- Aldegheri R. Distraction Osteogenesis for Lengthening of the Tibia in Patients Who Have Limb-Length Discrepancy or Short Stature. *J Bone Joint Surg (Am)* 1999; 81-A (5): 624-34,.
- Bhave A, Paley D, Herzenberg JE. Improvement in gait parameters after lengthening for the treatment of limb-length discrepancy. *J Bone Joint Surg [Am]*. 1999; 81-A (4): 529-34.
- Busetto R., De Bastiani G., Giannoccaro A., Boccanera L., Renzi Brivio L., Lavini F. Studio morfologico del callo osseo durante osteogenesi riparativa in corso di distrazione con fissatore esterno assiale (F.E.A.) nella pecora. Comunicazione alla Società Italiana delle Scienze Veterinarie, 1988.
- De Bastiani G., Aldegheri R., Renzi Brivio L., Trivella G. Limb Lengthening by Callus Distraction: Callotasis. *J. Paediatr. Orthop.* 1987; 7 (2): 129-134.
- Giebel G. In *Callus Distraction: Clinical Applications*. 1992. Georg Thieme Verlag, Stuttgart, New York.
- Gonzalez FL, Arevallo RL, Coretti SM, Labajos VU, Rufino BD. Pulsed Electromagnetic Stimulation of Regenerate Bone in Lengthening Procedures. *Acta Orthop Belg* 2005; 71: 571 - 6
- Hatzokos I, Drakou A, Christodoulou A, Terzidis I, Pournaras J. Inferior Subluxation of the Fibular Head Following Tibial Lengthening with a Unilateral External Fixator *J Bone Joint Surg* 2004; 86-A (7):1491 – 6
- Inoue N, Ohnishi I, Chen D, Deitz LW, Schwardt JD, Chao EYS. Effect of pulsed electromagnetic fields (PEMF) on late-phase osteotomy gap healing in a canine tibial model. *J Orthop Res* 2002, 20: 1106–1114
- Kojimoto H., Yasui N., Goto T., Matsuda S., Shimomura Y. Bone lengthening in rabbits by callus distraction. *J. Bone Joint Surg.* 1988 ; 70-B: 543-549.
- Kojimoto H., Yasui N., Sasaki K., Shimizu H., Shimomura Y. Blood supply after transverse osteotomy in experimental bone lengthening by callus distraction. From: 13th International Conference on Hoffman External Fixation - May 1989.
- Pouliquen J. C., L'Anglais J., Ceolin J.L., Pauthier F. The use of the Dyna-ring in lengthenings of the lower limb. Presented at the second Riva Congress on Current Perspectives in External and Intramedullary Fixation, Riva del Garda, Italy, 27-31 May 1992.
- Saleh M., Burton M. Leg Lengthening: Patient Selection and Management in Achondroplasia. *Orthopaedic Clinics of North America*, (1991), 22:589-599.
- Saleh M., Flowers M.J. Bifocal Comment article "Limb Lengthening". *Current Medical Literature. Orthopaedics*, (1994), 7 (3): 71-73.
- Saleh M., Hamer A. Bifocal lengthening - preliminary results. *J. Paed. Orthop.* 1993; 2-B: 42-48.
- Trivella G and Aldegheri R. Surgical Correction of Short Stature. *Acta Paed Scand [Supp]* 1988; 347: 141 - 6
- Trivella G, Brigadoi F, Aldegheri R. Leg Lengthening In Turner Dwarfism. *J Bone Joint Surg [Br]* 1996;78-B (2): 290-3.
- Williams P, Kyberd P, Simpson H, Kenwright J, Goldspink G. The morphological basis of increased stiffness of rabbit tibialis anterior muscles during surgical limb-lengthening *J. Anat.* (1998) 193, 131-138
- Yasui N, Kawabata H, Nakanishi H. Bilateral and Bifocal Lengthening in the Tibia and the Femur using a Segmental Slide Lengthener. *Int J Orthop Tr* 1993; 3 (3): 87-88

Limb reconstruction

- Biermann J.S., Marsh J.L., Nepola J.V., Lavini F., Renzi Brivio L. Unilateral Bone Transport System for Segmental Deficiency of Bone. Presented at the American Academy of Orthopaedic Surgeons, Anaheim, California 7-12 March 1991.
- Bohler L. The Treatment of Pseudoarthrosis. In: *The Treatment of Fractures*. Vienna, Wilhelm Maudrich, 1929, 23-28.
- Charnley G., Baker S.L. Compression Arthrodesis of the knee. A clinical and histological study. *J. Bone Joint Surg.* (1952), 34-B: 187-199.
- Colchero R.F., Orst G., Vidal J. La scarification, son intérêt dans le traitement de l'infection ostéo-articulaire chronique fistulisée à pyogènes. *Int. Orthop*, 1982, 6 (4): 263-271.
- Donnan LT, Saleh M. Monolateral external fixation in paediatric limb reconstruction. *Current Orthopaedics*, (1998), 12: 159-166.
- Donnan LT, Saleh M, Rigby AS. Acute correction of lower limb deformity and simultaneous lengthening with a monolateral fixator. *J Bone Joint Surg*, 2003; 85-B (2): 254-60.
- Giannikas AK, Maganaris CN, Karski MT, Twigg P, Wilkes RA, Buckley JG. Functional Outcome Following Bone Transport Reconstruction of Distal Tibial Defects *J Bone Joint Surg* 2005; 87-A (1): 145 - 52
- Giebel G. Resektions - Débridement mit kompensatorischer Kallusdistraction. *Unfallchirurg.*, (1991), 94: 401-408
- Giotakis N, Narayan B, Nayagam S. Distraction osteogenesis and nonunion of the docking site: is there an ideal treatment option? *Injury* 2007; (38) Supp 1: S100—S107
- Glowacki J., Mulliken J.B. Demineralised bone implants. *Clin. Plast. Surg.*, (1985), 12: 233.
- Hashmi MA, Ali A, Saleh M. Management of non-unions with mono-lateral external fixation. *Injury* 2001;32: SD30–34
- Lavini F, Renzi Brivio L, Pizzoli A, Giotakis N, Bartolozzi P. Treatment of non-union of the humerus using the Orthofix external fixator. *Injury* 2001;32: SD35–40
- Judet R., Patel A. Muscle pedicle bone grafting of long bones by osteoperiosteal decortication. *Int. Orthop.*, (1972), 87: 74-80.

38. Kreibich D.N., Wells J., Scott I.R., Saleh M. Nonunion Donor site morbidity at the iliac crest: comparison of percutaneous and open methods. *J. Bone Joint Surg.*, (1994), 76-B: 847-848.
39. Marsh DR, Shah S, Elliott J, Kurdy N. The Ilizarov method in nonunion, malunion and infection of fractures. *J Bone Joint Surg Br* 1997; 79-B: 273-9.
40. Paley D, Catagni MA, Argnani F, Villa A, Benedetti GB, Cattaneo R. Ilizarov treatment of tibial nonunions with bone loss. *Clin Orthop* 1989; 241: 146-65.
41. Paley D, Herzenberg J E, Tetsworth K, McKie J, Bhav A. Deformity planning for frontal and sagittal plane corrective osteotomies. *Orthop Clin N Am* 1994; 25(3):425-65,
42. Ribbans W.J., Stubbs D.A., Saleh M. Non-union surgery. Part II. The Sheffield experience – one hundred consecutive cases. Results and lessons. *Int J Orthop Tr*, (1992), 2: 19-24.
43. Saleh M. External fixation of long bone fractures in children. British Orthopaedic Association Autumn Meeting, Cambridge, 25-27 September 1991 (Abstract in the *J. Bone Joint Surg.*, (1992), 74-B Orthopaedic Proceedings Supplement 2, page 152).
44. Saleh M. Non-union Surgery. Part I. Basic principles of management. *International Journal of Orthopaedic Trauma*, (1992), 2: 4-18.
45. Saleh M. Non-union treated with the Dynamic Axial Fixator: Results presented at the Second Riva Congress on Current Perspectives in External and Intramedullary Fixation, Riva del Garda, Italy, 27-31 May 1992.
46. Saleh M. Bone Grafting Harvesting: a percutaneous technique. *J. Bone Joint Surg.*, (1991), 73-B: 867-868.
47. Saleh M. Editorial - Mini symposium on bone loss. *Current Orthopaedics*, (1994), vol. 8 no 3: 141-143.
48. Saleh M. The management of bone loss. In C. Court-Brown and D. Pennig (eds): *Tibia and Fibula*. Butterworth - Heinemann, 1997: 143-159.
49. Saleh M., Howard A.C. Improving the appearance of pin site scars. *J. Bone Joint Surg.*, (1994), 76-B, 906-908.
50. Saleh M., Meffert R.H., Street R.J. Bifocal Verlängerung der unteren Extremität mit dynamisch-axialer externer Fixation nach der Technik von Vilarubias. *Tagliche Praxis*, (1994), 35 (1): 83-90.
51. Saleh M., Rees A.R. Bifocal surgery for deformity and bone loss - bone transport and compression distraction compared. *J. Bone Joint Surg.*, (1995), 77-B: 429-434.
52. Saleh M., Royston S. Management of nonunion of fractures by distraction with correction of angulation and shortening. *J. Bone Joint Surg.*, (1996), 78-B: 105-109.
53. Saleh M., Street R., Ribbans W.J. Lower limb reconstruction using the Ilizarov technique. British Orthopaedic Association Spring Meeting, Brighton, 24-26 April 1991 (Abstract in the *J. Bone Joint Surg.*, (1991), 73-B Orthopaedic Proceedings Supplement 2, page 188).
54. Sen C, Kocaoglu M, Eralp L, Gulsen M, Cinar M. Bifocal Compression-Distraction in the Acute Treatment of Grade III Open Tibia Fractures with Bone and Soft-Tissue Loss. *J Orthop Trauma*. 2004 18(3):150–157
55. Song HR, Kale A, Park HB, Koo KH, Chae DJ, Oh CW, Chung DW. Comparison of Internal Bone Transport and Vascularized Fibular Grafting for Femoral Bone Defects. *J Orthop Tr* 2003; 17 (3): 203–211
56. Svesnikov A.A., Barabash A.P., Cheplenko T.A., Smotrova L.A., Larionov A. A. Radionuclide studies of osteogenesis and circulation in substitution of large defects of the leg bones in experiment. *Ortop. Travmatol. Protez.*, (1984), 11:33.
57. Trueta J. Muscle contraction and interosseus circulation. *J. Bone Joint Surg.*, (1965), 47-B: 186.
58. PALEY D. and TETSWORTH K.T. Mechanical axis deviation of the lower limbs: Pre-operative planning of uniapical angular deformities of the tibia or femur. *Clin Orthop* 280:48-64, 1992.
59. PALEY D. and TETSWORTH K.T. Mechanical axis deviation of the lower limbs: Pre-operative planning of multiapical frontal plane angular and bowing deformities of the femur and tibia. *Clin Orthop* 280:65-71, 1992.

APPENDIX

Hydroxyapatite-Coated Bone Screws

As the LRS with its bone screws may be in position for some months, it is strongly recommended that hydroxyapatite coated bone screws are used throughout. These will reduce the rate of screw loosening and infection, and ensure that the frame remains fully stable until the completion of treatment. There is an extensive body of research that confirms the benefits of these screws, particularly when the fixation times are prolonged¹⁻⁷.

Screw Insertion and Pin Site Care

It is very important to follow the basic rules of screw insertion when using the LRS: to select the appropriate thread length for the size of the bone, with just 2-3 threads outside the bone on each side, and to use screw guides fixed in the screw clamps so that the screws are inserted parallel to each other (excluding particular applications where they are designed to be converging). Many of the early complications of external fixation are related to poor screw insertion technique; full details of the techniques of screw insertion are given in Manual 1, Basic Considerations. They are also provided in the leaflet enclosed in the bone screw packaging.

The technique for screw insertion will often determine the fate of the pin sites. If the correct technique has been followed, and hydroxyapatite coated bone screws are being used, serious problems with the pin sites are rare. However, it is very important that the whole department has an agreed protocol for the management of pin site care and pin site problems. The units that have fewer problems are undoubtedly those that have a protocol that all personnel follow and that the patient is informed about and understands. The papers listed in the bibliography⁸⁻¹³ describe the scientific investigation of the causes of pin site problems and the strategies for avoiding them. Early work suggested that simple saline solution or tap water was the correct liquid to use to clean the bone screws and surrounding skin. More recent work suggests that non astringent antiseptic solution may be more effective, with dressings that apply gentle pressure to stabilise the skin and prevent haematoma formation. It is important to avoid skin tethering, and during lengthening procedures it may be necessary to release tensioned skin under local anaesthetic. It is strongly recommended that each unit reviews the current evidence and agrees a protocol for pin site care that matches the personnel and facilities that are available locally. Individual patients will vary in their ability to manage their own pin site care, and the local system adopted should be able to allow for this.

REFERENCES

Hydroxyapatite Bone Screws

1. A Comparison of Hydroxyapatite-Coated, Titanium-Coated, and Uncoated Tapered External-Fixation Pins: An In Vivo Study in Sheep. Moroni, Toksvig-Larsen, Maltarello, Orienti, Stea & Giannini, *J Bone Joint Surg (Am)*, 1998; 80-A (4): 547 - 554
2. Hydroxyapatite coating of threaded pins enhances fixation. Magyar G., Toksvig-Larsen S., Moroni A. J. *Bone Joint Surg (Br)*, 1997; 79-B (3): 487-489.
3. The Effect of Surface Material and Roughness on Bone Screw Stability. Moroni A, Faldini C, V. Chilò, M. Rocca, S. Stea, S. Giannini: *J. Orthop. Trauma*, 1999; 13 (7): 477-482
4. Improvement of the Bone-Pin Interface Strength in Osteoporotic Bone with Use of Hydroxyapatite-Coated Tapered External-Fixation Pins: A Prospective, Randomized Clinical Study Of Wrist Fractures. A. Moroni, C. Faldini, S. Marchetti, M. Manca, V. Consoli & S. Giannini. *J Bone Joint Surg (Am)*, 2001; 83-A (5): 717 - 21
5. Hydroxyapatite-coated external-fixation pins: The Effect on Pin Loosening and Pin-Track Infection in Leg Lengthening for Short Stature. Pizà G, Caja VL, González-Viejo MA, Navarro A. *J Bone Joint Surg [Br]* 2004; 86-B (6): 892-7.
6. Fixation Strength and Pin Tract Infection of Hydroxyapatite-Coated Tapered Pins. Moroni A, Heikkila J, Magyar G, Toksvig-Larsen S, Giannini S. *Clin Orthop* 2001; (388): 209-217
7. State of the Art Review: Techniques to Avoid Pin Loosening and Infection in External Fixation. Moroni A, Vannini F, Mosca M, Giannini S. *J Orthop Tr* 2002; 16 (3):189-195

Pin Site Infection

8. DeBastiani G, Aldegheri R, Renzi Brivio L. The treatment of fractures with a dynamic axial fixator. *J Bone Joint Surg [Br]* 1984; 66B: 538-545.
9. Pin Track Infection: Definition, Incidence and Prevention. Checketts R, Otterburn M, MacEachern G. *Int J Orthop Trauma* 1993; 3(3): 16-18
10. Sims M, Saleh M. Protocols for the care of external fixator pin sites. *Prof Nurse* 1996; 11 (4): 261-4.
11. Sims M, Saleh M. External fixation—the incidence of pin site infection: a prospective audit. *J Orthop Nursing* 2000; 4: 59-63.
12. No difference between daily and weekly pin site care: A Randomized Study of 50 Patients with External Fixation. W-Dahl A, Toksvig-Larsen S, Lindstrand A. *Acta Orthop Scand*. 2003 Dec; 74: 704-8.
13. The care of pin sites with external fixation. Davies R, Holt N, Nayagam S. *J Bone Joint Surg [Br]* 2005; 87-B (5): 716-19.

Manufactured by: ORTHOFIX Srl
Via Delle Nazioni 9
37012 Bussolengo (Verona)
Italy

Telephone +39 045 6719000
Fax +39 045 6719380



Your Distributor is:

Deformity Correction | Trauma | Pediatrics | Bone Growth Stimulation