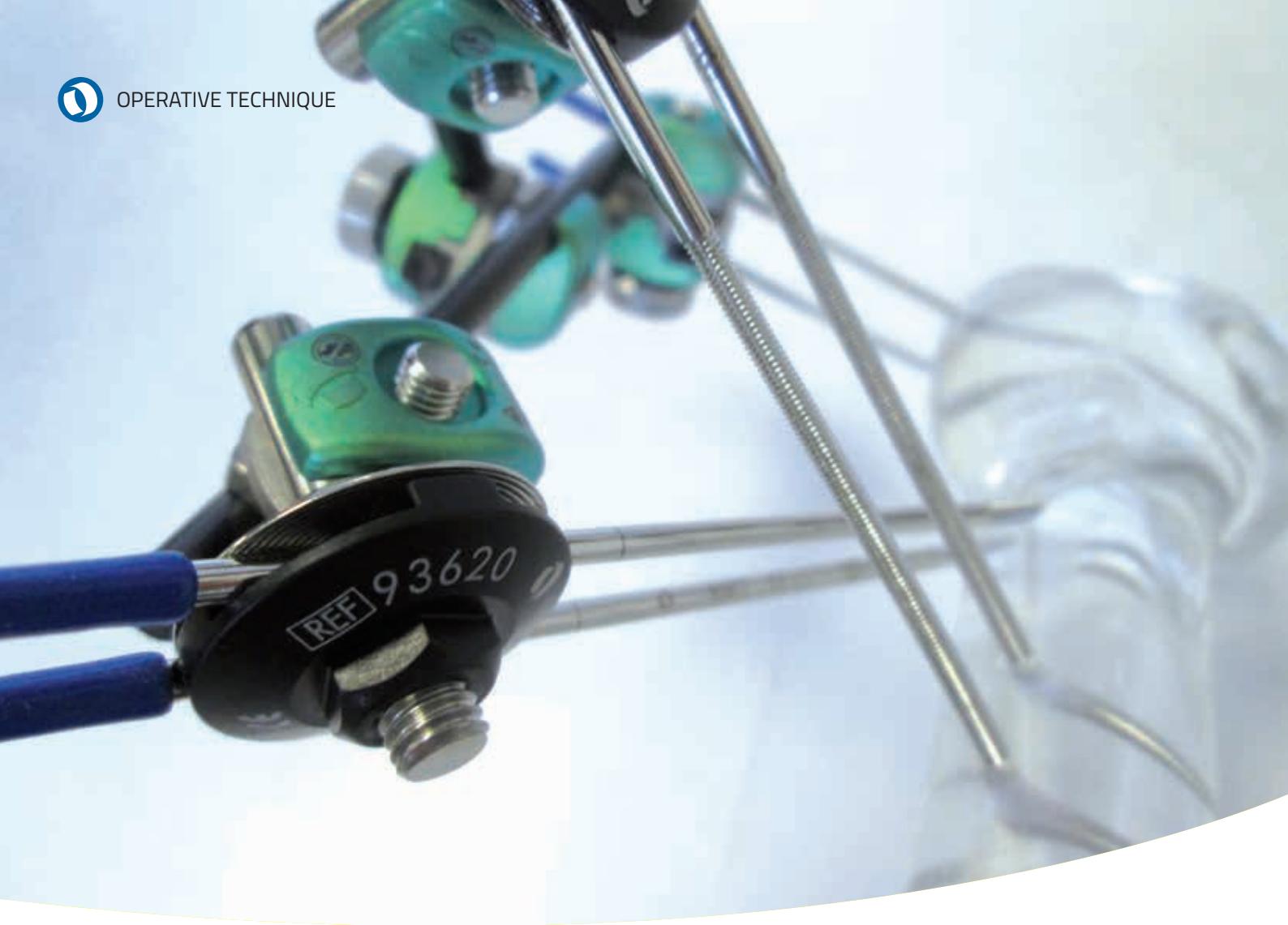

GALAXY FIXATION™ SHOULDER

INTRODUCTION	1
FEATURES OF SHOULDER COMPONENTS	2
EQUIPMENT REQUIRED	5
PREOPERATIVE PLANNING	6
SURGICAL PROCEDURE	8
POST OPERATIVE MANAGEMENT	17
MRI SAFETY INFORMATION	17

The surgical technique shown is for illustrative purposes only. The technique(s) actually employed in each case will always depend upon the medical judgment of the surgeon exercised before and during surgery as to the best mode of treatment for each patient. Please see the Instructions for Use for the complete list of indications, warnings, precautions, and other important medical information.

Operative Technique Contributing Surgeon:
M. Assom, MD
D. Blonna, MD

INTRODUCTION

This operative technique explains the recommended procedures for using the Orthofix Galaxy Fixation™ Shoulder system and instruments. Please refer to the relevant instructions below for specific steps. The IFU (Instruction For Use) leaflet contains the indications for use and contraindications and is provided with the product. It can also be found at <http://ifu.orthofix.it>

For **MRI** Safety Information see page 17.

The rods and the threaded wires are strictly single patient use.

FEATURES OF SHOULDER COMPONENTS

Rods


Strong radiolucent rods with diameter 6mm and various lengths.

Rods **Diameter 6mm** 

Code	Description
936060	Rod 60mm long
936080	Rod 80mm long
936100	Rod 100mm long
936120	Rod 120mm long
936140	Rod 140mm long
936150	Rod 150mm long
936160	Rod 160mm long
936180	Rod 180mm long
936200	Rod 200mm long

Small clamp (93310)

Allow easy and stable connection of either a rod and a wire locking clamp or two rods.




Clamp closure

1 pre-closure



Turn the locking screw fully by hand

2 final closure



Wrench

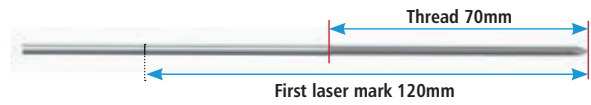
Wire Locking Clamp (93620)

It consists of two disks which lock the 2.5mm Threaded Wire (93100) passing through it (NB: the clamp must not be removed but only slackened).

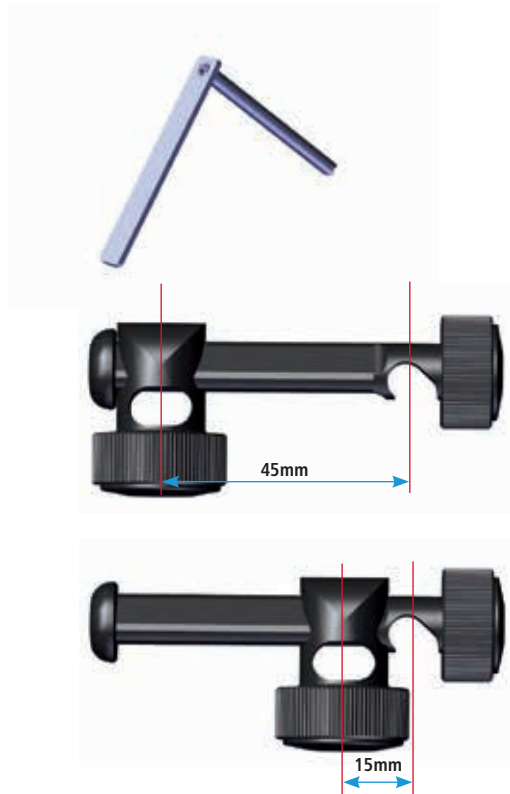


Threaded Wire (93100)

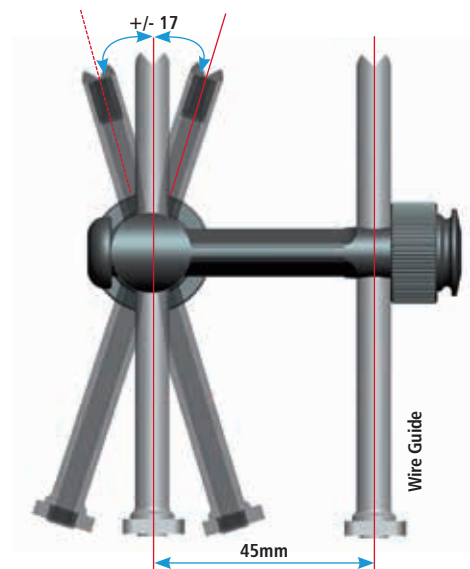
It is self-drilling and self-tapping. The wire have been marked at 120 and 165mm to verify the correct insertion depth. Full length of the wire: 300mm, Ø 2.5mm.

**Wire guide (19970)**

Allows the correct insertion of the 2.5mm threaded wires.

**Wire Targeting Device (19975)**

Allows positioning and fixation of the Wire Guides which can be fixed parallel, converging or diverging according to the type of fracture. The Wire Guides must be used to insert the 2.5mm Threaded Wires correctly.



Galaxy small clamp

Simple: one clamp for rod-to-rod and wire locking clamp to-rod connections.

Easy: snap-in system, provisional tightening by hand, definitive closure in one step.

Stable: internal teeth and locking profiles designed to provide high torsional strength and avoid components sliding.



Galaxy shoulder frame

Simple, standardized and reproducible: frame application guided by anatomical landmarks for most common proximal humeral fracture patterns.

Stable: 7cm threaded paired bicortical wires. Subchondral (in the humeral head) and lateral bone purchase.

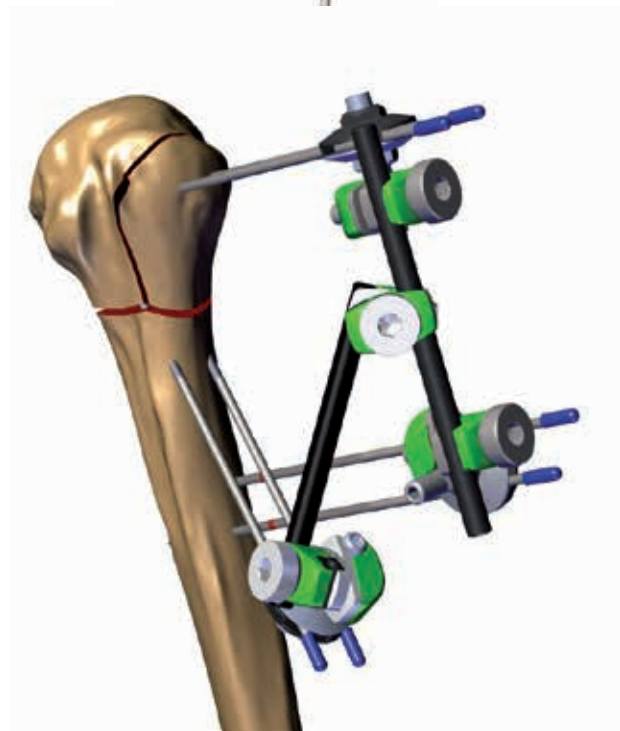
Low complication rate: Galaxy Shoulder Fixation significantly reduces pin migration and backing out vs traditional pinning.

Minimally invasive: percutaneous reduction. Fracture fixation with six wires externally stabilized with Galaxy Shoulder components.

End of treatment (Average 6 weeks) corresponds to frame removal without need for a second surgery.

Early passive mobilization and rehabilitation

Versatile: sterile kit, sterile-single packed components, instrument and implant tray.



EQUIPMENT REQUIRED

GALAXY SHOULDER TRAY


Can accommodate:

Code	Description
93310	Small Clamp
93620	Wire Locking Clamp
936080	Rod d 6mm L 80mm
936100	Rod d 6mm L 100mm
30017	Allen Wrench 5mm
19975	Wire Targeting Device
19970	Wire Guide
19980	Wire Bender
91150	Bone Screw T Wrench
81031	Open End Wrench

to order any of the Rods or Clamps, single-packaged and sterile, please add 99- prior to the part number, ex. 99-93310

Out of tray:

- Threaded wire sterile (pack of 2) 99-93100
- Wire cutter W1003



GALAXY SHOULDER STERILE KIT (99-93505)

Can accommodate:

Code	Description
4x93310	Small Clamp
3x93620	Wire Locking Clamp
2x936080	Rod d 6mm L 80mm
2x936100	Rod d 6mm L 100mm
1x30017	Allen Wrench 5mm
1x19975	Wire Targeting Device
2x19970	Wire Guide
1x91150	Universal "T" Wrench
1x81031	Open end wrench
5x93100	300mm Threaded wire

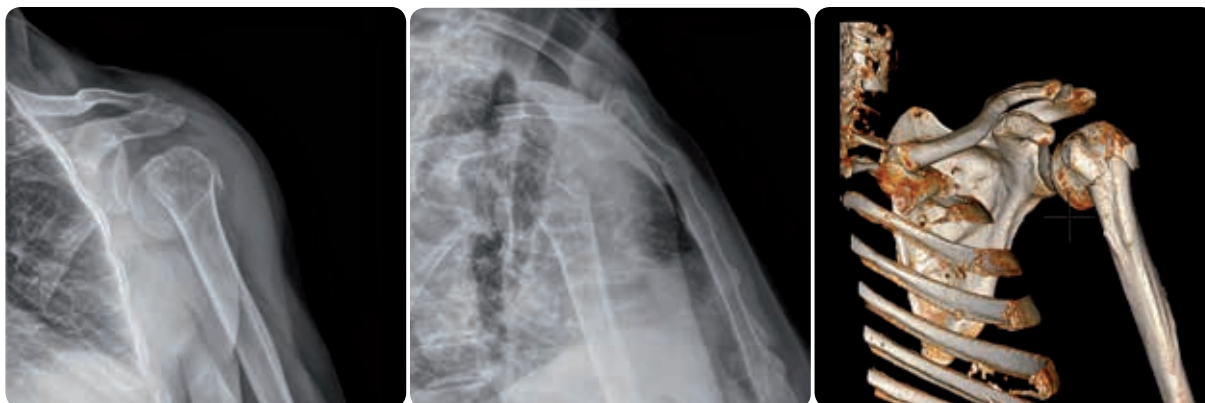

Out of sterile kit:

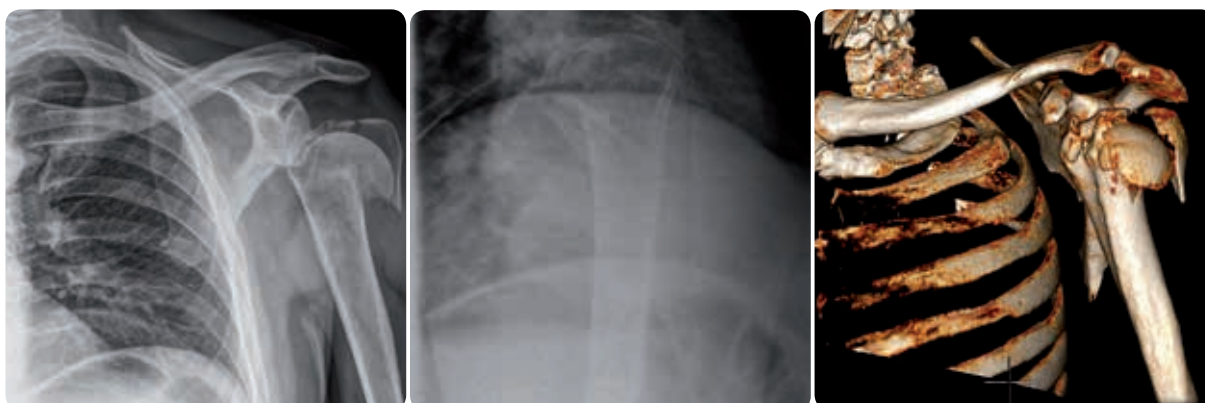
- Threaded wire sterile (pack of 2) 99-93100
- Wire cutter W1003

PREOPERATIVE PLANNING

AP and trans-thoracic or outlet X-ray views are recommended in all cases. A CT scan is also strongly recommended especially in 3 and 4 part fractures.



Antero-posterior, trans-thoracic X-ray and a CT scan with 3D reconstruction of a 2 part fracture



Antero-posterior, trans-thoracic X-ray and CT scan of a 4 part proximal humeral fracture

Positioning the patient in the operating room

The patient is placed in the beach chair position (Fig. 1).

NOTE: in order to allow the Image Intensifier to be handled correctly, we recommend using a modular table for shoulder surgery with removable proximal components.

Position the Image Intensifier on the contralateral side with the X-ray beam positioned over the glenoid to obtain a true AP view.

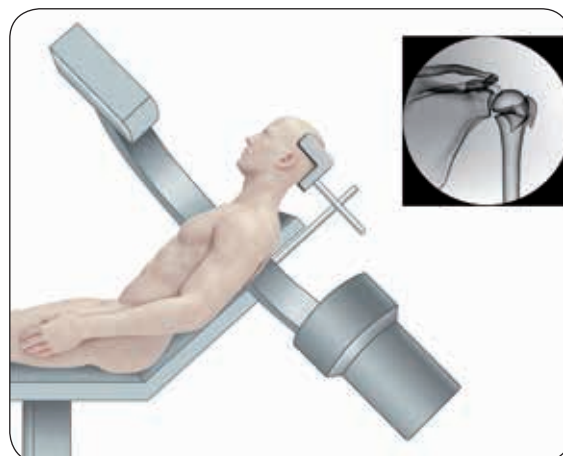


Fig. 1

Suggested preparation of the surgical field

A double skin preparation is recommended to reduce the risk of infection:

- prewash the shoulder with 4% chlorhexidine gluconate
- proceed with standard skin preparation according to hospital protocol.

The area of the acromioclavicular joint and coracoid must be clearly visible: this is important to facilitate percutaneous insertion of the wires. The upper limb must be able to be moved freely to allow reduction manoeuvres.

Anatomical landmarks

For a safer procedure and to minimise the use of X-ray, draw marks on the skin to identify the coracoid and the lateral part of the acromion.

Draw a transverse line 5cm distal to the lateral acromion that will show the position of the axillary nerve (Fig. 2).

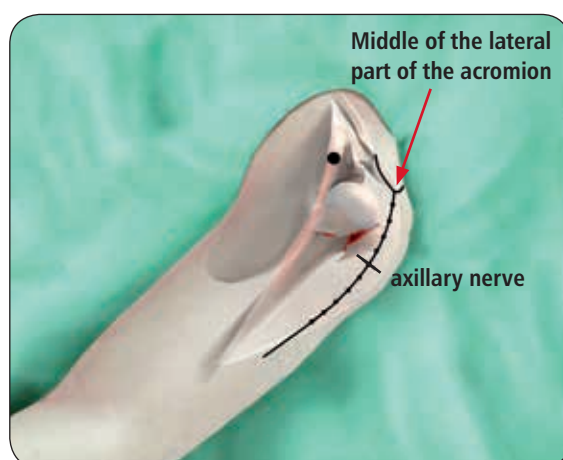


Fig. 2

SURGICAL PROCEDURE

The surgical procedure can be conducted in two different ways, depending on the type of fracture, surgeon experience and preference:

- Closed reduction and percutaneous fixation (in some cases aided by percutaneous instruments)
- Open reduction and percutaneous fixation

CLOSED REDUCTION AND PERCUTANEOUS FIXATION

Closed reduction

Usually these fractures have a varus deformity with antero-medial displacement of the humeral shaft. In such cases, the reduction can be achieved by combining 2 manoeuvres. Alternatively, other reduction manoeuvres should be performed depending on the pattern of fracture.

First manoeuvre: reduction of the varus deformity

Stabilize the scapula of the patient with one hand and move the arm into abduction. The degree of abduction depends on the severity of varus displacement; usually traction is not indicated (Fig. 3).

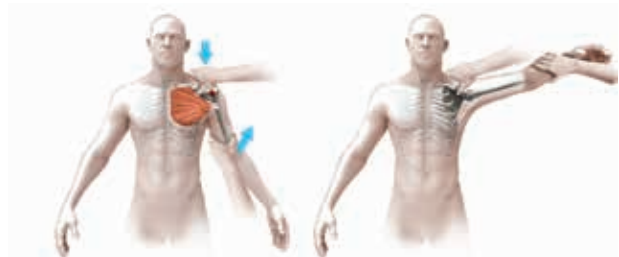

Fig. 3

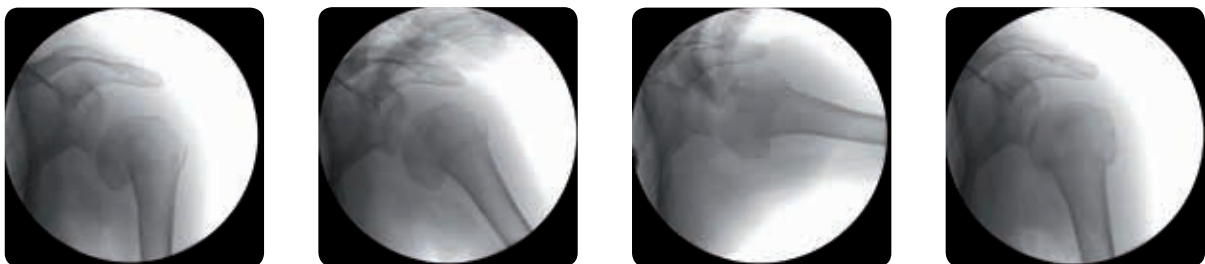
Second manoeuvre: reduction of the antero-medial displacement of the shaft and the internal rotation of the head

Support the forearm of the patient with one hand and press the humeral shaft posteriorly with the other. Keep the arm abducted about 45 degrees and in neutral rotation with gentle pressure (Fig. 4).

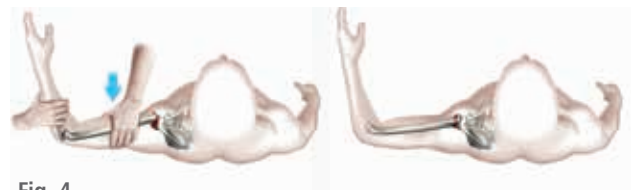

Fig. 4

NOTE: additional lateral traction can be applied to correct any residual displacement of the shaft.



Sequential x-ray images during the reduction manoeuvres.

If the reduction is not satisfactory or cannot be obtained with external manipulation, it can be improved using a percutaneous instrument, such as a small hook or a periosteal elevator, inserted through a small deltoid split to reduce the greater tuberosity (Fig. 5).

Alternatively, open reduction can be performed, via a deltopectoral approach. (See pag 16)

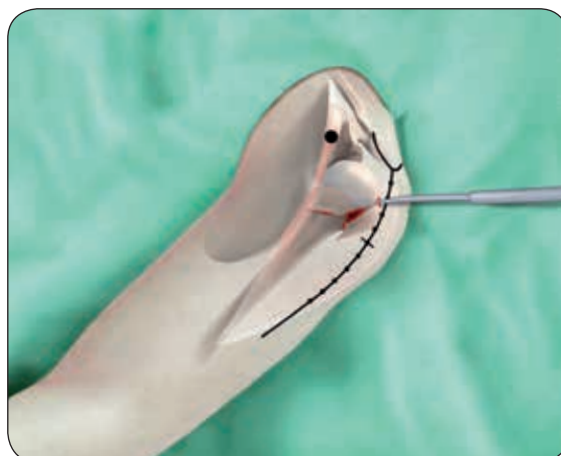


Fig. 5

Percutaneous fixation

It is useful to keep the injured arm parallel to the floor, with approximately 45° of abduction, to maintain the reduction (Fig. 6). Wires should be inserted from anterior to posterior with an inclination of about 20° to the humeral diaphysis in order to target the humeral head (Fig. 7).

WARNING: Use the wire guide during insertion to avoid damage to the threaded wires.

Each wire should have a bicortical purchase without damaging the articular cartilage (in the humeral head bicortical means subchondral and lateral cortex). Make a small skin incision and position the tip of the wire on the cortical surface. Insert the wires with the drill at low speed and use the wire guide to avoid damage of the soft tissue and/or joint impingement. After wire insertion, check for correct position and joint function under image intensification.

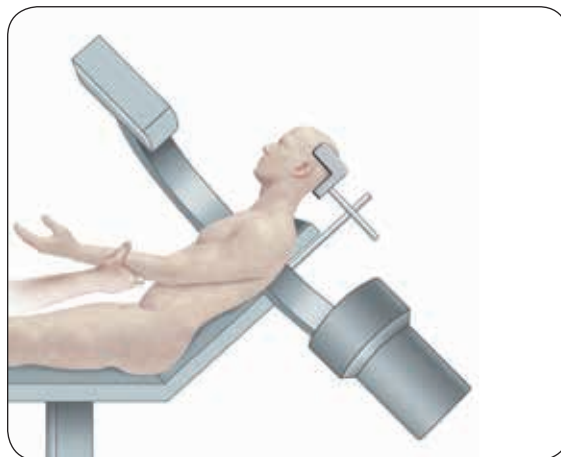


Fig. 6

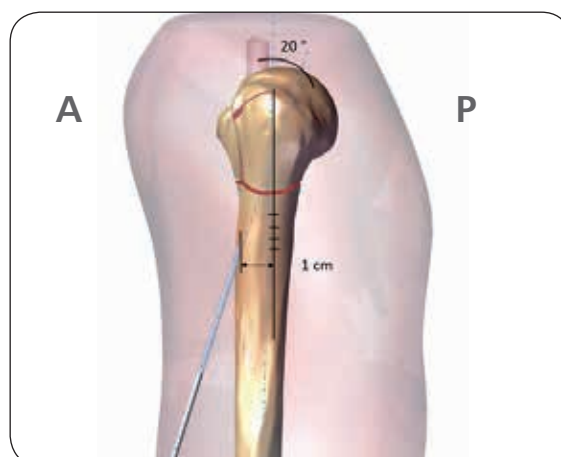


Fig. 7

1) Ideally, the first wire should be about 9cm distal to the lateral border of the acromion and about 1cm anterior to this line. The insertion point is usually anterior, in line with the area of the deltopectoral approach (see red dotted line). This avoids axillary nerve injury (Fig. 8). The wire should be inserted in the direction of the coracoid with approximately 20° posterior inclination to allow for the anatomical retroversion of the humeral head (Fig. 9, 10).

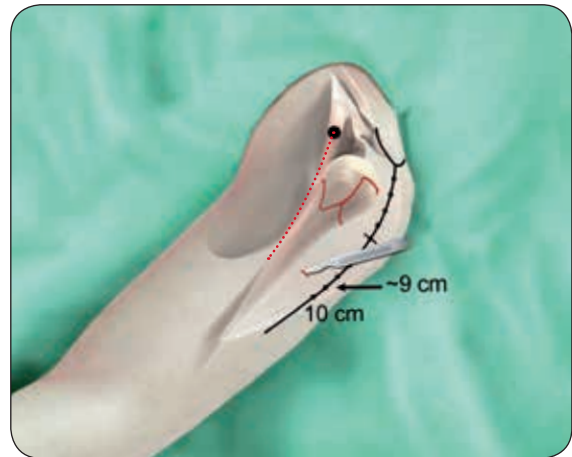


Fig. 8

Warning: The tip of the threaded wire should be in the subchondral area of the humeral head (Fig. 9).

Check the wire position with the image intensifier (Fig. 11).

If necessary, reposition the wire in the desired position, without bending it.

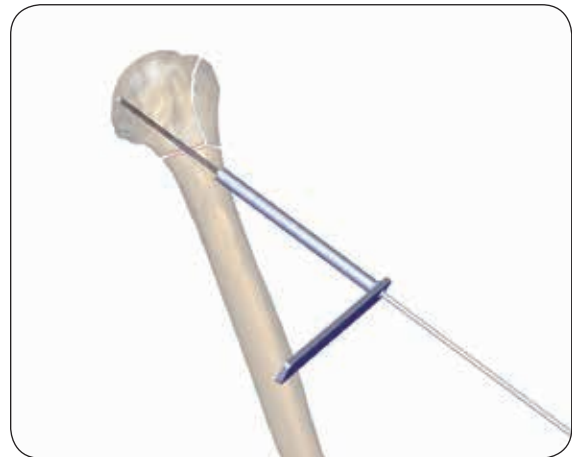

Fig. 9

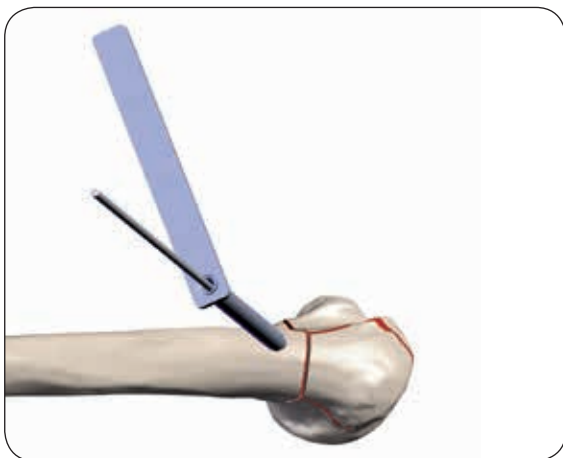


Fig. 10

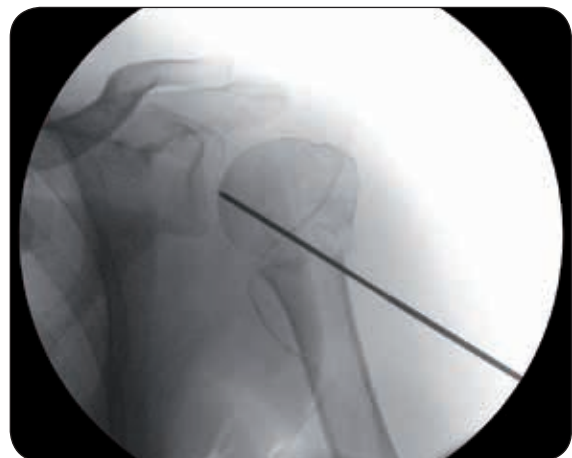

Fig. 11

2) Insert a second wire about 1cm from the first, as parallel to it as possible to facilitate final application of the clamps (Fig. 12). The wire targeting device is available as an option to assist in this step. The wires have been marked as an aid to obtain correct insertion depth, reducing the use of image intensification.

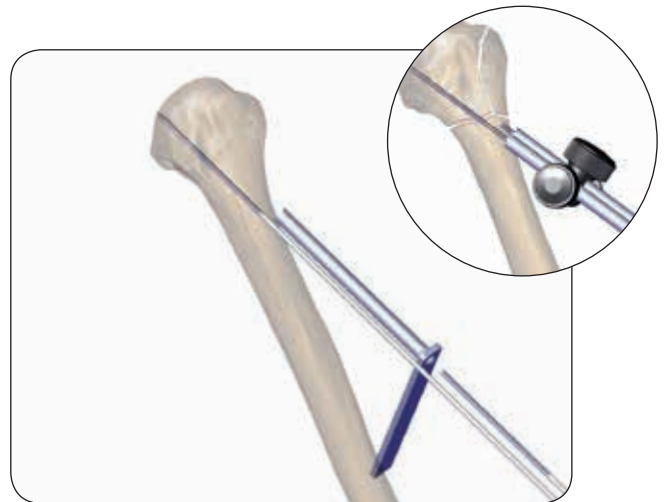

Fig. 12

Correct positioning of the first two wires is critical because they provide initial fixation of the humeral head to the shaft (Fig. 13).

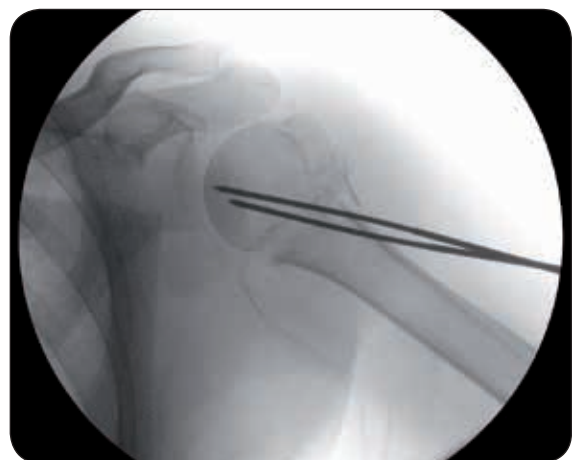
Check if the fracture is well reduced and that the wires have been inserted correctly by moving the patient's arm in internal and external rotation.

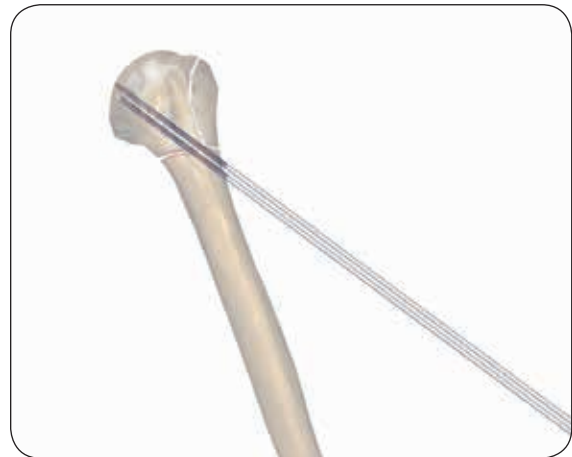
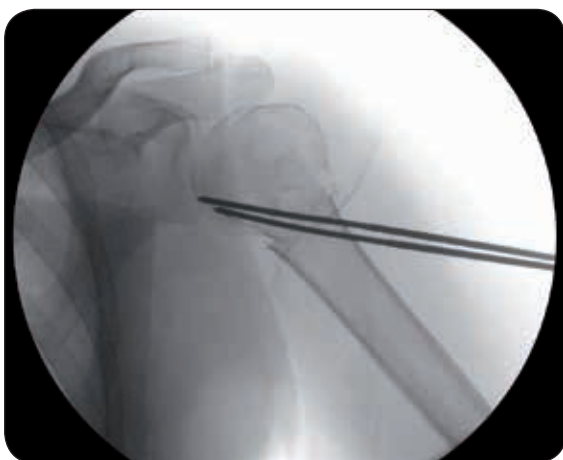
Fig. 13



Internal rotation



External rotation

WARNING: the tip of the threaded wire should be in the subchondral area of the humeral head (Fig. 14). The wires must not penetrate the cartilage. Back the wires out if necessary (Fig. 15).

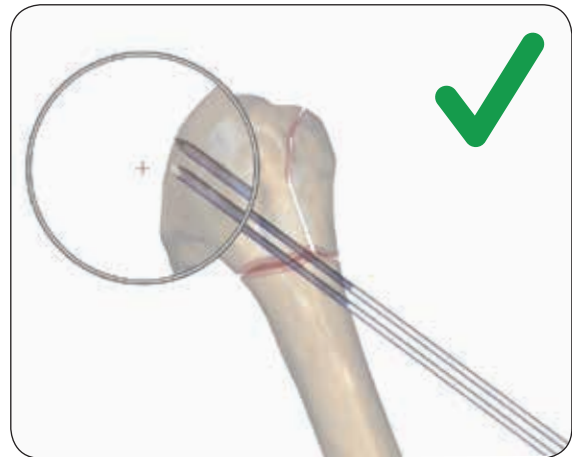


Fig. 14

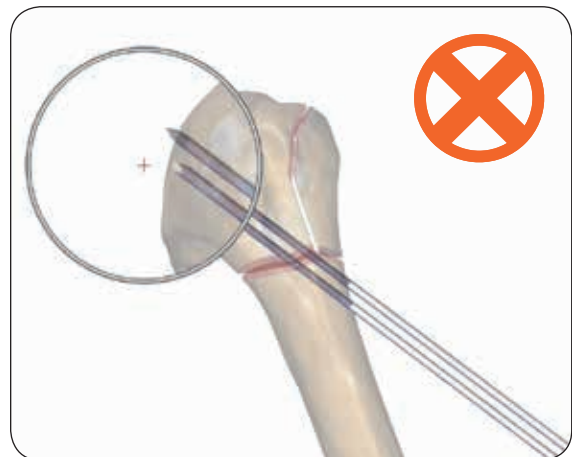


Fig. 15

3) Keeping the patient's arm around 40° abducted, insert third and fourth wires about 1 to 2cm distal to the acromial border towards the humeral head. Insert the wires parallel, about one centimeter apart (Fig. 16).

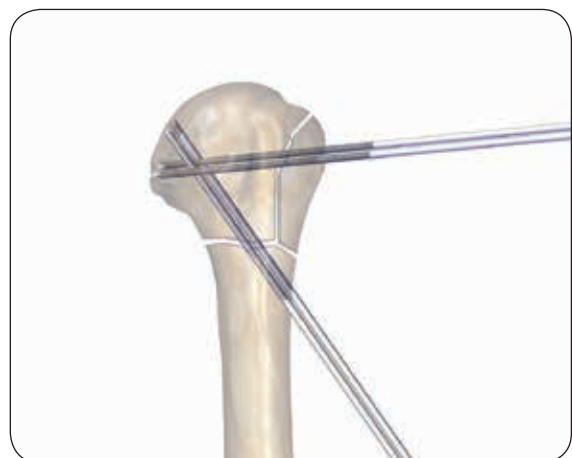

Fig. 16

4) Insert fifth and sixth wires into the diaphysis, again about 1cm apart. The wires will be inserted in the skin proximally to the oblique wires (see blue arrow), whereas they will enter the bone distally to the oblique wires (see red arrow) (Fig. 17).

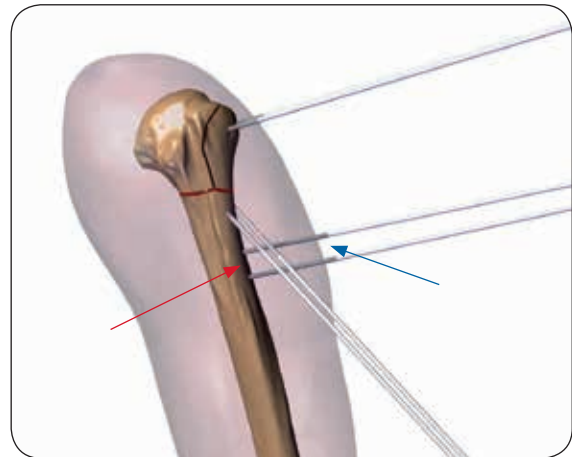


Fig. 17

Stabilization of the wires

Insert the Wire Locking Clamp between each pair of wires, checking that they are orientated in the same plane.

If necessary, bend the wires to approximately 90° with the Wire Bender.

Leave a distance of about 3cm from the skin: this will facilitate medication and removal at the end of treatment (Fig. 19).

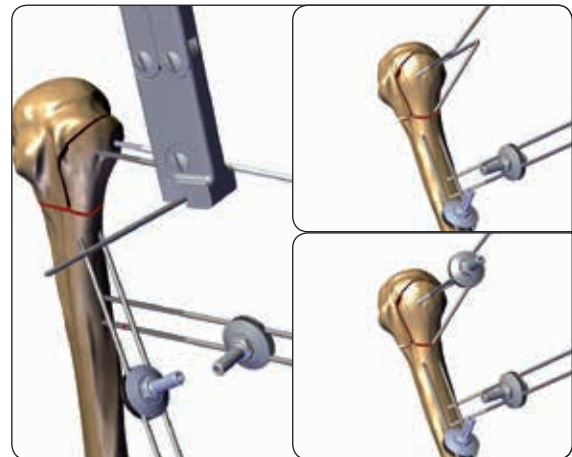


Fig. 19

Hold the Wire Locking Clamp with the Open End Wrench 10mm, and tighten the upper disk of the clamp using the Universal T-Wrench (Fig. 20).

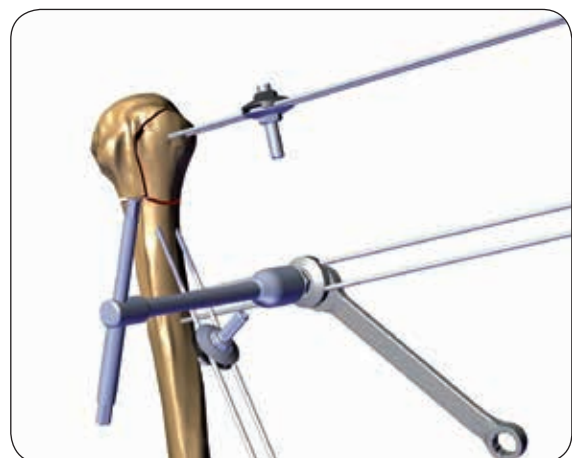


Fig. 20

Connect each wire locking clamp with a Galaxy Small Clamp, then connect them with 6mm diameter rods and an additional galaxy small clamp. Galaxy Small Clamp knobs should be oriented towards the surgeon to facilitate their closure (Fig. 21).

Each Galaxy Small Clamp must be pre-closed turning the knob fully by hand and then tightening it with the wrench for the final closure.

Test the stability of the fixation under image intensification.

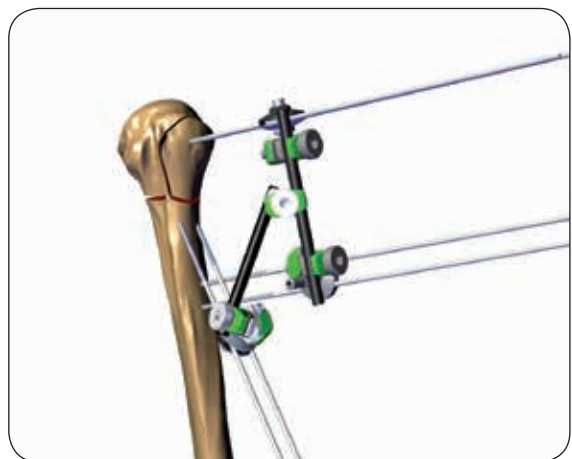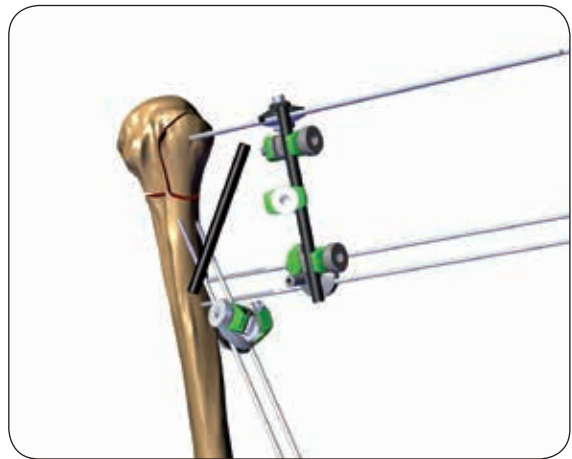
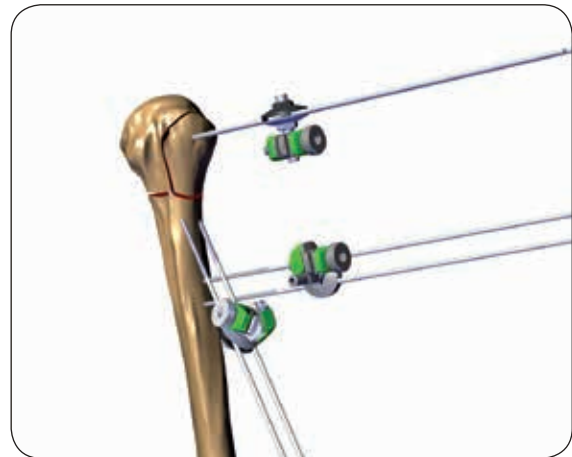


Fig. 21

Cut the wire close to the Wire Locking Clamp (Fig. 22).




Fig. 22

Cover each wire with a Wire Cover (Fig. 23).

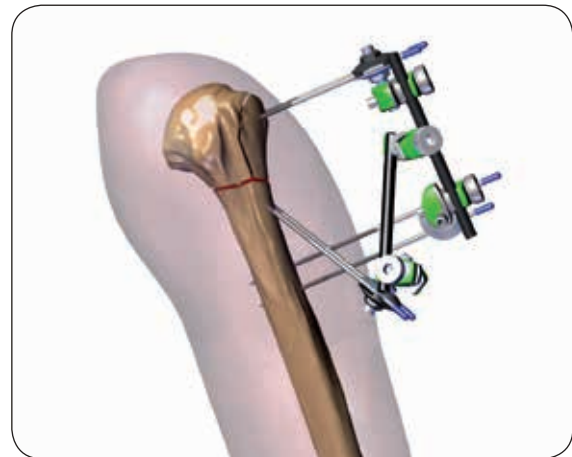
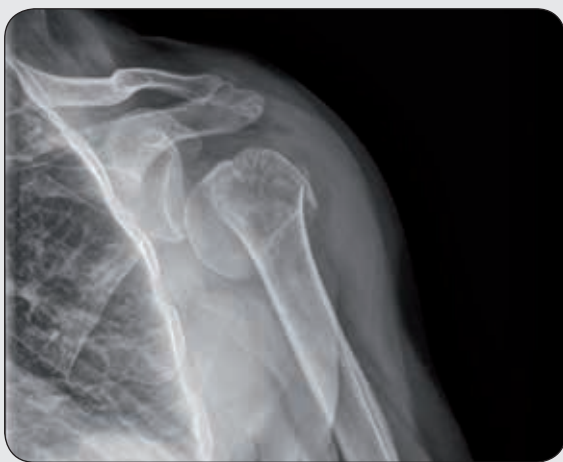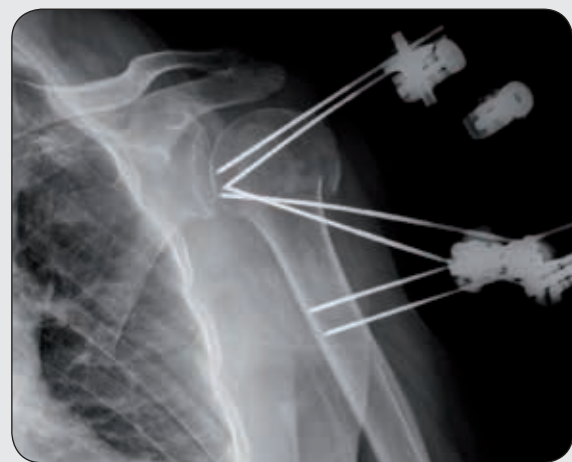


Fig. 23



PRE OP



POST OP

Open reduction and percutaneous fixation

Open reduction can be used for a wide range of fracture patterns. The reduction does not differ from other techniques that employ internal fixation.

Draw the same landmarks described above (see page 7) with the lines referring to the level of deltopectoral incision (red line) and the axillary nerve (Fig. 24).

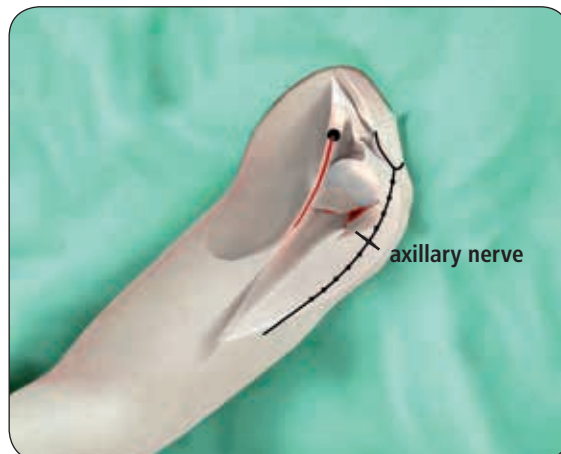


Fig. 24

Expose the fracture using a deltopectoral approach. The tuberosities are identified and the rotator interval opened (Fig. 25).

The humeral head is reduced by elevation and rotation with one finger or with a blunt instrument.

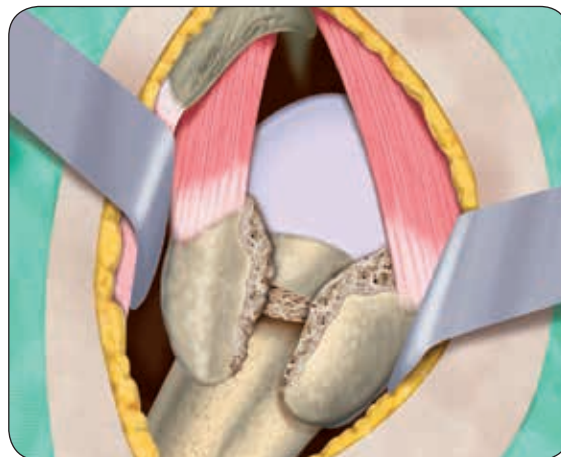

Fig. 25

After reduction the humeral head is fixed to the shaft, inserting the first two oblique wires with the same technique described above. (See page 10, 11) These first two wires must be at least 2cm distal to the deltopectoral incision (Fig. 26).

Check the reduction and the position of the two wires under fluoroscopy.

A hole is made in the proximal shaft to accommodate 2 not-absorbable sutures. The tuberosities are reduced and held in place using the not-absorbable sutures.

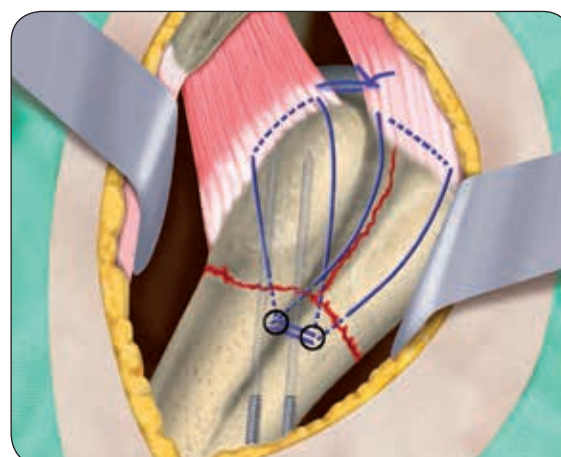


Fig. 26

Insert the third and the fourth wires through the greater tuberosity towards the humeral head, as described above. (See page 12)

Leave the deltopectoral incision open to facilitate the entry point of the wires in the cortex (Fig. 27).

Complete the fixation inserting the fifth and the sixth wires into the shaft in the proximity of the first two oblique wires, perpendicular to the humeral axis. (See page 13)

Stabilize the wires inserting the wire locking clamps and connect them with Galaxy small clamps and 6mm diameter rods as described previously.

Once the fixator is applied, verify the stability of the fixation under image intensification.

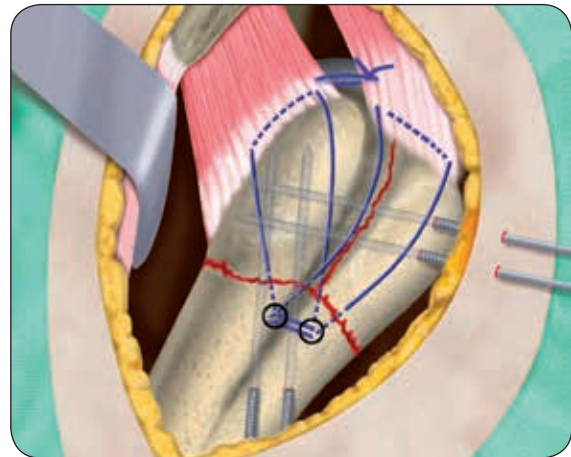
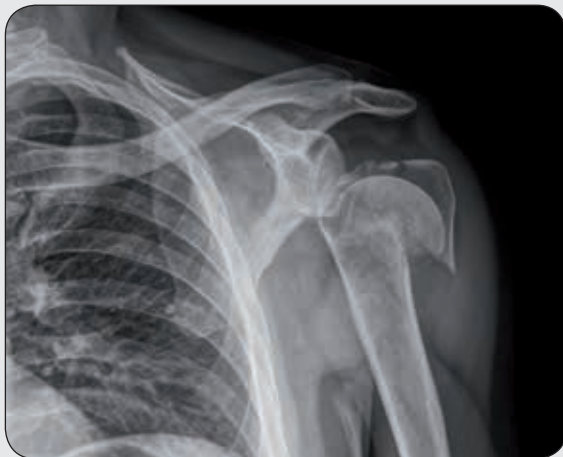
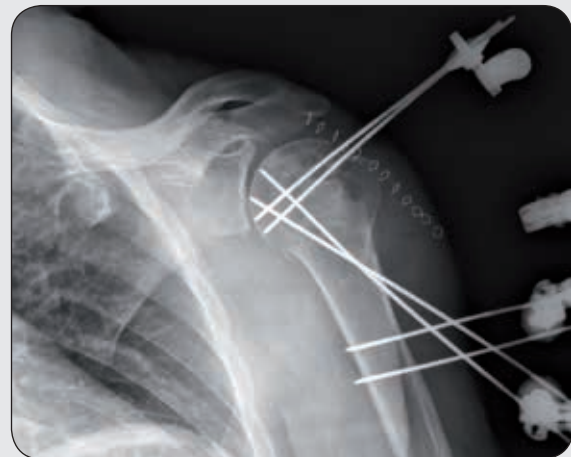
Fig. 27

The antero-posterior x-ray images below show an example in case of valgus-impacted 4 part proximal humeral fracture before and after surgery.



PRE OP



POST OP

POST OPERATIVE MANAGEMENT

Pin site care and wound dressing should be performed once a week; avoid wetting the area of the frame. Place the arm in a sling until the removal of the wires. This can be temporarily removed to permit personal hygiene and passive mobilization according to surgeon's prescription.

Frame removal

Disassemble the frame or remove it cutting the six wires leaving enough space to connect the power drill and fully unscrew them.

MRI SAFETY INFORMATION

The Orthofix Galaxy Shoulder Frame has not been evaluated for safety and compatibility in the MR environment.

It has not been tested for heating, migration, or image artifact in the MR environment. The safety of the Orthofix Galaxy shoulder frame in the MR environment is unknown. Scanning a patient who has this device may result in patient injury.

Electronic Instructions for use available at the website
<http://ifu.orthofix.it>

Electronic Instructions for use - Minimum requirements for consultation:

- Internet connection (56 kbps)
- Device capable to visualize PDF (ISO/IEC 32000-1) files
- Disk space: 50Mbytes

Free paper copy can be requested to customer service (delivery within 7 days):
tel +39 045 6719301, fax +39 045 6719370,
e-mail: customerservice@orthofix.it

Distributed by:



Manufactured by:
ORTHOFIX Srl
Via Delle Nazioni 9, 37012 Bussolengo (Verona), Italy
Telephone +39 045 6719000, Fax +39 045 6719380



Caution: Federal law (USA) restricts this device to sale by or on the order of a physician. Proper surgical procedure is the responsibility of the medical professional. Operative techniques are furnished as an informative guideline. Each surgeon must evaluate the appropriateness of a technique based on his or her personal medical credentials and experience. Please visit www.orthofix.com/IFU for full information on indications for use, contraindications, warnings, precautions, adverse reactions information, and sterilization.

www.orthofix.com

GF-1805-OPT-E0 A 09/18

ORTHOFIX®